

Pierre Dahdah<sup>1</sup>, Giuseppe Bruschi<sup>2\*</sup>  
and Victor Jebara<sup>1</sup>

<sup>1</sup>Department of Thoracic & Cardiovascular Surgery, "Hotel-Dieu de France" Hospital, Beirut, Lebanon  
<sup>2</sup>"De Gasperis" Cardiac Center, ASST Niguarda General Hospital, Italy

**Dates:** Received: 12 August, 2016; Accepted: 27 September, 2016; Published: 28 September, 2016

**\*Corresponding author:** Giuseppe Bruschi, "De Gasperis" Cardiac Center, ASST Niguarda General Hospital, Piazza dell'Ospedale Maggiore 3, 20162 Milan, Italy, Tel: +39.02.6444.2565; E-mail: giuseppe.bruschi@fastwebnet.it

[www.peertechz.com](http://www.peertechz.com)

ISSN: 2455-2976

**Keywords:** Transcatheter valve implantation; Surgery; Aortic; Aortic valve disease

## Case Report

# Direct Aortic Evolut R Implantation as Valve-In-Valve in a Patient Affected by Leriche Syndrome

### Abstract

Transcatheter aortic valve implantation (TAVI) has been designed to treat elderly patients with severe aortic stenosis considered high-risk surgical candidates.

Due to the large device size, even of current generation systems, the trans-femoral approach requires favorable ilio-femoral arterial anatomy; this approach is contraindicated in patients with excessive atherosclerosis, calcifications, or tortuosity of ilio-femoral arteries.

We report the case of a 75-year-old female affected by Leriche syndrome who successfully underwent direct aortic (DAo) transcatheter aortic valve implantation with a Medtronic CoreValve Evolut R (Medtronic Inc., Minneapolis, MN, USA) as valve-in-valve implantation to treat a degenerate aortic bioprosthesis.

## Introduction

Transcatheter aortic valve implantation (TAVI) is an appropriate therapy to treat elderly patients with severe aortic stenosis considered high-risk surgical candidates. The safety and effectiveness of TAVI have been demonstrated in numerous observational clinical studies, national registries and also in controlled randomized trial [1,2].

The less invasive approach should be considered the trans-femoral one, nevertheless a number of patients that are referred for TAVI are not eligible for trans-femoral access due to calcification, vascular narrowing, or tortuosity of ilio-femoral arteries. For them, the transapical, subclavian, or direct aortic approaches may be a suitable alternative. The choice of alternative access should be determined by the heart team based on anatomic characteristics and clinical status of the patient.

We report the case of a 75-year-old female affected by Leriche syndrome who successfully underwent valve-in-surgical valve TAVI, through a direct aortic approach, with a Medtronic CoreValve Evolut R.

The Evolut R maintains the cell geometry of the prior CoreValve prosthesis to optimize frame conformance to the native aortic annulus, the delivery system is designed to have a stable and predictable deployment with the advantage, if necessary, to re-sheath, reposition, and redeploy the valve. Evolut R system used the new, catheter-mounted InLine sheath, which eliminates the need for an external sheath; this sheath has a lower equivalent to the outer diameter of a 14-F sheath [3].

## Case Report

A 75 year-old female was admitted, on January 2016, for congestive heart failure at our hospital. The patient had undergone in 2011 aortic valve replacement with a biological Carpentier-Edwards

Magna 23 mm prosthesis (Edwards Lifesciences, Irvine, CA). She was also affected by severe chronic renal failure (creatinine clearance 30 ml/min), oxygen dependent chronic obstructive pulmonary disease (COPD) and epi-aortic vessels vasculopathy with left subclavian artery occlusion and 70% stenosis of left internal carotid artery. The patient suffered from aorto-iliac occlusive disease with complete occlusion of the aorta distal to the renal arteries. To treat Leriche syndrome in 2014 she underwent axillo-bi-femoral bypass with extra-anatomic technique (Figure 1A), at that time transthoracic echocardiography (TTE) revealed normal left ventricle (LV) function with mean gradient of the aortic bioprosthesis of 15 mmHg. Six months after surgery the patient experienced shortness of breath with NYHA Class III; ambulatory TTE showed an increased gradient through the aortic bioprosthesis with a mean gradient of 50 mmHg. Valve thrombosis was suspected and Coumadin was prescribed. Her condition continued to deteriorate in spite of an INR between 2.5 and 3.0. During this period, she was readmitted three times for bouts of congestive heart failure. All blood essays for systemic inflammatory diseases were negative.

After clinical stabilization patient underwent TTE that showed aortic trans-prosthesis mean gradient of 100 mmHg. After Heart Team evaluation taking into consideration patient's comorbidities (Euroscore II: 24.1; STS score Mortality: 20.6%) a trans-catheter aortic valve-in-valve implantation was preferred.

An ECG-gated multi-slice computed tomography (MSCT) was performed to evaluate patient's anatomy and access site. Taking into consideration aorto-iliac occlusive disease, epi-aortic vessels vasculopathy and oxygen dependent chronic obstructive pulmonary disease a direct aortic access was considered the safest option for the patient, patient's written informed consent was obtained.

On the basis of 3-d MSCT scan images, that excluded calcifications on the ascending aorta, entry site was selected and right anterior

thoracotomy was preferred (Figure 1B), a Medtronic CoreValve 23 mm valve was preferred considering Magna 23 mm prosthesis inner diameter of 61 mm (Figure 1C).

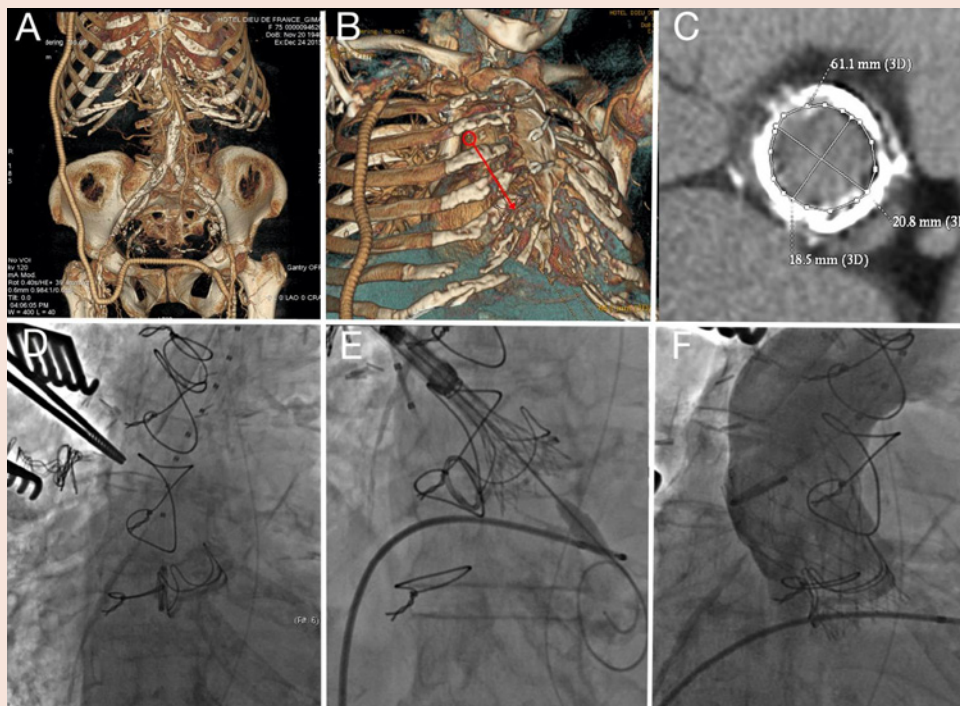
A temporary pacing lead was advanced in the right ventricle through the right jugular vein. A right radial access was performed in order to advance a pigtail catheter in the non-coronary cusp. Right anterior mini-thoracotomy was performed in the 2nd intercostal space as evaluated by CT scan. A basal fluoroscopy of the ascending aorta was performed to check correct alignment and coaxial trajectory to aortic annulus (Figure 1D). Direct aortic cannulation was performed with the Seldinger technique through double purse-string sutures. A 7-Fr sheath was then inserted and aortic bioprosthesis crossed using a 0.035 straight guide-wire, then a 18-Fr sheath was inserted over an Amplatz super stiff guidewire (Amplatz Cook, Inc., Bloomington, Indiana). A 23 mm CoreValve Evolut R was then carefully introduced and retrogradely implanted under fluoroscopic guidance without contrast injections (Figure 1E). The 18-Fr sheath was removed, purse string sutures on the aorta were knotted. Final ascending aorta angiography evidenced normal ascending aorta no para-valvular leak and good Evolut R expansion inside the Magna valve (Figure 1F), hemodynamics evaluation evidenced invasive transvalvular mean gradient of 9 mmHg, and no paravalvular leak on trans-esophageal

echo imaging. A 26-Fr round fluted chest spiral drain was positioned and mini-thoracotomy incision was closed in standard fashion. Patient was extubated on the same day, and discharged from hospital on 9th post-operative day. At three months from TAVI the patient experience significant clinical improvement and is in NYHA class II.

## Discussion

Early degeneration or high gradient across a bioprosthesis in elderly patients has been rarely reported [4]. Structural valve deterioration includes changes intrinsic to the valve like wear, calcification, leaflet tear, and stent creep. Other possible mechanisms included valve thrombosis, excessive pannus formation, accelerated structural valve deterioration [5,6] and marastic endocarditis in patients with known antiphospholipid syndrome (primary or secondary to systemic lupus erythematosus, or other rheumatic or autoimmune diseases) [5,6]. This patient had no history of infection or systemic inflammatory disease. Bioprosthetic valve thrombosis was suspected, even if rare with a reported incidence varying from 0.1 per 100 valve-years to as high as 6% [7], and anticoagulation was started but gradient across valve continuously to increase.

The valve-in-valve approach may offer an effective, less invasive treatment for patients with failed surgical bioprostheses [8]. The most utilized access for TAVI is through the femoral artery.



**Figure 1:** Panel A: MSCT 3-d reconstruction evidenced severe peripheral vasculopathy and the presence of axillo-bi-femoral extra-anatomic bypass. Panel B: MSCT 3-d reconstruction was used to select right anterior mini-thoracotomy on 2<sup>nd</sup> intercostal space, to evaluate the entry site on the ascending aorta coaxial to aortic valve plane. Panel C: Double oblique transverse reformat of aortic valve at ECG-gated multislice computer tomography. Panel D: A basal fluoroscopy of the ascending aorta was used to check correct alignment and coaxial trajectory to aortic annulus. Panel E: A 23 mm CoreValve Evolut R was then introduced and retrogradely implanted under fluoroscopic guidance. Panel F: Final aortography evidenced normal ascending aorta no para-valvular leak and good Evolut R expansion inside the Magna valve.



However, in around 10-20% of cases, due to small iliac arteries, severe tortuosity, or massive or circumferential calcification, the femoral access cannot be used and other approaches have to be considered; these include: subclavian artery, carotid artery, direct aortic and trans-apical [9,10].

With the DAo approach, access to aortic annulus is achieved through the ascending aorta, and is distinct from the transapical approach in that pericardial dissection and direct heart muscle manipulation are not required. Moreover, in our patient affected by oxygen dependent COPB, trans-apical access was considered at higher risk. The left subclavian artery was totally occluded and epi-aortic vasculopathy was present excluding the possibility to use these arteries as entry site. Direct aortic access was selected by the heart team. Direct aortic approach can be performed either through an upper mini-sternotomy or through a right parasternal thoracotomy on the basis of patient's anatomy evaluated at MSCT. The advantage of performing TAVI through a right anterior mini-thoracotomy is more evident in re-do patients [11], in whom a repeat sternotomy, even if partial, is a challenging procedure; indeed, right thoracotomy requires only limited dissection at the entry site on the ascending aorta.

## Conclusion

The use of direct aortic access for TAVI procedures provides a safe alternative for patients with poor peripheral vessel access and common comorbidities. Our experience characterized by a heart team approach and multidisciplinary patient care demonstrated the safety and feasibility of direct aortic approach even in very fragile patients with multiple comorbidities.

## References

1. Adams DH, Popma JJ, Reardon MJ, Yakubov SJ, Coselli JS, et al. (2014) Transcatheter aortic-valve replacement with a self-expanding prosthesis. *N Engl J Med* 370: 1790-1798.
2. Leon MB, Smith CR, Mack MJ, Makkar RR, Svensson LG, et al. (2016) Transcatheter or Surgical Aortic-Valve Replacement in Intermediate-Risk Patients. *N Engl J Med* 374: 1609-1620.
3. Sinning JM, Werner N, Nickenig G, Grube E (2013) Medtronic CoreValve Evolut R with EnVeo R. *EuroIntervention* 9: S95-S96.
4. Sénage T, Le Tourneau T, Foucher Y, Pattier S, Cuffe C, et al. (2014) Early structural valve deterioration of Mitroflow aortic bioprosthesis: mode, incidence, and impact on outcome in a large cohort of patients. *Circulation* 130: 2012-2020.
5. Dohi M, Doi K, Yaku H (2015) Early stenosis of an aortic porcine bioprosthesis due to thrombosis: Case report and literature review. *J Thorac Cardiovasc Surg* 149: e83-e86.
6. Cremer PC, Rodriguez LL, Griffin BP, Tan CD, Rodriguez ER, et al. (2015) Early Bioprosthetic Valve Failure: Mechanistic Insights via Correlation between Echocardiographic and Operative Findings. *J Am Soc Echocardiogr* 28: 1131-1148.
7. Hammermeister KE, Sethi GK, Henderson WG, Oprian C, Kim T, et al. (1993) A comparison of outcomes in men 11 years after heart- valve replacement with a mechanical valve or bioprosthesis. Veterans Affairs Cooperative Study on Valvular Heart Disease. *N Engl J Med* 328: 1289-1296.
8. Dvir D, Webb JG, Bleiziffer S, Pasic M, Waksman R, et al. (2014) Transcatheter aortic valve implantation in failed bioprosthetic surgical valves. *JAMA* 312: 162-170.
9. Bruschi G, De Marco F, Botta L, Barosi A, Colombo P, Eet al. (2015) Right anterior mini-thoracotomy direct aortic self-expanding trans-catheter aortic valve implantation: A single center experience. *Int J Card* 181: 437-442.
10. Hayashida K, Romano M, Lefèvre T, Chevalier B, Farge A, et al (2013) The transaortic approach for transcatheter aortic valve implantation: a valid alternative to the transapical access in patients with no peripheral vascular option. A single center experience. *Eur J Cardiothorac Surg* 44: 692-700.
11. Bruschi G, De Marco F, Botta L, Oreglia J, Colombo P, et al. (2012) Direct transaortic CoreValve implantation through right mini-thoracotomy in patients with patent coronary grafts. *Ann Thorac Surg* 93: 1297-1299.

**Copyright:** © 2016 Dahdah P, et al. This is an open-access article distributed under the terms of the Creative Commons Attribution License, which permits unrestricted use, distribution, and reproduction in any medium, provided the original author and source are credited.

**Citation:** Dahdah P, Bruschi G, Jebara V (2016) Direct Aortic Evolut R Implantation as Valve-In-Valve in a Patient Affected by Leriche Syndrome. *J Cardiovasc Med Cardiol* 3(1): 038-040. DOI: 10.17352/2455-2976.000030