

Himanshu Jain and Nidambur Vasudev Ballal\*

Department of Conservative Dentistry and Endodontics, Manipal College of Dental Sciences, Manipal University, Manipal, Karnataka, India

**Dates:** Received: 30 January, 2016; Accepted: 09 February, 2016; Published: 11 February, 2016

\*Corresponding author: Dr. N. Vasudev Ballal, BDS, MDS, PhD, Professor, Department of Conservative Dentistry and Endodontics, Manipal College of Dental Sciences, Manipal, 576104, Manipal University, Karnataka, India, Tel: 91- 0820-2922172; Fax: 0091-820-257006; E-mail: drballal@yahoo.com

www.peertechz.com

ISSN: 2394-8418

**Keywords:** Bayonet shaped canals; Multiple canals; Root canal anatomy; Root canal instrumentation

## Case Report

# Endodontic Management of Aberrant Root Canal Anatomy in Premolars - A Report of Two Cases

### Abstract

Premolars are recognized for their aberrant root canal anatomy. The unique feature of dilacerations and multiple root canals pose utmost challenge in the endodontic management. A clinician is required to have an insight of the morphology of tooth related to its shape, form and structure prior to commencing root canal treatment. This article describes the endodontic management of two cases of aberrant root canal anatomy in premolars.

This paper describes the endodontic management of premolars with anatomic variations in the root canals that were identified during routine endodontic treatment.

### Case Report 1

A 19-year-old female patient reported to the Department of Conservative Dentistry and Endodontics, with the chief complaint of food lodgment in her upper right and lower left back tooth. There was associated history of mild pain while biting. Her medical and family history was noncontributory. Intra oral examination revealed a deep carious lesion with respect to the mandibular right second premolar (45) and maxillary left first premolar (24). On evaluation of the pulp status, both the teeth showed no response with heat (gutta-percha stick), cold (ice piece) and electric pulp testing (Parkell Electronics Division, Farmingdale, NY). The teeth were tender to percussion suggestive of symptomatic apical periodontitis. Intraoral periapical radiograph (IOPA) in relation to 45 and 24 revealed deep proximal caries involving the pulp (Figure 1). There was also widening of periodontal ligament space confirming the diagnosis of apical periodontitis in both the teeth. Root canal treatment for 45 and 24 was planned out. Intraoral periapical radiographs revealed

## Introduction

Root canal anatomy is a highly complex with over time clinicians missing canals, or unable to negotiate them properly. The successful outcome of an endodontic treatment demands the thorough knowledge of the internal anatomy of the root canal system [1,2]. Failure to recognize the variations in root canal anatomy may result in unsuccessful endodontic outcomes. Even in teeth with a low frequency of abnormal root canal anatomy, the possibility of additional root canals has to be considered in the clinical and radiographic examination of the patient. The incidence of number of roots and the number of canals which have been reported in the endodontic literature greatly varies [3,4]. Dilacerations refers to an angulation that may occur anywhere along the length of the tooth (crown or root) [5,6]. Root dilacerations may occur either unilaterally or bilaterally [7]. The direction of root dilacerations should be considered in single or double planes. They can be categorized as mesial, distal, labial/buccal, or palatal/lingual [8]. If the roots bend mesially or distally, the dilaceration is clearly apparent on a periapical radiograph. However, when the dilaceration is toward the labial/buccal or palatal/lingual, the x-ray beam passes through the deflected portion of the root in an approximately parallel direction. The dilacerated portion then appears at the apical end of the unaltered root as a rounded opaque area with a dark "spot" in its center that is caused by the apical foramen of the root canal. This appearance has been likened to a bull's-eye or a target appearance. When the root dilaceration is in labial direction, it is called a scorpion tooth. If a tooth is doubly affected, it is called as a bayonet dilaceration [9]. Bayonet shaped root canal are also called as "S" shaped canal which has two curvatures. The apical curvature in bayonet shaped root canal is very difficult to negotiate and may lead to strip perforation during instrumentation. Premolars often have very complex root canal anatomy and morphology with finely tuned and synchronized small tributaries running all through the length of the root canal making it challenging for the clinician to treat them effectively [10]. Clinicians have commonly encountered with bifurcating canals, multiple foramina, fins, deltas, loops, cudle-sacs, inter-canal links, and accessory canals in premolars.

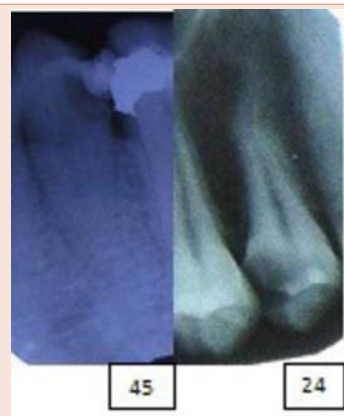

Figure 1: Preoperative IOPA radiograph of teeth #45 and #24.

the presence of double curved canals (S shaped) in both the teeth suggestive of bayonet shaped canals.

After obtaining the informed consent, local anesthesia was administered using 2% lignocaine and 1:100000 adrenaline (Neon Laboratories Ltd. Mumbai, India) and endodontic therapy was initiated under rubber dam isolation. A conventional endodontic access opening was made using Endo round carbide bur (ISO 014) and Endo-Z FG burs (Dentsply Maillefer, Ballaigues, Switzerland) under rubber-dam isolation. Canal patency was established using #10 K file (Mani Inc- Tochigi Ken, Japan). Working lengths were established using IOPA with the help of #15 K-flex file (Mani Inc-Tochigi Ken, Japan) using balanced force technique. Working length in tooth 24 was, 22 mm (buccal canal) and 22.5 mm (palatal canal). In the tooth 45, the working length was 24 mm.

Coronal enlargement was done for both the canals using Pre-Race rotary instruments (FKG Dentaire, Swiss Dental Products) and shaping and cleaning of the root canals were performed using Hyflex files (Coltene-Whaledent, Switzerland) till #25 (4%). The canals were irrigated with 5ml of 2.5% sodium hypochlorite (NaOCl) for 1 min after each instrument change. Smear layer removal was carried out using 5ml of 17% ethylenediaminetetraacetic acid (EDTA) (Merck, Germany) solution for 1min. All the irrigation procedure was performed using 29 gauge stainless steel needle (NaviTip, Ultradent Products. Inc. USA). The canals were then dried with sterile paper points (Dentsply Maillefer, Ballaigues, Switzerland). Calcium hydroxide powder (Nice Chemicals, Pvt. Ltd. Cochin, India) was mixed with propylene glycol, made into a paste and was placed as an intra-canal medicament using a lentulospiral (Dentsply Maillefer, Ballaigues, Switzerland). The access cavity was then temporarily sealed with Cavit (3M ESPE, St Paul, MN, USA). The patient was recalled after one week for second appointment. On recall, the patient was asymptomatic and the teeth were non tender to percussion. The canals were then cleaned with #25 H file and irrigated with 5ml of 17% EDTA (Merck, Germany) for 1 min using 29 gauge stainless steel needle to remove the remnants of the calcium hydroxide. Finally the canals were irrigated with 5ml of saline and dried using sterile paper points. Master cones (Dentsply Maillefer, Ballaigues, Switzerland) were selected and the canals were obturated with gutta percha (Dia Dent, Mumbai, India) and AH Plus sealer (Dentsply, Maillefer, Switzerland) using single cone technique (Figure 2). The access cavity was then restored with composite resin (3M ESPE, St, Paul, MN, USA) (Figure 2). Post-operative instructions were given and the patient was reviewed after a month and was found to be asymptomatic.

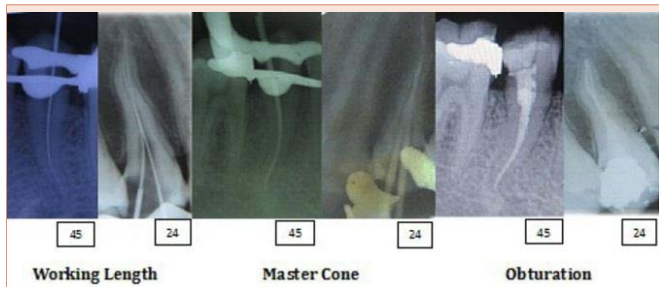
## Case Report 2

A 32 year old male patient reported to the Department of Conservative Dentistry and Endodontics with the chief complaint of decay in his lower right back teeth. History revealed that he had mild pain which was occurred while having food. Medical and family histories were non-contributory. On intraoral examination, a deep proximal carious lesion was seen in relation to his mandibular right first (44) and second premolar (45) teeth. On pulp sensibility testing using (gutta-percha stick), cold (ice piece) and electric pulp testing (Parkell Electronics Division, Farmingdale, NY), 44 showed no

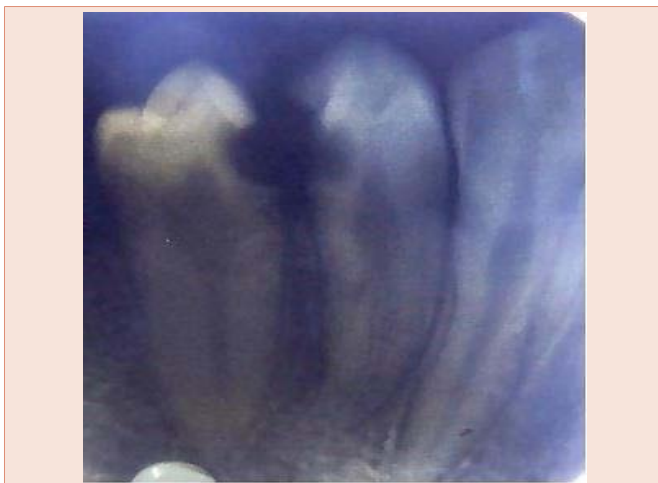response while 45 had a positive response. An intraoral periapical radiograph (IOPA) revealed deep proximal carious lesion involving pulp with respect to 44. In relation to 45, proximal caries was close to the pulp without the pulpal involvement (Figure 3). After obtaining the informed consent, caries was excavated with respect to 45. Calcium hydroxide (Dycal, Dentsply, Germany) was placed in the deepest portion of the cavity and was the cavity was temporized using zinc oxide eugenol cement (Deepak Enterprise, Mumbai, India). On examination of IOPA in relation to 44, the periodontal ligament outline suggested of two roots. Local anesthesia was administered using 2% lignocaine and 1:100000 adrenaline (Neon Laboratories Ltd. Mumbai, India) and endodontic therapy was initiated under rubber dam isolation. To gain sufficient access to the root canals, the access cavity was prepared wider bucco-lingually using Endo-Z FG burs (Dentsply Maillefer, Ballaigues, Switzerland) as the roots were oriented in bucco-lingual direction. The coronal pulp chamber was unusually long and the separation of the roots was from the middle third of the root canal system. After careful inspection, two canal orifices were located and patency was ascertained using #10 K-file (Mani Inc- Tochigi Ken, Japan). Working length was determined using #15 K files (Mani Inc- Tochigi Ken, Japan) which was 20 mm for both the canals. Shaping and cleaning of the root canals were performed using Protaper Next files (Dentsply Maillefer, Ballaigues, Switzerland) till X2. The canals were irrigated with 2.5% NaOCl for 1 min after each instrument change. Smear layer removal was carried out using 5ml of 17% EDTA (Merck, Germany) solution for 1min. All the irrigation procedure was performed using 29 gauge stainless steel needle (NaviTip, Ultradent Products. Inc. USA). The canals were dried using sterile paper points (Dentsply, Maillefer, Ballaigues, Switzerland). Calcium hydroxide powder (Nice Chemicals, Pvt. Ltd. Cochin, India) was mixed with propylene glycol, made into a paste, and placed in the root canals as intracanal medicament by using a lentulospiral (Dentsply Maillefer, Ballaigues, Switzerland). The access cavity was temporarily sealed with Cavit (3M ESPE, St Paul, MN, USA). The patient was recalled after one week, and the canals were then instrumented with #25 H file and irrigated with 5 ml of 17% EDTA (Merck, Germany) solution for 1 min using 29 gauge stainless steel needle to remove the calcium hydroxide paste. The root canals were finally irrigated with 5 ml of saline for 1 min and were dried using sterile paper points (Dentsply, Maillefer, Ballaigues, Switzerland). Master cones were selected and the obturation was performed by lateral compaction and vertical condensation technique using gutta percha (Dentsply, Maillefer, Ballaigues, Switzerland) and AH Plus sealer (Dentsply, Maillefer, Switzerland) (Figure 4). Post endodontic restoration was done using composite resin (3M ESPE, St. Paul, USA).

## Discussion

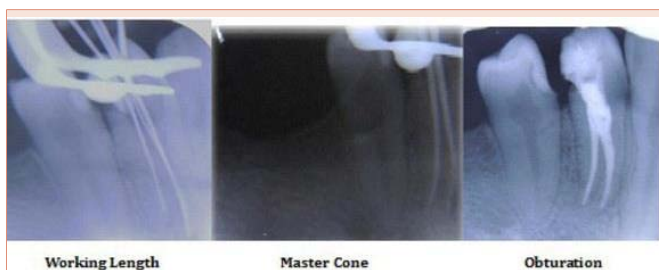The presence of extra roots or canals in mandibular premolars is undoubtedly an endodontic challenge. Numerous studies have reported the prevalence of multiple canals in premolars. Jain A et al. [11], reported the prevalence of 11.59%, while Sharma D et al. [12], reported 26.6% and Velmurgan N et al. [13], showed 27% chances of finding two canals in mandibular premolars. In the present case series, Vertucci's classification was used to determine the pattern of the root canal. In the first case, the tooth 24 had type IV Vertucci's



**Figure 2:** IOPA radiograph of working length, master cone and post obturation of teeth #45 and #24.



**Figure 3:** Preoperative IOPA radiograph of teeth #44 and #45.



**Figure 4:** IOPA radiograph of working length, master cone and post obturation of tooth #44.

configuration, while tooth 45 had type I Vertucci's configuration. In the second case, the tooth 44 had type IV Vertucci's configuration. Various challenges can be encountered in the successful management of bayonet shaped roots. One of the main challenges is the shortcoming of periapical radiographs, in which only the curvatures in mesio-distal plane is visible, although curvatures in the bucco-lingual plane are also evident in many teeth [14]. The other challenge is the difficulty in exploration and negotiation of the root canals due to the inability to continuously follow the root canal curvature, which might result in blocking of the canal, ledging, transportation, zipping, perforation, and instrument separation [15].

The incidence of these procedural errors can be reduced by decreasing the restoring force, by means of which straight file has to bend against the curved dentin surface or decreasing the length of the file which is aggressively cutting at a given span. Decreasing the force can be done by precurving the file, extravagant use of smaller number files, use of intermediate size of files or use of flexible files [16]. In the present case series, NiTi K flex files were used during the instrumentation of the root canals. These files are extremely flexible and can follow canal curvature. Thus, pre-curving of instruments was not required and also the non-cutting tips of these NiTi K flex files instruments prevented zipping or ledging.

Decreasing the length of actively cutting files is achieved by use of anti-curvature filing, changing the canal preparation techniques, i.e. use of coronal pre-flaring and crown down technique or by modifying the cutting edges of the instrument. Cutting edges of the files can be modified by dulling the flute on outer surface of apical third and inner portion of middle third by using a diamond file [16]. In present case series, 25 mm long instruments were used for the preparation of bayonet shaped root canals. Shorter size instruments could not be used due to longer length of the root canals.

In the present case series, bayonet shaped root canals were successfully managed by # 8k file in watch-winding motion to confirm the canal patency. After exploring the canal, crown-down sequence of instrumentation with NiTi files was followed, as early coronal flaring leads to greater tactile awareness of the apical constriction and reduce coronal binding of instruments. HyFlex<sup>®</sup> CM<sup>™</sup> NiTi rotary files were chosen for managing bayonet shaped root canals since, these files have been manufactured utilizing a unique process that controls the material's memory, making the files extremely flexible but without the shape memory of other NiTi files. This gives the file the ability to follow the anatomy of the canal very closely, thus reducing the risk of ledging, transportation or perforation [17].

The cleaning and shaping of two rooted premolar in the present case series has been carried out using Protaper Next rotary files. These files have a patented, off-centred, rectangular cross section giving them a unique, snake-like swaggering movement. This improved action creates an enlarged space for debris removal, optimises the canal tracking and reduces binding [18].

## Conclusion

The clinician should be astute enough to identify the presence of unusual number and morphology of root canals. A thorough knowledge of root canal anatomy and its variations, careful interpretation of the radiograph, close clinical inspection of the floor of the chamber, proper access preparation and a detailed exploration of the interior of the tooth are essential for a successful treatment outcome. Also, the clinicians should be aware of all the basic principles, modification and latest technology of endodontic therapy to manage these kinds of cases.

## References

1. Rodig T, Hulsmann M (2003) Diagnosis and root canal treatment of a mandibular second premolar with three canals. *Int Endod J* 36: 912-919.



2. Krasner P, Rankow HJ (2004) Anatomy of the pulp chamber floor. J Endod 30: 5-16.
3. Trope M, Eifenbein L, Tronstad L (1986) Mandibular premolars with more than one root canal in different race groups. J Endod 12: 343-345.
4. Zillich R, Dowson J (1973) Root canal morphology of mandibular first and second premolars. Oral Surg Oral Med Oral Pathol Oral Radiol 36: 738-744.
5. Tomes J (1848) A course of lectures on dental physiology and surgery. London: Gryphon Editions, Ltd.
6. Jafarzadeh H, Abbott PV (2007) Dilaceration: review of an endodontic challenge. J Endod 33: 1025-1030.
7. Lin L, Dowden WE, Langeland K (1982) Bilateral dilacerations. J Endod 8: 85-87.
8. Pramod John (2014) Textbook of Oral Medicine, 3rd ed, JP Medical Ltd 85.
9. ValladaresNeto J, de Pinho Costa S, Estrela C (2010) Orthodontic-surgical-endodontic management of unerupted maxillary central incisor with distoangular root dilaceration. J Endod 36: 755-759.
10. ElDeeb ME (1982) Three root canals in mandibular second premolars: literature review and a case report. J Endod 8: 376-377.
11. Jain A, Bahuguna R (2011) Root canal morphology of mandibular first premolar in a gujarati population - an in vitro study. Dent Res J (Isfahan) 8: 118-122.
12. Sandhya R, Velmurugan N, Kandaswamy D (2010) Assessment of root canal morphology of mandibular first premolars in the Indian population using spiral computed tomography: an in vitro study. Ind J Den Res 21: 169-173.
13. Velmurugan N, Sandhya R (2009) Root canal morphology of mandibular first premolars in an Indian population: A laboratory study. Int Endod J 42: 54-58.
14. Ingle JI (2005) In: PDQ Endodontics. Hamilton, Ontario: BC Decker, Root canal preparation 129.
15. Walton RE, Torabinejad M (1996) Principles and practice of endodontics. 2nd ed. Philadelphia: WB Saunders.
16. Ansari I, Maria R (2012) Managing curved canals. Cont Clin Dent 3: 237-241.
17. [www.hyflexcm.com](http://www.hyflexcm.com)
18. <https://www.dentsply.co.uk/Products/Endodontics/Endodontic-Files/Rotary-Files/ProTaper-Next.aspx>.

**Copyright:** © 2016 Jain H. This is an open-access article distributed under the terms of the Creative Commons Attribution License, which permits unrestricted use, distribution, and reproduction in any medium, provided the original author and source are credited.

**Citation:** H Jain, Ballal NV (2016) Endodontic Management of Aberrant Root Canal Anatomy in Premolars - A Report of Two Cases. J Dent Probl Solut 3(1): 008-011. DOI: 10.17352/2394-8418.000025