

Nezar Watted¹ and Muhamad Abu-Hussein^{2*}

¹University Hospital of Würzburg, Clinics and Policlinics for Dental, Oral and Maxillofacial Diseases of the Bavarian Julius-Maximilian-University Wuerzburg, Germany, Center for dentistry, and Arab American University, Palestine
²Department of Pediatric Dentistry, University of Athens, Greece

Dates: Received: 19 September, 2016; Accepted: 24 October, 2016; Published: 25 October, 2016

*Corresponding author: Abu-Hussein Muhamad, DDS, MScD, MSc, M Dent Sci (Paed Dent), FICD, Department of Pediatric Dentistry, University of Athens, 123 Argus Street, 10441 Athens, Greece, E-mail; abuhusseinmuhamad@gmail.com

www.peertechz.com

ISSN: 2394-8418

Keywords: Migration; Transposition; Ectopic eruption; Mandible; Canine; Lateral incisor

Case Report

Dental Transposition of Mandibular Canine and Lateral Incisor

Abstract

Dental transposition is a form of ectopic eruption with change in position of normal adjacent teeth. Its prevalence is very low in general population and could be frequently missed on oral examination. This article reports a case of early orthodontic treatment of a rare unilateral mandibular right lateral incisor – canine transposition.

Introduction

Tooth transposition is defined as ‘the positional interchange of two adjacent teeth particularly of the roots or the development or eruption of a tooth in a position occupied normally by a non-adjacent tooth. Tooth transposition is an anomaly of eruption characterized by interchanged position of two adjacent teeth [1,2].

Transposition may affect both sexes equally and, although it may occur in the maxilla or in the mandible, the frequency of maxillary permanent canine involvement is the greatest [3]. In the maxilla the canine is transposed most frequently with the first premolar (Figure 1a,b), less often with the lateral incisor followed rarely by central incisor or second premolar. In the mandible transposition is reported to involve the canine and lateral incisor only [3].

Prevalence varies according to different authors. Thus, it was found 0.38% in Turkey, 0.13% in Saudi Arabia, 0.43% in India. Prevalence in syndromic patients is significantly higher. Tooth transpositions are observed at a rate of 14.29% in patients with Down’s syndrome and at a rate of 4.1% in cleft palate patients. According to most researchers, transposition is more frequent in women, in the maxilla, as a unilateral condition and in the left facial half [4].

Unilateral tooth transpositions have been reported far more

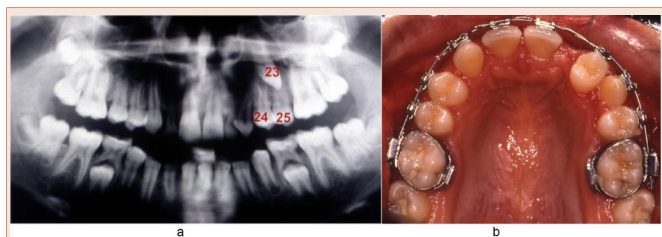


Figure 1: Transposition In the maxilla the canine-23-is transposed with the first premolar 24.

frequently than bilateral and left side becomes the victim more frequently than the right side. Only one case of asymmetric transposition in both arches was found in the literature, involving maxillary canine and the first premolar on the right side and of the mandibular canine and the lateral incisor on the left side [4,5].

Canines are the most often dental in experiencing transposition. The dental of upper canine is probably dental who is the most varied position in the composition of human teeth and important for the orthodontist who often must find their location and move it [3]. These teeth are often out of dental arch to the facial and palatal. It appears that from the canine transposition of first upper premolar sometimes show on the transposition of canine eruption in the side of facial between the first and second premolars, especially if there is still deciduous canine, so that it affects deficiency of arch length. Canine often rotates to the mesial, while the first premolar rotates to the distal and sometimes rotates to mesiopalatal [3,6].

The causes are not definitely known. Nodine reported that abnormal displacement of the dental lamina in the embryonic life is the cause of the displacement and non-eruption of the canines [7].

Bruszt, believed that the bud of the canine has risen in front of the incisors and its crown is displaced to the contralateral side during growth and eruption [8].

Sutton, has suggested that an abnormally strong force of eruption directed towards the crown drives the canine through the midline, which is a dense bone [9].

Broadway suggested that displacement of the crypt of the affected tooth is the cause [10].

Bennet emphasized that a very small obstacle like a small root fragment would be sufficient to divert a tooth from its normal path of eruption [11].

Vichi1 et al., mentioned that proclination of the lower incisors, increased axial inclination of unerupted canine and an enlarged symphyseal cross-sectional area of the chin are causative factors [12].

Javid reported that the conical shape of the crown and root of the mandibular canine facilitated its transmigration [13].

A complete transposition is one in which both the crown and the entire root of the involved teeth exchange places in the arch and

are fully parallel. In incomplete transposition (also called “pseudo” or “par-tial-transposition”) the crowns may be transposed while the root apices remain in the normal position.²⁶ Alternatively, the crowns may be in correct order while the root apices are transposed, thus the two involved teeth overlap and their long axes cross each other [14,15].

Tooth transposition is often accompanied by several congenital dental disturbances such as peg-shaped lateral incisors, hypodontia, ankylosed milk teeth, severely rotated teeth, and dilacerated teeth. Shapira et al reported 18.5% of the individuals with transposition to have one or more missing teeth, excluding third molars. Lateral incisor was the most frequently missing tooth (14%). This was followed by the maxillary (6%) and the mandibular (3%) second premolar. Small sized lateral incisors were detected in 9% of the cases with transpositions. 32% individuals had retained milk teeth, 45% had severely rotated maxillary canines and 14% had impacted third molars [16].

Mandibular transposition is rare and it is frequently reported only with mandibular canine and lateral incisor. To the best of our knowledge, we report the first case report of unilateral complete transposition of mandibular right canine with lateral incisor of a Syrian immigrant patient in literature. The study was done according to the ethical principles of the Declaration of Helsinki.

Case Report

A 14-year-old male patient of Syrian origin, reported to the outpatient to my private dental clinic, Athens, Greece. He complained of pain in a decayed tooth in lower right front region. He also complained of food impaction between teeth and difficulty in mastication. His medical history and personal history was non-contributory. Past dental history revealed that he had undergone uneventful extraction.

On intra-oral examination, the mandibular right lateral incisor was present in place of mandibular right canine and canine in place of lateral incisor. Overjet and overbite was normal. There was no other abnormality present in the oral cavity. Intra-oral periapical radiograph and orthopantomograph (OPG) further confirmed this entity with no other associated abnormality in the maxillary or mandibular arches (Figure 2).

Clinical examination revealed mobile deciduous first molar and retained deciduous lateral incisor on the right side and permanent lateral incisor on the contra lateral side. The clinical findings may suggest that the permanent lateral incisor is congenitally missing, impacted, or deflected from the path of the eruption.

If early interceptive measures of up righting the lateral incisor to its correct position next to the central incisor are not undertaken in a timely fashion that is before the permanent canine erupts, it will erupt in a transposed position with the lateral incisor already erupted ectopically.

The early detection and timely prevention of such a condition is recommended to prevent the development of this transposition. On early diagnosis of developing transposition interceptive treatment was initiated, which consisted of immediate removal of mandibular left deciduous first molar. Extraction of mandibular deciduous first molar

was done under LA. The lateral incisor with prominent mammelons was noticed in the extraction socket. The retained deciduous lateral incisor and canine were also removed. Impression of the lower arch was made and cast was poured to appreciate the transposition of the erupting permanent lateral incisor. Comprehensive orthodontic treatment was instituted using straight wire technique with elastic chain. The permanent right lateral incisor was uprighted and aligned to its normal position in the arch within 8 months' time. Another panoramic radiograph was taken. After complete orthodontic correction, the vitality of the transposed tooth was checked and the tooth was found vital (Figure 3).

Following the movement, the lateral incisor must be retained in its new position until the permanent canine erupts distal to it. Lingual retainer of reinforced composite wire splint was used. After 1 ½ years of the initiation of the orthodontic treatment eruption of the first premolar was noticed. Permanent right mandibular canine has not yet erupted. Space deficiency was noticed for the permanent mandibular canine on the left side of the arch. Further follow-up and treatment for the same is taken under consideration (Figure 4a-h).

Discussion

The literature shows that any tooth can show transposition. It occasionally happens that a central incisor is situated between the lateral incisor and the canine of the same side, right central incisor may be situated in the place of the left and the left in the place of the right incisor. It might also be that a lateral incisor is situated between the canine and first premolar and sometimes canine erupts between the first and second premolar [4,5]. Statistically, the maxillary permanent canine is the most frequently involved tooth in transposition (0.135-

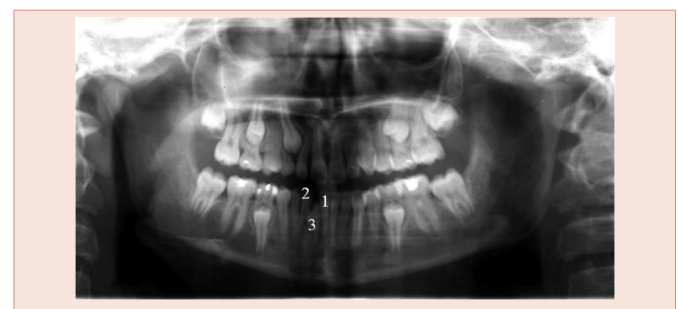


Figure 2: Transposition between the mandibular right lateral incisor and mandibular right canine, before the treatment.

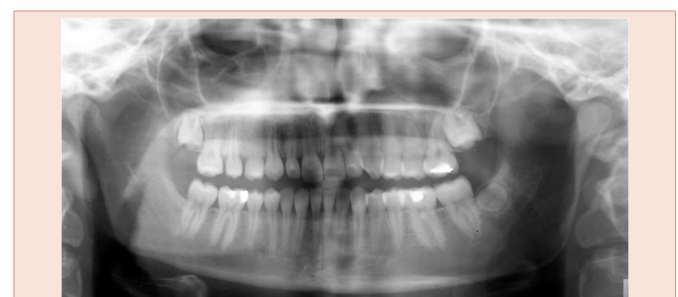

Figure 3: Transposition between the mandibular right lateral incisor and mandibular right canine, after the treatment.

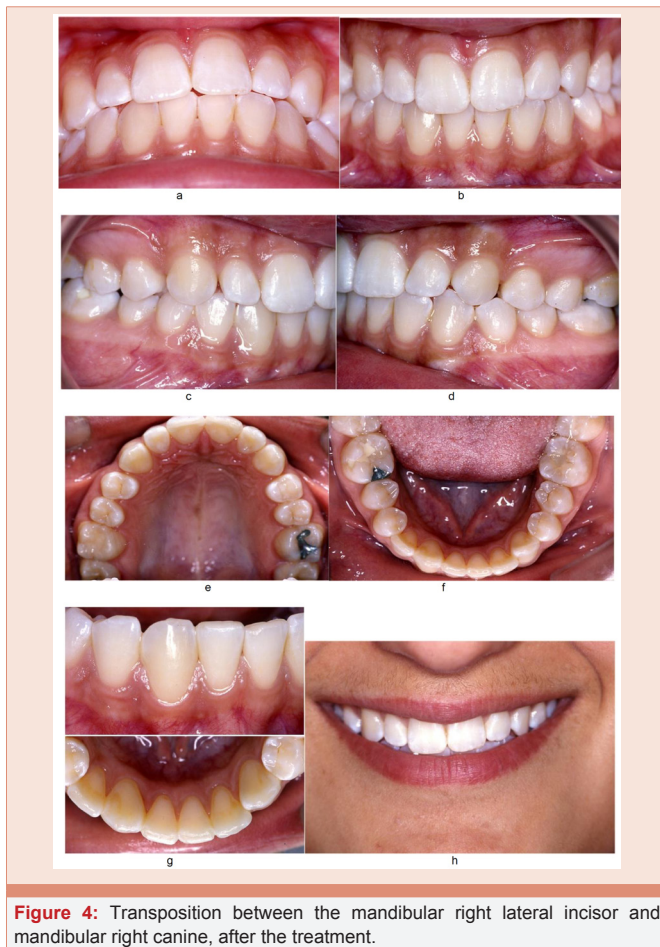

Figure 4: Transposition between the mandibular right lateral incisor and mandibular right canine, after the treatment.

0.51%) and shows the highest incidence of transposition with the first premolar [6]. Although less frequent, but canine transposition has also been documented with lateral incisor, central incisor and rarely with the second premolar or first molar [3,7,8].

Treatment options

- 1) Surgical removal: surgical removal of the transmigrated canines is one form of treatment of such cases.
- 2) Transplantation: when there is enough space to accommodate the canine
- 3) Exposure and Orthodontic alignment.
- 4) Observation to give the opportunity of seeing whether any further migration takes place after tooth growth has been completed

Mupparapu classified (Type 1-5) based on their migratory pattern and the final position within the jaw when diagnosed.

- ▶ Type 1: Canine positioned mesio-angularly across the midline within the jaw bone, labial or lingual to anterior teeth and the crown portion of the tooth crossing the midline.
- ▶ Type 2: Canine horizontally impacted near the inferior border of the mandible below the apices of the incisors.

- ▶ Type 3: Canine erupting either mesial or distal to the opposite canine.
- ▶ Type 4: Canine horizontally impacted near the inferior border of the mandible below the apices of either premolars or molars on the opposite side.
- ▶ Type 5: Canine positioned vertically in the midline. (The long axis of the tooth crossing the midline) irrespective of eruption status [18].

The present reported case showed the right mandibular canine tip crossing the midline reaching little beyond or below the roots of the incisors (Type 2).

Peck S. and Peck L classified maxillary tooth transposition in a classic article published in May 1995 in American journal of orthodontics and dentofacial orthopedics. On the basis of anatomic factors, five types of maxillary tooth transpositions were firmly identified among 201 people in their study. The classification is stated below according to the teeth involved. 1. Canine-First premolar [Mx. C. P1] 2. Canine-Lateral incisor [Mx. C. 12] 3. Canine to First molar site [Mx. C to M1] 4. Lateral incisor-Central incisor [Mx. 12. I1] 5. Canine to Central incisor site [Mx. C to I1] [1,2,5].

Tooth transposition in mandibular arch is extremely rare (0.003%). The most common teeth involved are canines and lateral incisors [4]. A few cases of mandibular second premolar and first molar have also been reported in literature.

Variety of Transposition: Transposition may be complete or incomplete [17]. It may be unilateral or bilateral [18]. In complete transposition, both the crown and entire root of involved teeth interchange their places while in incomplete type, only the crowns are interchanged and the root apices remain in their normal position [19]. Unilateral transposition occurs more frequently than bilateral (12:1 ratio) and the left side is reported to be more frequently involved than the right side (2:1 ratio) [20].

Dental transposition is identified as complete transposition when the crowns and the roots of the involved teeth exchange places in the dental arch and incomplete transposition when the crowns are transposed, but the roots remain in their normal positions. The canine is one of the most commonly involved teeth in the transposition phenomenon [19,20].

Etiology of transposition is not known. Proposed causes include abnormal displacement of tooth bud or deviation during tooth development, genetic interchange between tooth buds, mechanical interferences in eruption, early loss or prolonged retention of deciduous teeth [21].

In general population, the prevalence of dental transposition is around 0.4%. It frequently involves mandibular canine/lateral incisor and on the left side. Herewith, we give the first report of mandibular canine transposition and first premolar in a male Libyan patient for the first time in literature [22].

Early diagnosis of a developing transposition is extremely important and has a great influence on prognosis. This may usually be performed by a radiographic examination when the patient is

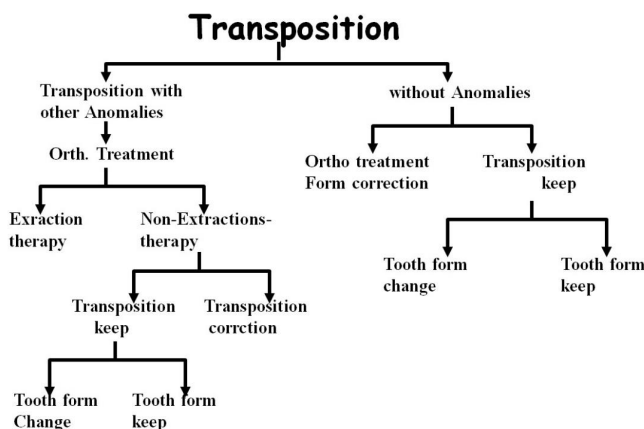
between 6 and 8 years of age. When the alteration is detected early, interceptive procedures including extraction of deciduous teeth and placement of eruption guides for the permanent teeth may be performed, thus preventing complete development of the anomaly. On the other hand, when transposition is detected at a later stage, orthodontic treatment planning and intervention must be addressed [1,3]. Upper canine premolar transposition in adult patients allows consideration of several treatment options, with or without extraction of the premolar [3], (Table 1).

If the anomaly is bilateral, the same teeth are affected on both sides; whereas asymmetrical transposition is rare. Transposition has never been reported in deciduous dentition. Many theories have been proposed to explain the etiology of transposition includes, altered eruption paths, positional interchange of tooth buds presence of retained primary teeth and trauma [1]. In the present case mandibular canines are transposed with mandibular lateral incisors, which is a very rare and unique presentation. Shapira reported that in mandibular arch transposition of canines could be developed due to distally directed eruption of permanent lateral incisor which leads to premature loss of primary canine. Three treatment options were given to the patient were include, to leave the dentition as it is [19].

To mimic the transposed canines into lateral incisors and transposed lateral incisors into canines and simulate the ideal dentition that includes relatively simple mechanics and lesser treatment duration. It has a several esthetic and functional concerns especially the canine guided occlusion will be lost and gingival contour is altered in the anterior region which requires an additional periodontal recontouring procedures [7] and to correct the transposed canine into its original position by fixed orthodontic treatment modality. Which depends on various factors such as the patient’s degree of occlusion, dental crowding, esthetics, the position of the radicular apices, socio-economic factors, and the last but the major factor is patient’s motivation [1,4,5].

Unilateral transposition and particularly left side is more commonly involved than bilateral transposition. The term complete transposition is used when both the crown and the entire root structure of the involved teeth are found parallel in their transposed position and an incomplete transposition, if the transposition is of the crown, but not the root apex [23,24].

Table 1: Management of transposition.



The normal position of a developing mandibular permanent lateral incisor is lingual to its predecessor, and upon eruption it migrates labially to resorb the root of the deciduous tooth [25-28]. A possible explanation for the displacement of the developing lateral incisor could be the prolonged retention of its predecessor. Alternatively, an abnormal path of eruption of the permanent tooth may be responsible for the lack of resorption of the over retained deciduous tooth. All reported cases of ectopic mandibular permanent lateral incisors involved retained deciduous teeth. Many also exhibited an early exfoliation of the deciduous first molar [27-29]. It is not clear, however, whether retained deciduous teeth may be the cause, or the result of the displacement and ectopic eruption of their successors. Unlike the maxilla, where canine migration is the major cause for transposition, in the mandible the distal displacement of the permanent lateral incisor is the main cause for transposition [25,26].

Positional changes of tooth anlage at the, very early stages of odontogenesis as well as genetic control within the dental follicle, were also suggested as possible causative factors for tooth transposition [3,21,30].

In the present case, transposition is diagnosed as complete type with the help of clinical examination and radiographic findings. So, initially the lateral incisor has to be moved lingually to remove interference for the canine, and canine should be moved distally with orthodontic mechanics and after reversing the transposed teeth, the achieved treatment results will fulfill all the functional and esthetic considerations and maintain a stable occlusion.

Conclusions

Early diagnosis of transpositions helps in correction with less chance of injuries to the surrounding tissues. This is possible with periodic clinical examination and complete radiographic analysis. Both function and esthetics restoration in patients with tooth transposition depends on the treatment design and cooperation of the patient.

References

1. Watted N, Abu-Hussein M., Hussein E, Proff P (2015) A Dental Transposition: Literature Review and Clinical Management. *Journal of Dental and Medical Sciences* 14: 80-85.
2. Peck S, Peck L, Kataja M (1998) Mandibular lateral incisor-canine transposition, concomitant dental anomalies, and genetic control. *Angle Orthod* 68: 455-466.
3. Peck S, Peck L (1995) Classification of maxillary tooth transpositions. *Am SJ Orthod* 107: 505-517.
4. Abu-Hussein M, Watted N (2015) Prevalence of Tooth Transposition in Arab Israelian(Arab48) Population;A retrospective study. *Journal of Dental and Medical Sciences* 14: 65-71.
5. Peck L, Peck S, Attia Y (1993) Maxillary canine–first premolar transposition, associated dental anomalies and genetic basis. *Angle Orthod* 63: 99-109.
6. Watted N, Hussein E, Awadi O, Abu-Hussein M (2014) Transmigration of Impacted Canines: A Report of Two Cases and a Review of the Literature. *RRJDS* 2: 23-32.
7. Nodine AM (1943) Aberrant teeth, their history, causes and treatment. *Dent Items of Interest*. 65: 440-451.
8. Bruszt P (1957) On the migration of lower canines to the opposite side of the mandible. *Acta Morph* 7: 199-207.

9. Sutton PRN (1969) Migration and eruption of non-erupted teeth. A suggested mechanism. *Aust Dent J* 14: 269-270.
10. Broadway RT (1987) A misplaced mandibular permanent canine. *Br Dent J* 163: 357-358.
11. Bennett S (1931) Prehistoric specimen- inverted canine in mandible of a chile. *Int. The Dental Record*. 138.
12. Vichi M, Franchi L, Bassarelli V (1991) *Minerva. Stomatology*. 40: 579-589.
13. Javid B (1985) Transmigration of impacted mandibular cuspids. *Int J Oral Surg* 14: 547-549.
14. Ruprecht A, Batniji S, El-Newelhi E (1985) The incidence of transposition of teeth in dental patients. *J Pedod* 9: 244-249.
15. Chattopadhyay A, Sirinivas K (1996) Transposition of teeth and genetic etiology. *Angle orthod* 66:147-52.
17. Shapira Y, Kuflinec MM (2001) Maxillary tooth transpositions: Characteristic features and accompanying dental anomalies. *Am J Orthod Dentofac Orthop* 119:127-134.
18. Mupparapu M (2002) Patterns of intra-osseous transmigration and ectopic eruption of mandibular canines: review of literature and report of nine additional cases. *Dentomaxillofacial Radiology* 31: 355-360.
19. Shapira Y (1980) Transposition of canines. *J Am Dent Assoc* 100: 710-712.
20. Al-Shawaf MD (1988) Bilateral asymmetrical transposition of teeth. Report of a case. *Am J Dent* 27: 41-43.
21. Abu-Hussein M, Watted N, Yehia M, Proff P, Iraqi F (2015) Clinical Genetic Basis of Tooth Agenesis. *Journal of Dental and Medical Sciences* 14: 68-77.
22. Abu-Hussein M, Watted N, Watted A, Abu-Hussein Y, Yehia M, et al. (2015) Prevalence of Tooth Agenesis in Orthodontic Patients at rab Population in Israel. *International Journal of Public Health Research* 3: 77-82.
23. Babacana H, Kilic B, Bicakc A (2008) Maxillary canine-first premolar transposition in the permanent dentition. *Angle Orthod* 78: 955-960.
24. Papadopoulou MA, Chatzoudib M, Kaklamanos EG (2010) Prevalence of tooth transposition. A meta-analysis. *Angle Orthod* 80: 275-285.
25. Gellin ME (1961) A method of predicting the initial eruptive pattern of the mandibular Permanent teeth by radiographic analysis. *J Dent Child* 28: 138-149.
26. Gellin ME, Haley JV (1982) Managing cases of over retention of mandibular primary incisors where their permanent successors erupt lingually. *J Dent child*. 49: 118-122.
27. Abu-Hussein M, Watted N, Abdulgani M, Abdulgani Az (2016) Tooth Autotransplantation; Clinical Concepts. *Journal of Dental and Medical Sciences* 15: 105-113.
28. Abu-Hussein M, Abdulgani Azzaldeen (2016) Intentional replantation of maxillary second molar; case report and 15-year follow-up. *Journal of Dental and Medical Sciences* 15: 67-73.
29. Abu-Hussein M, Watted N, Emodi O, Obaida Awadi (2015) management of lower second premolar impaction. *Journal Of Dental College Azamgarh* 1: 71-79.
30. Abu-Hussein M, Nezar W, Azzaldeen A (2015) The Curve of Dental Arch in Normal Occlusion. *Open Science Journal of Clinical Medicine* 3: 47-54.

Copyright: © 2016 Watted N, et al. This is an open-access article distributed under the terms of the Creative Commons Attribution License, which permits unrestricted use, distribution, and reproduction in any medium, provided the original author and source are credited.

Citation: Watted N, Abu-Hussein M (2016) Dental Transposition of Mandibular Canine and Lateral Incisor. *J Dent Probl Solut* 3(1): 045-049. DOI: 10.17352/2394-8418.000034