

Ibrahim Saeed Gataa^{1*}, Balkees Taha Garib² and Noroz Hama Rashid³

¹Department of Oral Surgery, School of Dentistry, Faculty of Medical Sciences, University of Sulaimani, Iraq

²Department of Oral Pathology, School of Dentistry, Faculty of Medical Sciences, University of Sulaimani, Iraq

³Sulaymanya Teaching Hospital, Iraq

Dates: Received: 08 March, 2015; Accepted: 30 March, 2015; Published: 31 March, 2015

***Corresponding author:** Ibrahim Saeed Gataa, Department of Oral Surgery, School of Dentistry, Faculty of Medical Sciences, University of Sulaimani, Iraq, Tel : 009647701467775; Email: dribsg@yahoo.com

www.peertechz.com

ISSN: 2455-4634

Keywords: Ameloblastoma, Mucous cells, PAS-D stain

Case Report

New Features in Mucous-Ameloblastoma. A Case Report of rare Entity

Abstract

Histologically ameloblastoma showed various forms of metaplastic changes. Evidence of mucous cells is a rare finding and only 9 cases were reported. We present a case of 80 year old male suffered from mandibular swelling for five years duration diagnosed as mucous ameloblastoma. Histopathological examination revealed a lot of mucous pools within the growth, a thin fibrous capsule surrounding the mass and a direct connection between growth islands and oral mucosa. This case highlights the features of rare type of ameloblastoma.

Introduction

Ameloblastoma (AB) is a well-known rare benign epithelial odontogenic tumor that more frequently involves the posterior region of the lower jaw at middle-aged male patient. Although it is slowly growing, it has local aggressive behavior and great tendency to recur if not properly excised. It has an unpredictable tendency to metastasize and required surgical en-bloc resection [1,2].

According to the WHO classification AB has different variants; solid / multicystic, extra osseous ameloblastoma, desmoplastic, unicystic type, beside malignant ameloblastoma and ameloblastic carcinoma [3]. Furthermore, histologically AB is highly polymorphic and undergoes various forms of metaplasia (follicular, plexiform, acanthomatous, granulomatous, desmoplastic [3] and even containing unusual finding [4]. However, the occurrence of the mucous cells in AB is rare phenomenon, mucous cells have reported in about 9 cases [5-12]. This report describes a distinct case of long duration ameloblastoma in elder patient exhibiting numerous large pools of mucin and peripheral fibrous wall that make it well separated from the bone.

Case Report

A-80-year old male presented to maxillofacial clinic in Sulaimanyia teaching hospital complained form right side facial swelling in cheek and submandibular area. The condition started five years ago (2010) as a small mandibular swelling increased in size gradually.

At July 2012 the patient attended the hospital for the management of the mandibular swelling. At that time, clinical examination indicated a hard mass, measured about 5X4cm and covered by normal skin. An incisional biopsy was done for him and showed to be ameloblastoma, but the patient refused surgical treatment.

Two years later the patient returned back to the hospital (August

2014) seeking help and treatment because the mass became larger and start to interfere with eating and speaking. On the presentation, the patient had extensive right side mandibular expansion; measuring 7X5 cm (Figure 1A). There was no paresthesia of the mandibular nerve and no trismus. The swelling exhibited diffuse margins and was painless and do not adhere to the overlying skin.

Intra orally, there was diffused swelling extending in an edentulous area from the distal surface of the mandibular right canine to the ramus antero-posteriorly obliterating the right buccal vestibule. The central area of the overlying mucosa showed large deep necrosis, the remaining mucosa stretched and erythematous (Figure 1E). There was no lymph node palpable in the neck.

Orthopantomography and CT examination revealed a large, well-defined unilocular radiolucency with a scalloped border and central septa. It extends from mandibular right edentulous premolar area to the ramus (Figure 1B and 1C).

A diagnosis of ameloblastoma was considered depending on the clinical, radiographic, and previous histopathological report of the lesion. Subsequently, it was removed by surgical excision as an en bloc resection (hemi mandibulectomy, Figure 1D), and the surgical specimen submitted for histologic examination.

Macroscopically, the surgical specimen is the right half of the mandible (from midline to the condyle). Only anterior teeth were present. The specimen measured 12X9 cm, (including the condyle head). The mass was grayish-white in color, rubbery with a smooth surface and was well separated from the bone at posterior border, fixed in formalin. The specimen sliced, and several samples were taken for histologic examination (one from the anterior bony margins). The cut surface showed nodular white-yellowish areas and numerous focal cystic spaces of variable sizes oozing thick mucinous material. The mass was well capsulated by thin smooth continues wall (Figure 1F).

Microscopic examination revealed numerous odontogenic

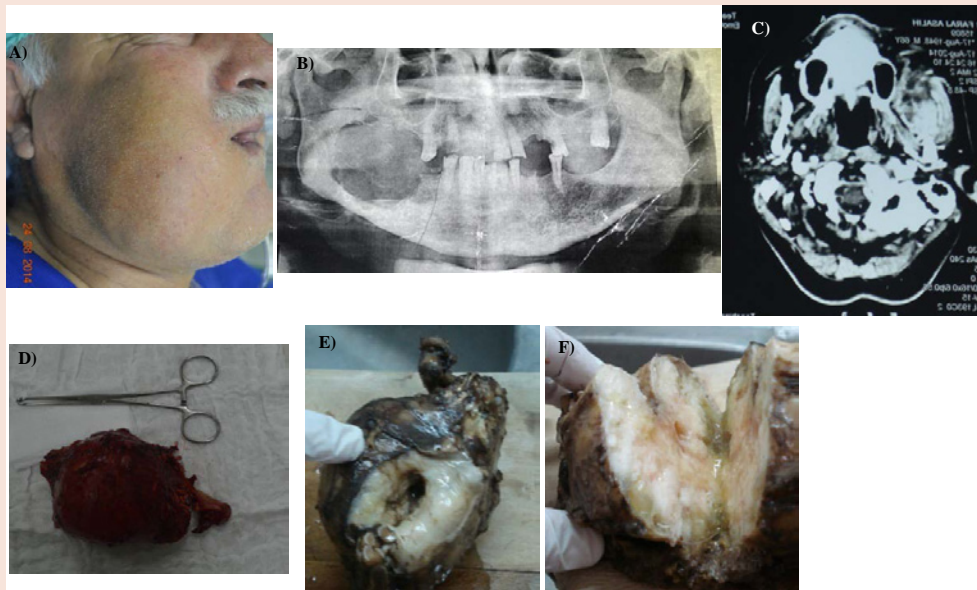


Figure 1: (A): Extra-oral clinical photograph of the tumor on the right side of the face. (B): Orthopantomogram is showing well-defined unilocular radiolucency extending from the right mandibular premolar area to right ramus. (C): Axial section of the lesion. (D): Tumor after surgical removal (E): Gross specimen showed necrotic central area on the superficial surface (F): The cut surface showed whitish solid nodules with evidence of small and large cystic spaces containing mucous secretion.

epithelial islands and multiple cystic spaces dispersed in a loose fibro-cellular stroma (Figure 2A). The follicles were surrounded by cuboidal or columnar cells with large nuclei and prominent nucleoli. Some of them with reversed polarity (ameloblast-like cells) (Figure 2B), however, the majority exhibited an absence of peripheral palisading. These islands were enclosing central stellate reticulum-like cells that may associate with few squamous metaplasia or mucous metaplasia with large cystic spaces filled with mucin. The mucous cells (pale cells) arranged in the form of lining with few papillary-like projections or they dispersed singly or in clumps inside the follicles (Figure 2D, 2E). These pale cells demonstrated a positive reaction for Periodic acid–Schiff–diastase (PAS-D) staining (Figure 2B, Figure 3). The mass was covered by stratified squamous epithelia on the upper surface and showed site of connection with tumor islands. While the remaining outer surrounding tissue showed continuous fibrous wall separating the lesion from the adjacent muscles and bone trabeculae (Figure 4).

Discussion

Clinically and radiographically, the present case mimics the typical presentation of solid intra-osseous ameloblastoma. However, in comparison to the reviewed cases of ameloblastoma associated with mucous differentiation, the age of our patient was older than the maximum reported age (53 years female [13]). The duration of previous cases varied from 2 months to 1.5 years, nevertheless our patient is elder patient and suffered longer period since its diagnosis (2years).

Grossly the mass was compressible and covered all-around by tense smooth surface. There was no bone covering shelf possibly due to the expansion induced by the existence of a considerable

amount of mucin within the mass. During sample sectioning, a thick yellowish material was flowing down from multiple micro and macro cystic spaces that exist throughout the mass. Nearly similar description was mentioned in one case of Tamgadge's et al. [5] report, while Hertenian and Kalfayan [12] just remarked to the existence of cloudy mucoid yellowish fluid within the cyst. On the other hand other studies did not mention gross mucin; they identified it under microscope PAS-stained sections. The upper surface of the mass was covered with oral mucosa, and histologically there was a connection between the oral and odontogenic epithelial islands. No such finding was reported in the previous nine cases. Therefore, further molecular analysis is needed to differentiate and clarify the role of oral mucosa the lesion.

The remaining microscopical descriptions do not much differ from other reports [1,8,10,12]. There are squamous metaplasia and extensive cystic degeneration. The mucous cells located and arranged within solid islands, or as single or group admixed with epithelial lining. The only remarkable difference was the number of cells and the amount of secretion. Hence, we thought that this could be linked to the age of the lesion, following Soundarya et al. [13] suggestion that the presence of mucous cells increases in odontogenic cysts with age of the lesion. Furthermore, the mass seemed to be surrounding by thin fibrous capsule separating it from remaining bone and muscles. Although it is well known that AB is locally aggressive, but the published information do not clearly describe the exact peripheral microscopic findings.

The presence of vacuolated and mucous cells in odontogenic cysts has been well described [14]. However, up today reviewing of published literatures regarding similar findings within ameloblastomas is limited, and exclusion of other lesions (mucoepidermoid carcinoma,

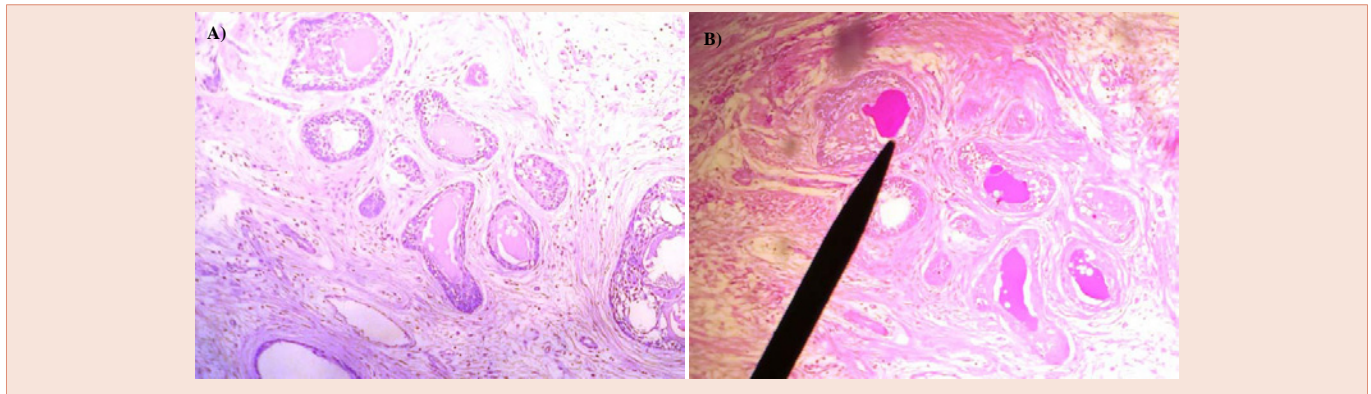


Figure 2: Photomicrograph is illustrating a mass predominated by numerous epithelial islands containing mucin pools (A) that proved to be PAS-D positive (B) Tumor stroma consists of a loose fibrous tissue, (Original magnification ×100).

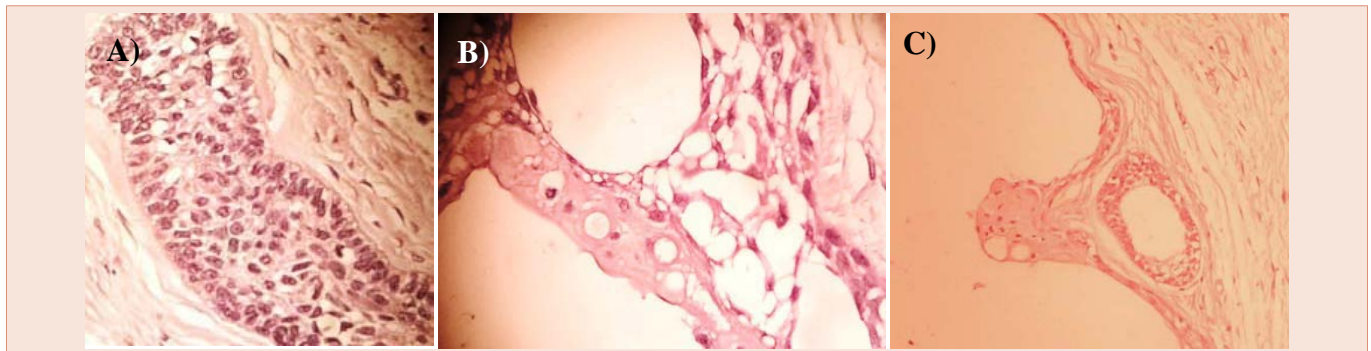


Figure 3: Tumor islands consist of odontogenic epithelium surrounded by columnar cells with reversed polarity (ameloblast-like cells) enclosing central stellate reticulum-like cells (A). The mucous cells arranged as lining (B) with few papillary-like projections (C). (Hematoxylin-eosin, original magnification ×400).

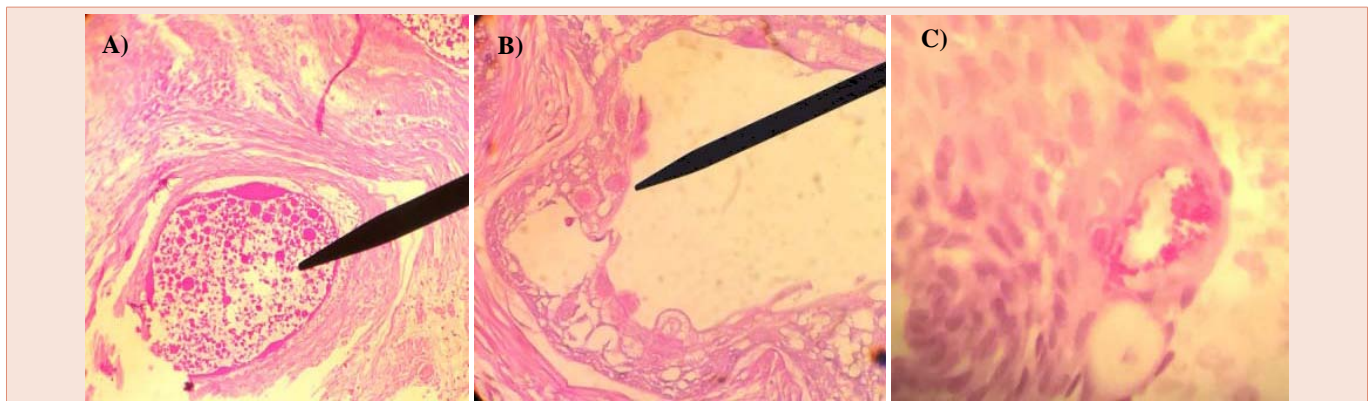


Figure 4: Periodic acid–Schiff–diastase stained sections. Tumor contains large cystic spaces filled with mucin (A, original magnification x100). The mucin-positive cells in the lining (B, original magnification x100) and admixed with odontogenic epithelial cells (C, original magnification x 400).

clear cell odontogenic tumor, or clear cell ameloblastoma) should be considered [8]. Most previous authors used the term “clear cells” as synonym for ‘mucous cells’, and they describe them as PAS-positive clear cells. It is important to remark that cells in clear cell AB do not mimic PAS-positive clear cells. They have single pyknotic nucleus [15] and were PAS-D negative. Therefore, one should not confuse

with morphological description and should select precise words like “pale or vacuolated” cells. In our case these cells were polyhedral pale cells having obvious nucleus and uptake PAS stain to show mucin.

Recent data indicated that the mucous cell in odontogenic cystic lesions have a mixed type of mucin (acidic, neutral or mixed). This finding resembles mucous cells from major salivary glands [16].

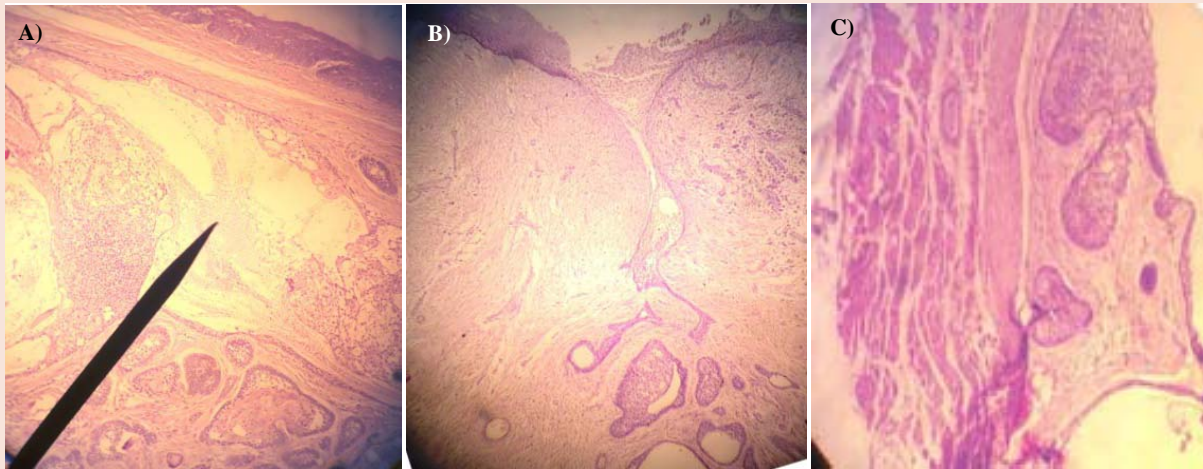


Figure 5: The mass covered superficially by oral epithelium (A) that connect with underlying odontogenic epithelial islands (B). Sections from the inferior border showed a continuous fibrous wall separates the mass from surrounding tissue (C) (Original magnification $\times 100$).

Furthermore, in a recent genetic study, researchers strongly revealed signals for part of odontogenic ameloblast-associated protein in salivary gland-derived RNA [17]. Thus more studies are needed to evaluate the immune profile of these mucous cells of odontogenic source.

There are three proposed theories explaining the transition of odontogenic epithelium from the usually non-mucous cells to mucin-producing cells. They include odontogenic metaplasia, grafting mucous cells from nasal cavity and maxillary sinus, and embryological epithelium residues [16]. The concept of transition due to inflammatory stimuli is rejected since the fibrous connective tissue in AB devoid from inflammatory infiltrate. In this study, the mandibular lesion will negate the possibility of grafting theory. Evidence emphasizes the pluripotential character of the odontogenic epithelium [6]. Almost all types of metaplastic changes reported in AB were localized to the inner cells (the central stellate reticulum-like cells) which is believed to be a candidate cancer stem-like cells [18]. They can differentiate to several legend related to the epithelium. While the peripheral cells were immature ameloblast-like cells and did not undergo differentiation to the point of hard structure formation, they do not show metaplasia. Still the exact pathological basis how cells change their phenotype is poorly understood [18,19].

The numerous histologic patterns of AB believed to have no clinical relevance. Nevertheless, metastases usually follow multiple recurrences, unicystic ameloblastomas may behave less aggressively than multilocular lesions. Desmoplastic ameloblastoma and clear cell ameloblastoma are considered to be more aggressive [1]. In recent years, many researchers published and reviewed the immune profile and genotyping of different variants of AB [20–23]. Additional work will be necessary to identify that one specific for the mucous ameloblastoma in order to determine its biological behavior and predicate outcome. The prediction of the prognosis of ameloblastoma with mucous cell differentiation is not established as only few cases have been published in the literature. Nevertheless, Yoon et al. [6] expected that its prognosis is similar to unicystic ameloblastoma. Till

date, only 9 cases of mucous AB have been reported. Here we add a new case with interesting finding hoping providing more clinical and possibly in the future molecular information to improve our understanding and management of such hybrid lesion.

Conclusion

More accumulative knowledge gained from adding a new case of mucous ameloblastoma. Based on the observations reported in this case, it occurred in elder patient with longer disease duration. It contained a large amount of mucous secretion within the growth and surrounded by thin fibrous capsule. This case highlight the rare type of ameloblastoma.

References

1. Angadi P (2011) Head and Neck: Odontogenic tumor: Ameloblastoma. *Atlas Genet Cytogenet Oncol Haematol* 15: 223-229.
2. Neville BW, Damm DD, Allen CM BJ (2002) *Oral & Maxillofacial Pathology*, 2nd edition. W. B. Saunders, Philadelphia 2002: 610-619.
3. Philipsen HP, Reichart PA (2006) Classification of odontogenic tumours. A historical review. *J Oral Pathol Med* 35: 525-529.
4. Hisatomi M, Asaumi J, Konouchi H, Yanagi Y, Kishi K (2000) A case of glandular odontogenic cyst associated with ameloblastoma: Correlation of diagnostic imaging with histopathological features. *Dentomaxillofacial Radiol* 29: 249-253.
5. Tamgadge S, Tamgadge A, Bhalerao S, Pereira T (2012) Case report mucous cell differentiation in desmoplastic ameloblastoma: unique presentation in posterior mandible. *Int J Oral Maxillofac Pathol* 3: 61-64.
6. Yoon JH, Ahn SG, Kim SG (2009) Mucous cell differentiation in a unicystic ameloblastoma. *Int J Oral Maxillofac Surg* 38: 95-97.
7. Punnya AV, Rekha K (2008) "Ameloblastoma with mucous cells": review of literature and presentation of 2 cases. *Oral Surg Oral Med Oral Pathol Oral Radiol Endod* 106: e20-6.
8. Wilson D, Walker M, Aurora N, Moore S (2001) Ameloblastoma with mucous cell differentiation. *Oral Surg Oral Med Oral Pathol Oral Radiol Endod* 91: 576-578.

9. Takata T, Miyauchi M, Ito H (1999) Clinical and histopathological analyses of desmoplastic ameloblastoma. *Pathol Res Pract* 195: 669-675.
10. Raubenheimer EJ, van Heerden WF, Noffke CE (1995) Infrequent clinicopathological findings in 108 ameloblastomas. *J Oral Pathol Med* 24: 227-232.
11. Van Wyk CW, Thompson IO, Wyma G (1986) A Unicystic Ameloblastoma Mimicking a "Globulo-Maxillary" Cyst: A Case Report. *British J Oral Maxillofac Surg* 24: 422-425.
12. Hartenian KM, Kalfayan B (1976) Ameloblastoma Containing Mucus Glands. *Oral Surg Oral Med Oral Pathol* 41: 508-516.
13. Soundarya N, Sharada P, Nilima Prakash, Pradeep GL VJ (2010) Vacuolated cells and mucous metaplasia in the epithelial lining of radicular and residual cysts. *Int J Contemp Dent* 1: 110-115.
14. Takeda Y, Oikawa Y, Furuya I, Satoh M, Yamamoto H (2005) Mucous and ciliated cell metaplasia in epithelial linings of odontogenic inflammatory and developmental cysts. *J Oral Sci* 47: 77-81.
15. Radhika M, Thambiah LJ, Paremala K, Sudhakara M (2011) Clear cell unicystic ameloblastoma. *J Oral Maxillofac Pathol* 15: 109-112.
16. Carim R, Mahomed F (2013) A Comparative Histochemical Study of Mucous Cells in Odontogenic Cysts. *ISRN Pathol* 2013: 1-4.
17. Kestler DP, Foster JS, Macy SD, Murphy CL, Weiss DT, et al. (2008) Expression of odontogenic ameloblast-associated protein (ODAM) in dental and other epithelial neoplasms. *Mol Med* 14: 318-326.
18. Sathi GA, Tamamura R, Tsujigiwa H, Katase N, Lefeuvre M, et al. (2013) Analysis of immunoeexpression of common cancer stem cell markers in ameloblastoma. *Exp Ther Med* 3: 397-402.
19. Tosh D, Slack JMW (2002) How cells change their phenotype. *Nat Rev Mol Cell Biol* 3: 187-94.
20. Kato H1, Ota Y, Sasaki M, Karakida K, Kaneko A, et al. (2012) Peripheral ameloblastoma of the lower molar gingiva: a case report and immunohistochemical study. *Tokai J Exp Clin Med* 37: 30-34.
21. Premalatha BR, Patil S, Rao RS, P NR, Indu M (2013) Odontogenic Tumor Markers - An Overview. *J Int Oral Health* 5: 59-69.
22. Lee SK, Kim YS (2013) Current concepts and occurrence of epithelial odontogenic tumors: I. Ameloblastoma and adenomatoid odontogenic tumor. *Korean J Pathol* 47: 191-202.
23. Yoon HJ1, Jo BC, Shin WJ, Cho YA, Lee JI, et al. (2011) Comparative immunohistochemical study of ameloblastoma and ameloblastic carcinoma. *Oral Surgery Oral Med Oral Pathol Oral Radiol Endodontology* 112: 767-776.

Copyright: ©2015 Gataa IS, et al. This is an open-access article distributed under the terms of the Creative Commons Attribution License, which permits unrestricted use, distribution, and reproduction in any medium, provided the original author and source are credited.

Citation: Gataa IS, Garib BT, Rashid NH (2015) New Features in Mucous-Ameloblastoma. A Case Report of rare Entity. *Int J Oral Craniofac Sci* 1(1): 001-005. DOI: 10.17352/2455-4634.000001