

Hanane Atarguine^{1*}, Soundous Benmoussa², Fayçal Abbad³, Ouafa Hocar¹, Fatima Ihibbane², Hanane Rais³, Noura Tassi², Nadia Akhdari¹ and Said Amal¹

¹Department of Dermatology, Hospital Arrazi, CHU Mohamed VI, Marrakech, Maroco

²Department of Infectious Diseases, Hospital Arrazi, CHU Mohamed VI, Marrakech, Maroco

³Department of Pathological Anatomy and Cytology, CHU Mohamed VI, Marrakech, Maroco

Dates: Received: 21 January, 2016; Accepted: 08 February, 2016; Published: 10 February, 2016

*Corresponding author: Dr. Hanane Atarguine, Department of Dermatology, Hospital Arrazi, CHU Mohamed VI, 40000 Marrakech, Maroco, Tel: +212672691777; E-mail: hananeatarguine@hotmail.fr

www.peertechz.com

ISSN: 2455-4634

Keywords: Kaposi's sarcoma; Oral; Acquired immunodeficiency syndrome; HIV

Case Report

Acquired Immunodeficiency Syndrome Revealed by Oral Kaposi's Sarcoma

Abstract

Kaposi's sarcoma is the malignant proliferation of the endothelial cell vessels. It is a systemic, malignant and multifactor disease. It usually presents initially as violaceous cutaneous lesions. Outside of a known context of an immune deficiency, an isolated oral lesions may not think to Kaposi's sarcoma. Hence the interest of the histological and immunohistochemical study.

This paper reviews one such case of Kaposi's sarcoma in a 42-year-old woman who present an isolated pigmented lesions of the tongue, related to Kaposi's sarcoma, without cutaneous or visceral involvement, and which led to the discovery of acquired immunodeficiency syndrome (HIV). The stabilization was obtained with antiretroviral triple therapy.

Introduction

Kaposi's Sarcoma (KS), being first described in 1872 [1], is an unusual vascular neoplasm that most likely arises from endothelial cells, with some evidence of lymphatic origin. Different clinical and epidemiological variants have been identified. Lesions of KS typically manifests as bluish-purple macules and plaques on the skin, particularly of the face and lower extremities. Oral mucosa, lymph nodes and visceral organs may be affected, sometimes without cutaneous involvement.

Here, we report the case of a 42-year-old female, having pigmented macules of the tongue, without other sites, revealing Kaposi's sarcoma an acquired immunodeficiency syndrome with good response to antiretroviral triple therapy.

Case Report

A 42-year-old married woman, without specific medical history, was referred to our service for the evaluation of a pigmented lesion of the tongue, painless, non-pruritic and without changing of the taste that had appeared 20 days earlier. In the course of disease, she had a fever, diarrhea and weight loss.

Oral examination shows a confluent brownish macules bunched at the tongue, without other associated lesions of the oral cavity (Figure 1). No other similar lesions in any other region of the body were detected. Lymphadenopathy was not detected and physical examination showed no abnormalities.

An incisional biopsy was performed and the specimen was submitted for the histopathological examination which revealed a tumor proliferation in contact with the dermal vessels. It is made of a fusiform cell population and of small vascular structures dissecting the dermis. Vascular lights are lined by a monomorphic endothelial cells

seat of a moderate cytonuclear atypia. The interstitial tissue is fibrous and seat of deposits of hemosiderin and red cell. The spindle cells show a moderate cytonuclear atypia of neutrophils (Figure 2A,2B). Immunohistochemistry showed an intense cytoplasmic expression of endothelial and spindle cells of the anti-CD34 antibody (Figure 3), also a cytoplasmic membrane and focal expression of spindle cells of the anti- D2-40 antibody (Figure 4).

HIV serology (ELISA and Western Blot) was positive. TCD4 cells were 146/ mm³. Syphilitic serology (TPHA, VDRL) was positive, and serology of hepatitis B and C were negative. Hemogram and biochemical tests were unremarkable. Complete work-up (including chest radiography and ultrasonography of the abdomen) disclosed no signs of visceral involvement of KS. The patient was classified as a good risk according to the staging classification system for AIDS-related KS proposed by the AIDS Clinical Trial Group [2]. The oncologist suggested the antiretroviral treatment in order to allow Immune restoration, and to control the progression of KS. The patient was treated with antiretroviral triple therapy and 2,4 million units benzathine penicillin G (Once weekly for 3 weeks).

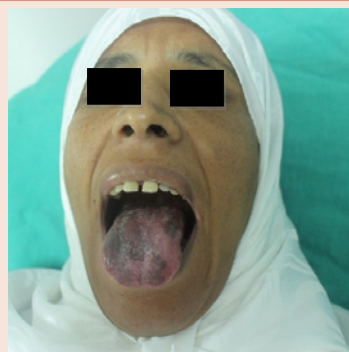

Figure 1: Confluent brownish macules bunched at the tongue without other associated lesions of the oral cavity.

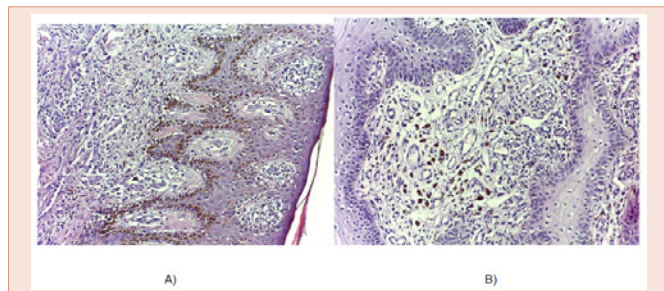


Figure 2: Normal acanthotic epidermis surmounted by an orthokeratose. Dermal proliferation made of spindle cells and vascular cells (A, Hematoxylin-eosin, original magnification x 20). Significant dermal proliferation made of vascular structures of which the lights are lined by a monomorphic endothelial cells seat of a moderate cytonuclear atypia (B, Hematoxylin-eosin, original magnification x 60).

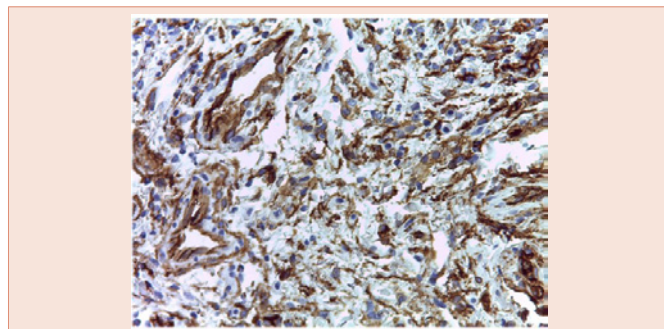


Figure 3: An intense cytoplasmic expression of endothelial and spindle cells of the anti-CD34 antibody (Immunohistochemistry).

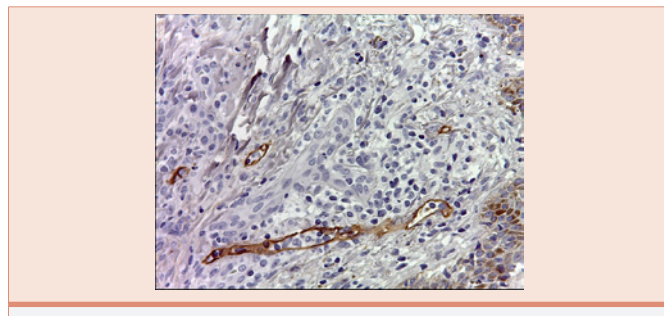


Figure 4: Cytoplasmic and focal expression of spindle cells of the anti- D2-40 antibody (Immunohistochemistry).

The outcome was favorable with recovery of the weight, regression of fever and diarrhea without major side effects. Three months after the beginning of treatment, oral lesions are in slow regression, without the appearance of other sites.

Discussion

Kaposi's sarcoma (KS) is a vascular neoplasm, it can be classified into four distinct forms: classic, endemic, iatrogenic and AIDS-associated [3,4]. The mere presence of KS lesions in HIV-seropositive subjects constitutes a diagnostic sign for AIDS. The etiology of the

disease is unknown, but the condition is considered by most workers to be neoplastic in nature; while other theories have proposed KS representing reticuloendothelial hyperplasia. Current evidence suggests that KS is caused by human herpes virus 8 (HHV-8). The course of the disease is strongly influenced by the immune status of the patient. Lesions of KS typically manifests as bluish-purple macules and plaques on the skin, particularly of the face and lower extremities. Any mucosal site may be involved; the hard palate, gingiva and tongue are affected most frequently [5]. An Isolated Kaposi Sarcoma of the Tonsil has been reported in the literature [6]. Of significance is that, oral lesion may be the initial site of involvement or the only site or the first indication of HIV infection as evidenced by our case how is unique as the patient had oral KS, without the evidence of any cutaneous involvement.

A biopsy is, therefore, necessary to ascertain an accurate diagnosis, and the Immunohistochemical staining may be done for CD34 antibody. It yields positive results for endothelial lining of slit like spaces and for spindle cells [7].

The prognosis is variable depending upon the form of the disease and the patient's immune status.

In the majority of subjects who are HIV-seropositive with KS, effective antiretroviral treatment decreases the incidence and the prevalence of KS and causes regression of established lesions [8].

Conclusion

Certain clinical situations not immediately orienting towards the diagnosis of Kaposi's sarcoma, such as the appearance of a simple modification of the color of a mucosa in an unknown immunosuppression context.

References

1. Kaposi M (1872) Idiopantisches multiples Pigmentsarkom der Haut. Arch DermVatol Syph 4: 265-273.
2. Krown SE, Metroka C, Wentz JC (1989) Kaposi's sarcoma in the acquired immune deficiency syndrome: A proposal for uniform evaluation, response, and staging criteria. AIDS Clinical Trials Group Oncology Committee. J Clin Oncol 7: 1201-1207.
3. Mukai MM, Chaves T, Caldas L, Neto JF, Santamaria JR (2009) Primary Kaposi's sarcoma of the penis. An Bras Dermatol 84: 524-526.
4. Borkovic SP, Schwartz RA (1982) Kaposi's sarcoma. Am Fam Physician 26: 133-137.
5. Neville BW, Damm DD, Allen CM, Bouquot JE (2002) Oral & Maxillofacial Pathology. 2 nd ed. Philadelphia: Saunders.
6. Pittore B, Pelagatti CL, Deiana F, Ortu F, Maricosu E, et al. (2015) Isolated kaposi sarcoma of the tonsil: a case report and review of the scientific literature. Case Rep Otolaryngol 2015: 874548.
7. Lin G, Wang H, Fan X, Li H, Wang Z, et al. (2015) Disseminated Kaposi sarcoma in a HIV negative patient. Int J Clin Exp Pathol 8: 80-3378.
8. Arul AS, Kumar AR, Verma S, Arul AS (2015) Oral Kaposi's sarcoma: Sole presentation in HIV seropositive patient. J Nat Sci Biol Med 6: 459-461.

Copyright: © 2016 Atarguine H, et al. This is an open-access article distributed under the terms of the Creative Commons Attribution License, which permits unrestricted use, distribution, and reproduction in any medium, provided the original author and source are credited.

Citation: Atarguine H, Benmoussa S, Abbad F, Hocar O, Ihibbane F, et al. (2016) Acquired Immunodeficiency Syndrome Revealed by Oral Kaposi's Sarcoma. Int J Oral Craniofac Sci 2(1): 001-002. DOI: 10.17352/2455-4634.000010