

Elizabeth Dacey¹, O John Ma² and Peter Stenzel^{1*}

¹Department of Pathology and Laboratory Medicine, Oregon Health and Science University, Portland Oregon, USA

²Department of Emergency Medicine, Oregon Health and Science University, Portland Oregon, USA

Dates: Received: 24 June, 2016; Accepted: 24 June, 2016; Published: 25 August, 2016

***Corresponding author:** Peter Stenzel, MD, PhD, Department of Pathology, Oregon Health and Science University, Portland, Oregon, United States of America; 3181 SW Sam Jackson, Portland, Oregon, USA, Tel: 1-503-494-2310; Fax: 1-503-494-2025; E-mail: stenzelp@ohsu.edu

www.peertechz.com

ISSN: 2455-1759

Case Report

Papillary Laryngeal Carcinoma Presenting as Laryngeal Obstruction and Fatal Intractable Hypoxemia

Introduction

Unexpected acute laryngeal obstruction is most often caused by foreign bodies or edema and rarely by cysts, infection, or neoplasia. Neoplastic cases include soft tissue tumors and benign epithelial tumors. We report a case of fatal, unexpected, sudden asphyxia due to laryngeal obstruction by a papillary squamous cell carcinoma, a unique presentation of laryngeal squamous cell carcinoma and in this case an unusual histologic pattern. A 61-year-old man experienced respiratory distress while at work. Laryngeal obstruction was discovered in the emergency department. Cricothyrotomy was performed, but his blood oxygen saturation levels failed to improve and he died after a prolonged resuscitation. Autopsy revealed a papillary squamous cell carcinoma on the inferior aspect of the right vocal fold. We suggest that this unusual presentation of laryngeal carcinoma may be due to the unusual histologic features of the tumor.

Case

A 61 year-old man was emergently transported to the emergency department with extreme respiratory distress and a decreased level of alertness. His oxygen saturations were in the 60s and only improved to the 80s with CPAP. He had been complaining of worsening shortness of breath all day at work and was found tripodding when EMS personnel arrived. Upon admission to the emergency department, the patient was unable to provide any history due to his altered mental status. Additionally, there was no medical history on file for this patient.

The patient's initial vital signs showed a temperature of 36.9°C, pulse 148, respirations 33, and oxygen saturation of 92% on 100% oxygen. On physical exam, the patient was in extreme respiratory distress and unable to speak. His neck was supple with no jugular vein distention and his trachea was midline. There were diminished breath sounds, inspiratory and expiratory wheezes, and poor aeration bilaterally. He was tachycardic with palpable pulses and his skin was notable for peripheral mottling throughout. He had a Glasgow Coma Scale score of 9. An electrocardiogram did not reveal any ST

segment changes. Because there was concern that the patient could not protect his airway and his oxygen saturations were dropping despite supplemental oxygen, the decision was made to secure his airway and place him on mechanical ventilation. Two endotracheal intubation attempts were made. Both attempts were unsuccessful due to the presence of a sizable, undifferentiated laryngeal mass and swollen larynx. No foreign body was present. A cricothyrotomy was then performed. Despite these interventions, the patient's saturations continued to plummet, he went into cardiac arrest, and a prolonged resuscitation attempt was ultimately unsuccessful. Epinephrine was not utilized initially because the patient had no history of laryngeal cancer and the obstructing tumor and associated edema were not evident until direct laryngoscopy during the intubation attempt.

On autopsy, external examination was notable only for mild clubbing of the digits. The internal exam revealed a right papillary mass measuring 1.2 x 1.5 cm on the inferior aspect of the right vocal fold (Figure 1). No foreign body was present. The lungs were severely emphysematous and weighed 1458 grams (left) and 1513 grams (right); normal weight for each lung is approximately 500 grams. Moderate to severe atherosclerosis of the aorta and left anterior descending coronary artery as well as left ventricular scarring were present. In addition, right ventricular hypertrophy and pulmonary artery atherosclerosis were found. Microscopy of the laryngeal mass showed a well-differentiated squamous cell carcinoma with finger-like projections containing fibrovascular cores (Figure 1). The lesion also exhibited hyperkeratosis, reactive inflammation, necrosis, and invasion into skeletal muscle. These characteristics led to a diagnosis of invasive papillary squamous cell carcinoma of the larynx. A complete autopsy revealed no other site of malignancy.

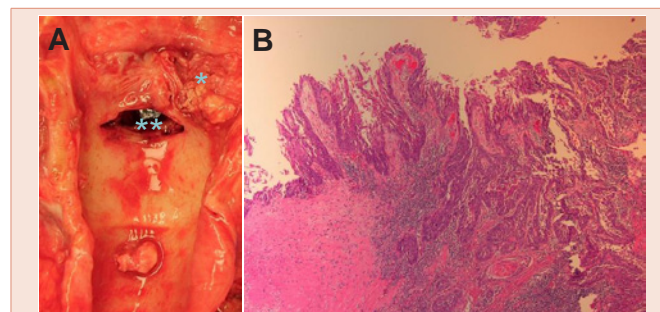


Figure 1: (A) Larynx (opened posteriorly) at autopsy showing tumor (*) and cricothyrotomy (**); (B) Photomicrograph of papillary squamous cell carcinoma.

Significant findings at autopsy were a laryngeal tumor, pulmonary edema, severe pulmonary emphysema, coronary atherosclerosis with myocardial scar formation, and right ventricular hypertrophy with pulmonary artery atherosclerosis. These findings were consistent with a fatal chain of events beginning with laryngeal obstruction, and pulmonary edema that persisted after cricothyrotomy in the setting of significantly compromised cardiorespiratory reserve due to severe pulmonary emphysema, chronic myocardial ischemia, and chronic pulmonary hypertension.

Discussion

The usual causes of acute laryngeal obstruction are foreign bodies, anesthesia and other states of unconsciousness, intubation injury, angioneurotic edema, burn injury, laryngeal or tracheal trauma, and various infections [1]. Glottic squamous cell carcinoma in most cases presents as dysphonia; stridor and dyspnea may ensue as airflow restriction develops [2]. There are rare case reports of unexpected, fatal laryngeal obstruction caused by laryngeal neoplasia. Such a case in a 3-month-old child was caused by a solitary pedunculated laryngeal papilloma composed of areolar tissue and mucus glands [3]. Applying a search in PubMed we found no case of laryngeal carcinoma presenting as acute asphyxiating laryngeal obstruction.

In this case the obstruction by the tumor needs some explanation in that the tumor was not pedunculated, massive, or circumferential. The histologic pattern of the carcinoma in this case is seen in only a small fraction of laryngeal squamous cell carcinomas and is peculiar because of its papillary projections covered by hyperkeratotic malignant epithelium [4]. Laryngospasm often contributes to laryngeal obstruction. The causes for laryngospasm include mucosal irritation followed by reflex closure of the larynx by a ball valve

mechanism [5]. Thus, it is possible that the surface of the tumor in this case was particularly irritating and produced laryngospasm. The obstruction was relieved via cricothyrotomy, but the patient's profound hypoxemia persisted, most probably due to severe pulmonary edema in evidence at autopsy by the weights of the lungs. Pulmonary edema is a known complication of laryngeal obstruction and occurs especially in post intubation laryngospasm, and also in cases of laryngeal mass lesions and trauma [6]. The mechanism likely involves prolonged negative intrathoracic pressure and exudation of fluid into distal airspaces. Under other circumstances this case may have been treatable, but the presentation with laryngeal obstruction and complications in a severely compromised patient precluded successful intervention.

References

1. Balkissoon RC, Baroody FM, Togias A (2005) Disorders of the upper airways. In Mason RJ, Broaddus VC, Murray JF, et al. (eds): Murray and Nadel's Textbook of Respiratory Medicine 4th edition. Philadelphia, PA, Elsevier Saunders, 1277-1294.
2. Armstrong WB, Vokes DE, Maisel RH (2010) Malignant tumors of the larynx. In Flint PW, Haughey BH, Lund VJ, et al. (eds): Cummings Otolaryngology Head & Neck Surgery 5th edition. Philadelphia, PA, 2010. Mosby Elsevier, 1490-1505.
3. Schaab K, Verdile VP (1994) Solitary papilloma of the larynx as the precipitant of sudden death. Am J Emerg Med 12: 605-607.
4. Thompson LDR, Wenig BM, Heffner DK, Gnepp DR (1999) Exophytic and papillary squamous cell carcinomas of the larynx: a clinicopathologic series of 104 cases. Otolaryngol Head Neck Surg 120: 718-724.
5. Fink BR (1956) The etiology and treatment of laryngeal spasm. Anesthesiology 17: 569-577.
6. Willms D, Shure D (1988) Pulmonary edema due to upper airway obstruction in adults. Chest 94: 1090-1092.

Copyright: © 2016 Dacey E, et al. This is an open-access article distributed under the terms of the Creative Commons Attribution License, which permits unrestricted use, distribution, and reproduction in any medium, provided the original author and source are credited.

Citation: Dacey E, John Ma O, Stenzel P (2016) Papillary Laryngeal Carcinoma Presenting as Laryngeal Obstruction and Fatal Intractable Hypoxemia. Arch Otolaryngol Rhinol 2(1): 051-052. DOI: 10.17352/2455-1759.000024