

Assunta Scuotto\* and Michele Rotondo

Neuroradiology, Department of Neuroscience,  
Second University of Naples; CTO Hospital, Viale  
Colli Aminei, 21, 80131 Naples, Italy

**Dates:** Received: 24 June, 2016; Accepted: 24  
August, 2016; Published: 26 August, 2016

\*Corresponding author: Assunta Scuotto, MD,  
Aggregate Professor, Neuroradiology, Department  
of Neuroscience, Second University of Naples, CTO  
Hospital, Viale Colli Aminei, 21, 80131, Naples, Italy,  
Tel: 39 0812545575; Fax: 39 0817414288; E-mail:  
assunta.scuotto@unina2.it

[www.peertechz.com](http://www.peertechz.com)

ISSN: 2455-1759

**Keywords:** Temporal bone trauma; Computed tomog-  
raphy; Magnetic resonance Imaging

## Short Communication

# Temporal Bone Trauma: To Pull Down the Wall of Incommunicableness

### Abstract

In the past decades, treatment of the temporal bone traumas (TBTs) was undeniably improved by advances in neuroradiological and in neuro-oto-surgical fields. However, these advances did not systematically enhance the quality of the approach to TBTs. Maybe they did not systematically target towards treatment- guidelines standardization. We suggest a simplified approach to TBTs, trying to enhance the communication among the different specialists involved in the matter, above all between the radiologists and not-radiologists.

## Introduction

The recent availability of efficient neuroimaging procedures, i. e. multidetector Computed Tomography (CT) and Magnetic Resonance (MR), provided a crucial support to the treatment of TBTs both in the acute and chronic stage.

Sometimes, classification of temporal bone fractures in general categories became the core of radiographic interpretation, undervaluing substantial clinical implications and forgetting crucial interactions with non-radiologists. Although fractures categorization is needed i.e. to predict trauma-associated complications (hearing loss, vestibular dysfunction ,facial nerve weakness, cerebrospinal fluid leakage, vascular injuries) , the identification of injury to significant structures is more important for guiding management and determining prognosis [1].

## Clinical scene and practical vademecum

Temporal bone (TB) anatomy is complex and rich in relationships with critical structures - cranial nerves (V to XI) - vascular elements (sigmoid sinus- internal jugular vein, internal carotid artery)-ear components (conductive and sensorineural compartment), Middle and Posterior Cranial Fossae. Therefore TBTs can produce injuries to local, regional, and intracranial structures. This distinctive feature strongly affects the neurological picture when a trauma occurs. At this regard, the TBTs might be considered as head traumas, thus requiring the same accurate imaging, sometimes even in the acute phase without neglecting the urgent need to evaluate the brain.

Generally speaking, CT plays a fundamental role in the initial evaluation of patients with polytrauma recognizing significant structural injuries that may have devastating complications, and helping to determine the priority of treatment when concomitant diseases exist.

MR examination can be supplementary required to better investigate CT findings and/or to look for possible lesions missing on CT.

When head trauma occurs, neuroradiological procedures preliminarily consist of emergency brain CT. In our opinion, head CT

examination should routinely include additional thin scans dedicated to temporal bone at least:

-when a petro-mastoid fracture is detected on routine head CT

It is useful to remind ourselves that approximately 30% of head trauma patients receive skull fractures and approximately 18% of all skull fractures involve TB [2].

-when there is clinical suspicion of TB involvement (i.e. otorrhagia, relevant cranial nerve dysfunction, haematoma in mastoid region).

This demeanor should allow a prompt governance of loco-regional complications as impairment of facial nerve (FN), that is the cranial nerve most often injured during head trauma . At this regard, TB CT scan is indicated in all cases of immediate onset of FN palsy to assess the relationship between the fracture line and the bony facial nerve canal, thus suggesting the indication for early surgical intervention. MR is required for cases of FN paralysis unexplained by CT findings because of its sensitivity in demonstrating the facial nerve itself and possible pathologic changes [3], (Figures 1,2).

Alternatively, brain CT valuation is mandatory still when trauma is confined to the petro-mastoid region in order to identify potential concurrent intracranial injuries, particularly frequent in the presence of temporal squama -mastoid injury.

## Conclusive proposal

To enhance treatment quality, TBTs radiographic features should be depicted according to the involvement of all temporal bone components and its potential clinical implications, as recently stressed in the literature [4,5].

The traditional classification of TB fractures into longitudinal , transverse , and mixed type- according to their orientation with respect to the long axis of the petrous pyramid- does not effectively consider all the anatomical elements involved and does not adequately contemplate the clinical relevance [6,7]. Moreover, the conventionally described relationships between the fracture orientation and the possible complications ( i.e. facial nerve injury, hearing Loss , cerebrospinal fluid leakage) are no longer thought to be convincing . To emphasize the structures impaired rather

than simply the orientation, alternative categorizations have been proposed. One among most compelling system considers whether the otic capsule structures have been violated or spared. Otic capsule violating fractures have been reported to have a higher incidence of loco-regional complications [4,8].

Some Authors found that the otic capsule-based classification system was not significantly better than the traditional system in predicting the likelihood of sustaining specific injuries from TB fractures [6]. Our experience is in agreement with this conclusion; it concerns 29 patients (19 males and 10 females with a mean age of 37 years) with TB fractures (transverse in 7 cases, longitudinal in 6 cases, mixed in 16 cases; alternatively otic capsule violating in 3 cases, otic capsule sparing in 23 cases), identified in a group of 312 patients with a radiological diagnosis of a skull-base fracture over a 5-year period.

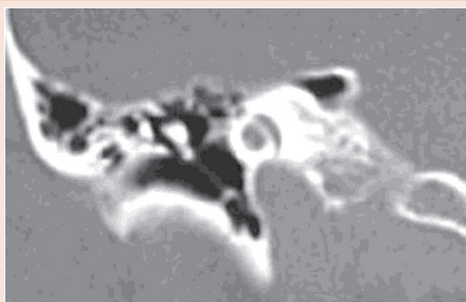
Neglecting the setting of conflicting reports, in our opinion rather than running after a satisfactory classification of TBTs, it would be more fitting to create a conjunction ring between “the image and the action”. A simplified account, that focuses on the fine anatomic location of TB fractures, alerts to both otological and intracranial potential sequelae, and otherwise is addressed to explain clinical features, could connect the different points of view in order to optimize the diagnostic and therapeutic chances.

From this standpoint one could resort to a “look at and look for” guide towards TBTs management (Table 1).

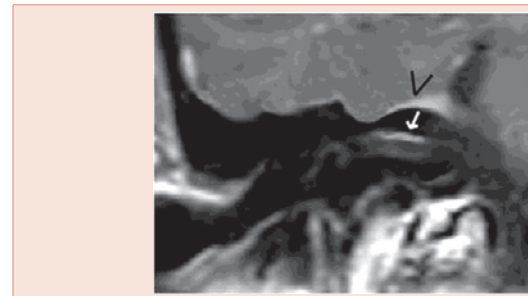We achieved some success and patients’ benefit with this “easy” approach.

In compliance with this proposal, imaging evaluation of the temporal bone should be an integral part of the diagnostic iter i.e. by the addition of thin dedicated CT images both in early and in late stage if needed. In fact, CT represents the best imaging modality to assess TB trauma offering key-diagnostic information promptly, and helping to select the suitable treatment accordingly. MR could be additionally required to better investigated brain and /or nerves lesions, internal ear injury thanks to special dedicated sequences.

In proposing our experience, that we know is relatively small and statistically not too efficient, we motivated by a desire to improve care for patients with TBTs encouraging interdisciplinary cooperation and avoiding a *dialogue of the deaf*.



**Figure 1:** 27 year-old man with gradual onset of left -sided facial weakness five days after accidental blunt head trauma. High-resolution TB coronal CT scan at the level of the labyrinthine segment of the FN: no bone fracture.



**Figure 1:** The same patient. Contrast-enhanced coronal T1-weighted magnetic resonance image shows subtle impregnation of the distal labyrinthine facial nerve section (white arrow) along with a linear dural enhancement (arrowheads). These findings were consistent with temporal bone microfracture and dural microlaceration, missed on CT scan.

**Table 1:** “look at and look for” guide towards TBTs management.

LOOK AT impairment of	LOOK FOR potential presence of
Squama	Intracranial damage (epi-subdural haematoma, subarachnoid haemorrhage, brain contusion...) <i>neurological deficit</i>
Mastoid	III facial nerve segment injury <i>facial weakness</i>
External Auditory Canal	Temporo- mandibular joint impairment, haemorrhage <i>mastication dysfunction, conductive hearing loss</i>
Tympanic cavum	ossicular chain disruption ,haemotympanum <i>conductive hearing loss</i>
Tegmen	Cerebrospinal fluid fistula and potential encephalo-meningocele <i>rhino-otoliquorrea, meningitis, neurological deficit...</i>
*This format should fall into the category of longitudinal fracture and/ or of sparing otic capsule fracture	
Internal Auditory Canal	Cochleo-vestibular and facial nerve injury (first and ganglionic segment,: high incidence!),) <i>facial weakness, sensorineural hearing loss, vertigo</i>
Cochlea	Cochlear nerve damage, <i>sensorineural hearing loss</i>
Posterior labyrinth	Vestibular and facial nerve (II segment: high incidence!) damage, perilymphatic fistula. <i>facial weakness, dizziness, fluctuating sensorineural hearing loss</i>
**This format could fall into the category of transverse fracture and/ or as of violating otic capsule fracture.	

Anyway I, neuroradiologist, and Professor Rotondo, neurosurgeon, are still now good friends

## References

- Barreau X (2011) Imaging features of temporal bone fractures. J Radiol 92: 958-966.
- Cvorovic L, Jovanovic M , Markovic M, Milutinovic Z, Strbac M (2012) Management of complication from temporal bone fractures. Eur Arch Otorhinolaryngol 269: 399-403.
- Dahiya R, Keller JD, Litofsky NS, Bankey PE, Bonassar LJ, et al. (1999) Megerian GA Temporal bone fractures: otic capsule sparing versus otic capsule violating clinical and radiographic considerations. J Trauma 47: 1079-1083.
- Ishman SL, Friedland DR (2004) Temporal bone fractures: traditional classification and clinical relevance. Laryngoscope 114: 1734-1741.



5. Little SC, Kesser BW (2006) Radiographic classification of temporal bone fractures. Arch Otolaryngol Head Neck Surg 132:1300-1304.
6. Nosan DK, Benecke JE Jr, Murr AH (1997) Current perspective on temporal bone trauma. Otolaryngol Head Neck Surg 117: 67-71.
7. Rafferty MA, Mc Conn Walsh R, Walsh MA (2006) A comparison of temporal bone fracture classification systems. Clin Otolaryngol 31: 287-291.
8. Rotondo M1, D'Avanzo R, Natale M, Conforti R, Pascale M, et al. (2010) Post-traumatic peripheral facial nerve palsy: surgical and neuroradiological consideration in five cases of delayed onset. Acta Neurochir 152: 1705-1709.

**Copyright:** © 2016 Scuotto A, et al. This is an open-access article distributed under the terms of the Creative Commons Attribution License, which permits unrestricted use, distribution, and reproduction in any medium, provided the original author and source are credited.

**Citation:** Scuotto A, Rotondo M (2016) Temporal Bone Trauma: To Pull Down the Wall of Incommunicableness. Arch Otolaryngol Rhinol 2(1): 053-055. DOI: 10.17352/2455-1759.000025