

Nazia Chaudhuri<sup>1\*</sup>, Lisa Spencer<sup>2</sup> and Colm Leonard<sup>1</sup>

<sup>1</sup>North West Interstitial Lung Disease Unit, University Hospital of South Manchester, Wythenshawe Hospital, Southmoor Road, Manchester, UK

<sup>2</sup>Aintree University Hospital NHS Foundation Trust, Longmoor Lane, Liverpool, UK

**Dates:** Received: 17 November, 2015; Accepted: 07 December, 2015; Published: 09 December, 2015

**\*Corresponding author:** Dr. Nazia Chaudhuri, North West Interstitial Lung Disease Unit, University Hospital of South Manchester, Wythenshawe Hospital, Southmoor Road, Wythenshawe, Manchester, United Kingdom, E-mail: Nazia.Chaudhuri@uhsm.nhs.uk

[www.peertechz.com](http://www.peertechz.com)

## Review Article

# A Review of the Multidisciplinary Diagnosis of Interstitial Lung Diseases: A Retrospective Analysis in a Single UK Specialist Centre

### Abstract

A multidisciplinary team approach to diagnosis and management of interstitial lung diseases (ILD) is considered gold standard and an integral part of ILD management and guidelines. The accurate diagnosis and management of individuals with ILDs poses an interesting challenge in clinical practice. This is a single center retrospective review of electronic patient letters and multidisciplinary team (MDT) records spanning a five and half year time period. In this study we assessed the accuracy of prior ILD diagnosis, the methodology used to establish a correct diagnosis and how an MDT approach to diagnosis affected subsequent management.

Our results demonstrate that a multidisciplinary approach to diagnosis within a single specialist ILD center can establish a diagnosis in the majority of cases when prior diagnosis is uncertain (76%). We also show that a prior diagnosis of idiopathic pulmonary fibrosis is deemed inaccurate in over fifty percent of cases after MDT discussion. Other ILD diagnoses fair better with an inaccurate prior diagnosis in a third of cases. Over time we demonstrate an increased utilisation of combined lung biopsy and radiological imaging to establish a diagnosis. However when diagnosis was deemed uncertain on radiological imaging alone, biopsy was seldom possible due to factors such as poor lung function or presence of comorbidities deeming biopsy as too high risk.

Our data supports an MDT approach in an experienced specialised ILD center. We have demonstrated that diagnosis is often changed after an MDT review and that this impacts on subsequent management. We have shown that during diagnostic uncertainty the considered gold standard of proceeding to a lung biopsy is not always feasible due to disease severity and comorbidities. In these circumstances an MDT approach to diagnosis of ILDs combines clinical data with serial lung function and disease behavior, with or without responses to previous treatment trials to establish an accurate expert diagnosis.

## Introduction

Interstitial Lung Diseases (ILD) are a group of over one hundred heterogeneous diseases [1]. The commonest, Idiopathic Pulmonary Fibrosis (IPF), has a median life expectancy of three to five years from diagnosis [2], with a prevalence that is increasing by 5% per year [3,4]. Accurate and early diagnosis is paramount for patient and clinician as it predicts prognosis and allows accurate targeting of the available treatment modalities whether immunosuppression, anti-fibrotic therapies, lung transplantation or involvement in clinical trials.

A multidisciplinary team (MDT) approach to diagnosis and management of ILD improves diagnostic confidence [5], and is now considered gold standard and an integral part of ILD management and guidelines [5-7]. ILD MDTs consisting of expert physicians, radiologists and histopathologists have been shown to minimise interobserver variation and improves diagnostic confidence [8].

We are a large tertiary referral center for ILD cases in the North West of England supporting a population of five million people. We have been performing a multidisciplinary ILD meeting to discuss newly referred clinical cases from the region for almost a decade.

Our clinical database has over 700 patients and in 2014 we saw over 350 new referrals. The development of specialist commissioning for ILD in England, the establishment of dedicated ILD centers and the approval of anti-fibrotic therapies has resulted in this number of new referrals increasing by twenty five percent year on year. Here we present a retrospective review of our MDT reviews, exploring the accuracy of prior ILD diagnosis after a single center MDT discussion of clinical cases, how these diagnosis are achieved and the influence of MDT discussion on subsequent management.

## Methods

This is a single center retrospective review of electronic patient letters and MDT records for a five and half year time period spanning 2005 to 2008 and 2010 to 2013. Data from 2008 through to 2010 was not available as MDT data and patient letters were not available electronically for review. Our MDT consists of two consultant respiratory physicians with a specialist interest and expertise in ILD, performing weekly, dedicated ILD clinics in our centre, a thoracic radiologist with expertise in ILD, a thoracic histopathologist and an ILD specialist nurse. We receive tertiary referrals from local hospitals within the North West of England spanning a population

of five million people. Patients with a prior diagnosis of ILD are referred for expert multidisciplinary review for a variety of reasons including uncertainty of diagnosis, failure to respond to standard therapy, assessment for initiation of second line immunosuppression or anti-fibrotic therapy, consideration for clinical trials and lung transplantation. Between 2005 and 2012 we conducted monthly MDT meetings and due to clinical demand this increased to a weekly meeting from November 2012. All MDT data was collected and recorded on a locally devised ILD MDT proforma that detailed patient demographics, clinical history, diagnosis prior to referral, MDT discussion of imaging and histopathology (if available) and final MDT diagnosis and management plan. This allowed us to analyse a number of key questions:

How often does an MDT review of clinical cases alter the diagnosis of ILD?

How often is this change in diagnosis based on radiographic imaging alone or combined computerised tomography (CT) imaging and biopsy?

How does this change in diagnosis subsequently alter patient management?

Has there been a temporal change in the management of cases in the two time periods?

## Results

A total of 318 clinical cases were discussed in our ILD MDT in this time period ( $n=165$  between 2005-2008 and  $n=153$  between 2010-2013). Seventy five (24%) cases were referred because of an ILD of unknown classification, 107 (33.5%) were referred with a prior diagnosis of IPF and 136 (42.5%) were referred with other ILD diagnoses (non-specific interstitial pneumonitis (NSIP), connective tissue disease related ILD (CTD-ILD), sarcoidosis, hypersensitivity pneumonitis (HP) and other ILDs) (Figure 1). Between 2005 and 2008 the majority of the MDT discussions were based on radiographic imaging alone (91%). This compared to 62% between 2010-2013. There was a 31% increase in MDT discussions involving combined radiology imaging and histopathological biopsy between the two time periods (2005 to 2008 vs 2010 to 2013).

### Specialist ILD MDT discussion of interstitial lung diseases of unknown classification results in a consensus unified diagnosis in 76% of cases with subsequent treatment change in 40% of cases

Seventy five cases were referred to our MDT because the referring physician was unable to classify the type of ILD. Our MDT discussion was able to make a consensus ILD diagnosis in 57/75 (76%) of cases. In 2005 to 2008 the majority of these consensus diagnoses were based on radiological imaging alone (42/44 95%) compared to 16/31 (52%) between 2011-2013. There was a 43% increase in MDT discussions of unclassifiable ILDs involving both radiology and histopathological biopsy between the two time periods (2005 to 2008 vs 2010 to 2013).

Between 2005 and 2008, 42/44 (95%) of diagnoses were based on radiological imaging alone (Figure 2a). Of these, 17 (41%) were deemed to be conclusive on CT imaging. Of the remaining 25 patients,

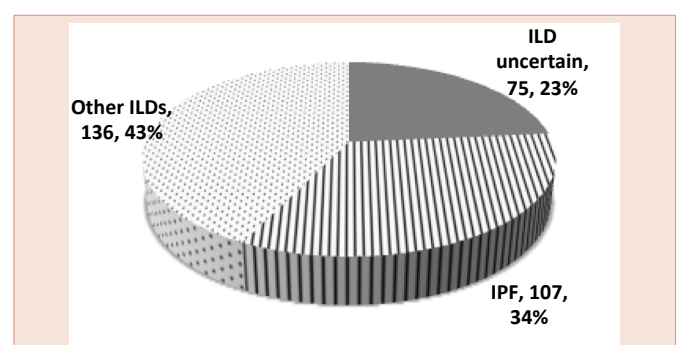
biopsy was not performed because it was deemed too high risk in 16 (38%) patients (average DLCO 35%) and in 9 (21%) patients it was deemed that clinical management would not be altered after a biopsy (Figure 2b). Between 2010 and 2013, 16/31 (52%) of diagnoses were based on radiological imaging alone (Figure 2c). Five (31%) were deemed conclusive on CT imaging alone, six (37%) patients were deemed too high risk to proceed to biopsy, two (13%) patients were asymptomatic or improving and three (19%) patients were referred for surgical biopsy to clarify a diagnosis (Figure 2d).

MDT discussion resulted in a change of treatment in 30 (40%) cases. Thirty one (41%) cases had no treatment change and data regarding treatment alterations was not available in 14 cases.

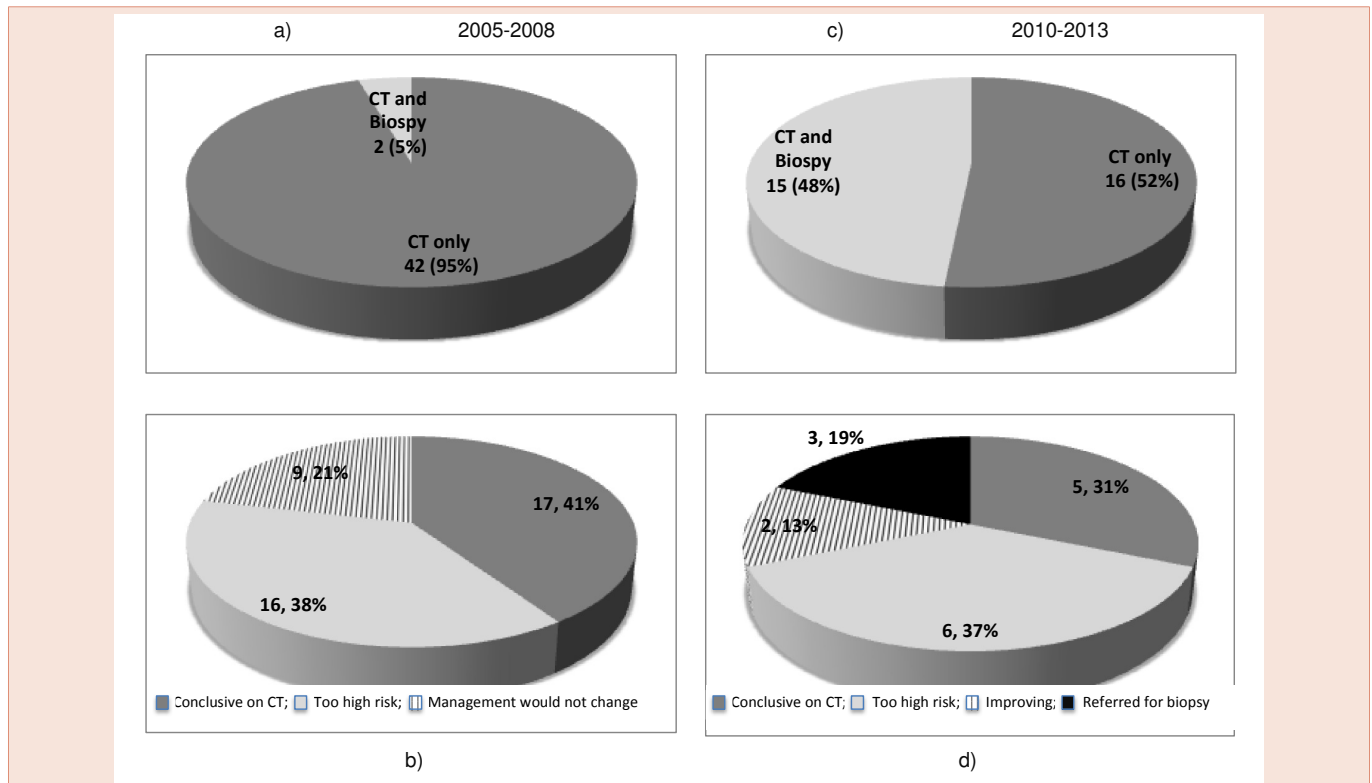
### Specialist ILD MDT discussion reveals that a prior diagnosis of Idiopathic Pulmonary Fibrosis is inaccurate in 53% of cases

107 cases were referred to our specialist ILD service with a prior diagnosis of IPF. After MDT discussion this diagnosis was deemed correct as defined by a definite UIP pattern (5) in 50 (47%) and incorrect in 57 (53%) cases. Between 2005 and 2008, 65/73 (88%) IPF diagnoses were based on CT imaging alone. Between 2010 and 2013 this reduced to 19/33 (58%). There was a 30% increase in MDT discussions involving both radiology and histopathological biopsy between these two time periods (Figure 3).

The commonest alternative diagnosis was that of fibrotic NSIP. In 2005 to 2008, 39 patients were deemed to have an incorrect diagnosis of IPF (Figure 4a). Seven (18%) were confirmed to have fibrotic NSIP on CT imaging and biopsy. In 32 (82%) cases a diagnosis of fibrotic NSIP was based on clinical course and radiological imaging alone. This was because 19 (49%) patients were deemed too high risk for biopsy with an average DLCO of 38.7%. In 13 (33%) patients it was felt that biopsy would not change clinical management (Figure 4b). In 2010 to 2013, 18 patients were deemed to have an incorrect diagnosis of IPF (Figure 4). 5 (28%) had alternative ILD diagnoses and 13 (72%) were diagnosed as fibrotic NSIP based on CT imaging and a more stable clinical course. Of all cases in which the diagnosis was based on CT imaging alone (19/53), 9(47%) were deemed correct on CT, 5(26%) were deemed too high risk to biopsy, 1(5%) patient was referred for a surgical biopsy and data was not available in 4(21%) (Figure 4c).



**Figure 1:** Reasons for referral to the interstitial lung disease multidisciplinary meeting.



**Figure 2:** Multidisciplinary discussion and diagnosis of interstitial lung disease of unknown classification. Which modalities were used to make the diagnosis (Figure 2a and c). If CT alone, why was a biopsy not performed (Figure 2b and d).

MDT discussion resulted in a change of treatment in 53 (50%) cases. Thirty six (34%) cases had no treatment change and data was not available in 18 cases.

### Thirty three percent of prior ILD diagnoses other than IPF are inaccurate when discussed at a specialist ILD MDT

136 patients were referred with other ILD diagnoses. After MDT discussion the diagnosis was correct in 91/136 (67%) of cases and incorrect in 45/136 (33%). Between 2005 and 2008, 44/47 (94%) of diagnoses were based on CT imaging alone. Between 2010 and 2013 this reduced to 64%. There was a 30% increase in discussions involving both radiology and histopathological biopsy between these two time periods.

Between 2010 and 2013, when diagnosis was based on CT imaging alone, consensus diagnosis was achieved in 27 (47%) by CT imaging alone, 6 (11%) patients were referred for surgical biopsy, 7 (12%) were deemed too high risk for biopsy, in 13 (23%) patients biopsy was deemed not to change management, 1(2%) declined biopsy and in 3 cases data was not available.

MDT discussion resulted in a change of treatment in 53 (39%) cases. 63 (46%) cases had no treatment change and data regarding treatment change was not available in 20 cases.

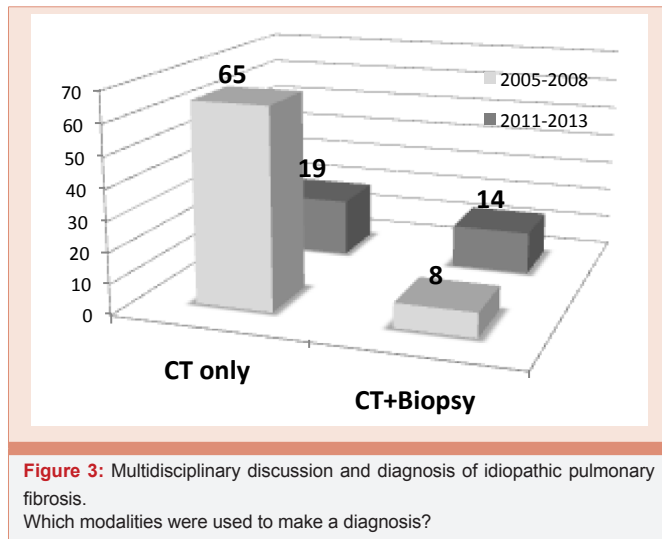
## Discussion

This is a single centre retrospective review of MDT data from a

large teaching university hospital based in the North West of England. As far as we are aware this is the largest published retrospective review of ILD MDT data. We have been conducting monthly MDT meetings discussing referred ILD cases from the North West region and have almost a decade of expertise in managing patients with ILD. Here we present a review spanning five and a half years of available data collection.

Current guidelines for diagnosis and management of ILDs advocate a multidisciplinary team review as gold standard (5-7). The aims are to raise the standard of care for patients with ILDs and optimise diagnosis and management of this group of conditions. Our data supports these recommendations by highlighting an inaccuracy of prior diagnoses based on our revision of ILD diagnoses after a comprehensive MDT review.

Approximately one quarter of cases are referred as ILD of unknown classification. After MDT discussion of cases we can reach a consensus and unified diagnosis in the majority of cases (76%). Over time there has been a paradigm shift and increased utility of combined radiology and histopathological biopsies to achieve this consensus diagnosis (5% vs 48%). We feel this increase is a reflection of the biopsy recommendations in the 2011 ILD guidelines. These guidelines advocate the need for tissue biopsy when there is diagnostic uncertainty [5]. Between the time period of 2005 and 2008, of those requiring biopsy due to diagnostic uncertainty, 64% of patients were deemed too high risk based on their DLCO and



pre-existing comorbidities and in 36% of cases a clinical decision was made that biopsy would not alter the treatment strategies. In the latter time period, although the absolute numbers without biopsy to aid diagnoses were smaller, again a high proportion of cases (55%) were deemed too high risk, 18% [2], patients were improving or asymptomatic clinically and 27% [3], were referred for biopsy. Our MDT discussions highlight an increased utilisation of lung biopsy in diagnosis over the time period, as is advocated in international guidelines when there is diagnostic uncertainty. Despite this increase, the majority of patients are deemed too high risk for lung biopsy, due to the severity of their disease as pertained by their poor lung function, or the presence of co-existing comorbidities. This is reflective on the fact that patients with ILDs tend to present in their later decades.

A third of cases discussed in our ILD MDT had a prior diagnosis of IPF based mainly on CT imaging alone. As discussed previously in line with international guidelines, there has been a shift in time of increased utility of combined CT imaging and histopathological biopsy to achieve a diagnosis (12% vs 42%). Of particular concern, over half the IPF diagnoses are changed after ILD MDT review. The commonest alternative diagnosis was fibrotic NSIP. This is primarily based on a more stable clinical course and the absence of honeycombing on CT imaging. Only 12% were diagnosed with combined CT imaging and histopathological biopsy. 79% of the diagnoses of fibrotic NSIP were based on CT imaging and evidence of stability on serial lung function monitoring. There is a major limitation of this observation as a diagnosis of fibrotic NSIP should only be conclusively made on biopsy and stability in lung function can also be a feature of IPF due to the heterogeneity of its clinical course. Subsequent data from our group on a select cohort of patients diagnosed as fibrotic NSIP has demonstrated that age of patient, decline in lung function over time and failure to respond to immunosuppressive therapies within a MDT discussion are important factors used to make a diagnosis of IPF when biopsy is not feasible [9]. In this cohort, biopsy was not performed because 53% of patients were deemed too high risk based on their DLCO and pre-existing comorbidities and in 29% of cases a clinical decision was made that biopsy would not alter the treatment

strategies. This was primarily driven by the earlier time point when immunosuppressive therapy was considered standard treatment for both IPF and fibrotic NSIP. Only one patient in this cohort was referred for biopsy.

This data highlights the difficulties often posed by the combination of the presence of comorbidities in an older population and the problems posed by delayed diagnosis. Symptoms can be present for many years before diagnosis and thus patients often present with severer disease. These factors impact on the suitability of patients for lung biopsy when diagnostic uncertainty ensues and goes some way to explain the over reliance on CT imaging and low biopsy referrals in these results. This data also represents the era prior to pirfenidone approval when immunosuppression was the only available treatment versus supportive care for both IPF and fibrotic NSIP. Biopsy was principally required to distinguish between IPF and fibrotic NSIP and so often a clinical decision was made that biopsy would not alter management and therefore was not performed.

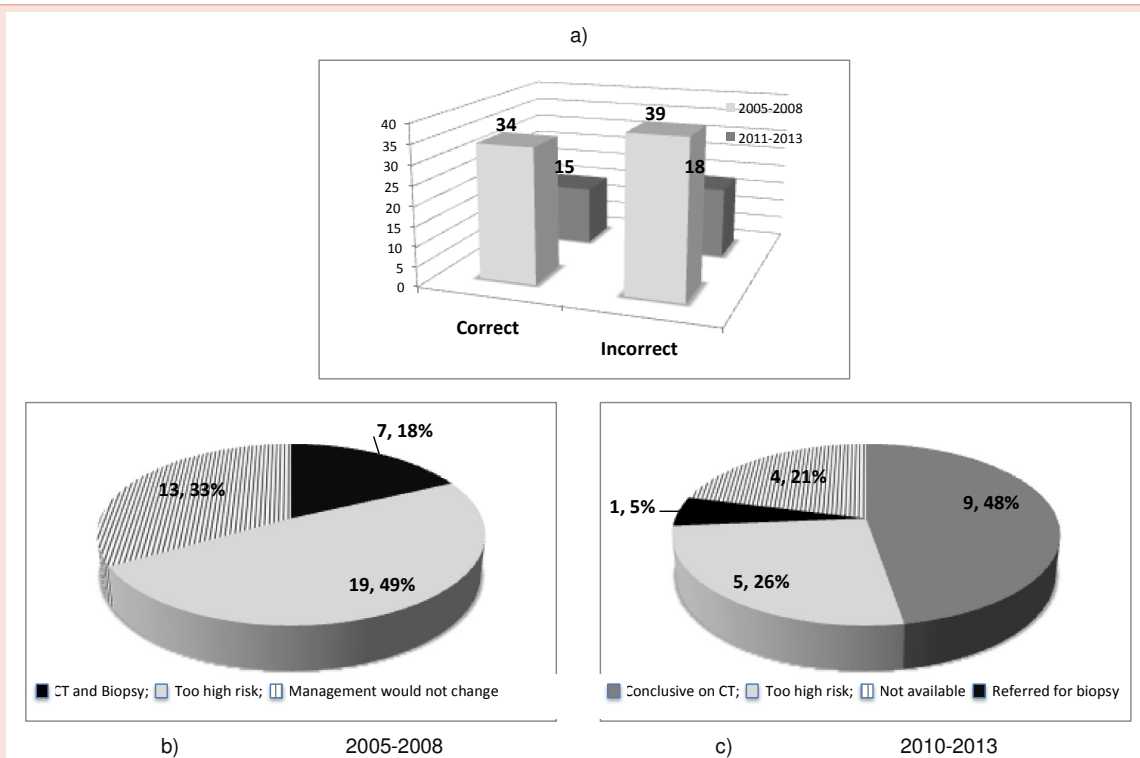
Change of diagnosis after MDT discussion is a recurring theme when addressing other ILDs. The diagnostic accuracy is somewhat better prior to MDT discussion compared to IPF. A third of diagnoses are changed after MDT discussion compared to over half in IPF.

Overall, for all cases MDT discussion with subsequent diagnosis clarification resulted in a change in treatment in 43% of cases.

## Conclusion

The accurate diagnosis and management of individuals with ILD poses an interesting challenge in clinical practice. ILD guidelines advocate an MDT approach to improve diagnostic accuracy and access to specialised treatments, with the ultimate goal of ensuring equality and improving patient care. ILD MDT diagnosis has also demonstrated better survival compared to patients diagnosed without MDT discussion [10]. Our data supports an MDT approach in an experienced specialised ILD center. We have demonstrated that diagnosis is often changed after an MDT review and that this impacts on subsequent management. We have shown that during diagnostic uncertainty the considered gold standard of proceeding to a lung biopsy is not always feasible due to disease severity and comorbidities. In these circumstances an MDT approach to diagnosis of ILDs combines clinical data with serial lung function and disease behavior, with or without responses to previous treatment trials to establish an accurate expert diagnosis. We acknowledge the major limitations of this retrospective review. We are presuming that a decade of experience in the diagnosis and management of ILDs serves to provide our MDT meetings with an expertise that is both robust and accurate. In the real world setting we have developed collaborative bench marking peer review strategies to address this on a local perspective by developing a Northern ILD network. This review is of real life clinical care and thus lacks the corroborative independent review of our clinical cases by a second independent blinded MDT. Despite this limitation we feel we have demonstrated the importance of an MDT review to ensure accurate diagnosis, assessment and subsequent treatment and advocates and supports the recommendation that a multidisciplinary team diagnosis is important for all individuals with ILD.





**Figure 4:** Multidisciplinary discussion and diagnosis of idiopathic pulmonary fibrosis. Accuracy of diagnosis of idiopathic pulmonary fibrosis (Figure 4a). If CT alone, why was a biopsy not performed (Figure 4b and c).

## References

- (2002) American Thoracic Society/European Respiratory Society International Multidisciplinary Consensus Classification of the Idiopathic Interstitial Pneumonias. American journal of respiratory and critical care medicine 165: 277-304.
- (2000) American Thoracic Society. Idiopathic pulmonary fibrosis: diagnosis and treatment. International consensus statement. American Thoracic Society (ATS), and the European Respiratory Society (ERS). American journal of respiratory and critical care medicine 161: 646-664.
- Navaratnam V, Fleming KM, West J, Smith CJ, Jenkins RG, et al. (2011) The rising incidence of idiopathic pulmonary fibrosis in the U.K. Thorax 66: 462-467.
- Gribbin J, Hubbard RB, Jeune IL, Smith CJP, West J, (2006) Incidence and mortality of idiopathic pulmonary fibrosis and sarcoidosis in the UK. Thorax 61: 980-985.
- Raghu G, Collard HR, Egan JJ, Martinez FJ, Behr J, et al. (2011) ATS/ERS/JRS/ALAT Committee on Idiopathic Pulmonary Fibrosis. An official ATS/ERS/JRS/ALAT statement: idiopathic pulmonary fibrosis: evidence-based guidelines for diagnosis and management. Am J Respir Crit Care Med 183: 788-824.
- Wells A, Hirani N (2008) Interstitial Lung Disease Guideline. Thorax 63: v1-v58.
- Cottin V, Crestani B, Valeyre D, Wallaert B, Cadranet J, et al. (2014) Diagnosis and management of idiopathic pulmonary fibrosis: French practical guidelines. Eur Respir Rev 23: 193-214.
- Flaherty KR, King TE Jr, Raghu G, Lynch JP 3rd, Colby TV, et al. (2004) Idiopathic interstitial pneumonia: what is the effect of a multidisciplinary approach to diagnosis? Am J Respir Crit Care Med 170: 904-910.
- Hanley M, Leonard C, Chaudhuri N (2015) P28 Real World MDT Diagnosis of Idiopathic Pulmonary Fibrosis. Thorax 70: A90.
- Lok SS (1999) Interstitial lung disease clinics for the management of idiopathic pulmonary fibrosis: a potential advantage to patients. Greater Manchester Lung Fibrosis Consortium. J Heart Lung Transplant 18: 884-890.

**Copyright:** © 2015 Chaudhuri N, et al. This is an open-access article distributed under the terms of the Creative Commons Attribution License, which permits unrestricted use, distribution, and reproduction in any medium, provided the original author and source are credited.

**Citation:** Chaudhuri N, Spencer L, Leonard C (2015) A Review of the Multidisciplinary Diagnosis of Interstitial Lung Diseases: A Retrospective Analysis in a Single UK Specialist Centre. Arch Pulmonol Respir Care 1(1): 018-022. DOI: <http://dx.doi.org/10.17352/aprc.000005>