

Amr Shaaban Hanafy*

Department of Internal medicine, Division of Hepatogastroenterology, Zagazig University, Egypt

Dates: Received: 12 March, 2017; Accepted: 17 June, 2017; Published: 19 June, 2017

*Corresponding author: Amr Shaaban Hanafy, Department of Internal medicine, Division of Hepatogastroenterology, Zagazig University, Egypt, E-mail: dr_amr_hanafy@yahoo.com

Keywords: Portal vein; Thrombosis; Splenectomy; Hypersplenism

<https://www.peertechz.com>

Case Report

Accidentally discovered Portal Vein Thrombosis before Splenectomy due to Hypersplenism - The role of Thrombogenic Genes Polymorphisms

Abstract

Portal vein thrombosis in patients with liver cirrhosis may be due neoplastic growth invading portal vein or due to non-neoplastic causes. The indications for treating PVT in cirrhotic individuals are difficult to be established but at least are of great benefit in acute PVT. Investigating the cause of portal vein thrombosis in cirrhotic patient prepared for splenectomy including virology and immune markers, AFP, triphasic CT. Factor V Leiden mutation and prothrombin gene 20210. The case showed non-neoplastic portal vein thrombosis due to portal pyemia with underlying prothrombin gene 20210 polymorphism. The early initiation of anticoagulation after the diagnosis of acute PVT may be the only predictive factor for complete PV recanalization with preservation of liver function.

Abbreviations

APC: Activated Protein C; Anti d DNA: Anti double Stranded DNA; AFP: Alfafetoprotein; ANA: Anti-Nuclear Antibodies; AMA: Anti Mitochondrial Antibodies; AT: Antithrombin III; CT: Computed Tomography; EVL: Esophageal Varices Banding; INR: International Normalized Ratio, LMWH: Low Molecular Weight Heparin; PVT: Portal Vein Thrombosis; TM: Thrombomodulin.

Introduction

Portal vein thrombosis (PVT) in patients with liver cirrhosis may be due to neoplastic growth invading portal vein or non-neoplastic causes that may include local causes as cirrhosis, hepatobiliary malignancy, portal pyemia, inflammatory diseases as pancreatitis, cholecystitis, cholangitis, appendicitis, ulcerative colitis or diverticulitis. Systemic causes as factor V Leiden mutation, prothrombin gene 20210 mutation, myeloproliferative disorders, hyperhomocysteinemia, antiphospholipid syndrome, recent use of contraceptive pills or early months of gestation [1].

It appears that prevalence increases with progression of liver disease being 1% in patients with compensated cirrhosis up to 25% in patients with urgent need for liver transplantation [2].

PVT has been associated with increased risk of hepatic decompensation, worse outcome including post-liver transplantation outcome. Predisposing factors for PVT are reduced blood flow velocity [3], severity of thrombocytopenia which reflects the severity of portal hypertension, previous variceal hemorrhage, post-splenectomy and endoscopic treatment of esophageal varices which may be complicated by thrombosis [4].

Cirrhotic coagulopathy

Cirrhosis can be associated with a hypercoagulable state despite the events that favor bleeding tendency and thrombocytopenia due to portal hypertension. Normally coagulation process is regulated through inhibition of thrombin generation via factors V and VIII inactivation mediated by activated protein C (APC) together with thrombomodulin (TM), protein S and negatively charged phospholipids. In cirrhosis, there is impaired production of coagulation factors except endothelium derived factor VIII, low levels of hepatic-derived protein C, S which augment thrombin production that converts fibrinogen to fibrin clot. Fibrinogen is often preserved or only mildly decreased in cirrhosis [5,6].

Also the decreased plasma levels of plasminogen and increased levels of plasminogen activator inhibitor may add to the procoagulant imbalance found in cirrhosis [7].

The clinical sequel of PVT include variceal bleeding or inability to control it, intestinal infarction when thrombosis extends to the superior mesenteric vein, PVT is a well-known risk factor of early mortality after liver transplantation and can also contraindicate liver transplantation in cases where thrombosis extends to the splenic or inferior mesenteric veins.

The aim of anticoagulation is recanalization of portal vein, complete recanalization occurred in up to 45% of patients while partial PV recanalization is observed in up to 35% of cases [5] which are similar to that occurred in noncirrhotic patients [8].

The indications for treating PVT in cirrhotic individuals are difficult to be established but at least are of great benefit in acute PVT with extension to the superior mesenteric vein, or PVT in cirrhotic individuals with a documented prothrombotic disorder.

The early initiation of anticoagulation within 14 days after the diagnosis of acute PVT may be the only predictive factor for complete PV recanalization [9].

In situation where cirrhotic patients develop PVT with preexisting bleeding esophageal varices; Amitrano et al noted no benefit in terms of variceal re-bleeding but a surprising improvement in survival in the treated group [10].

Clinically, patients may develop abdominal pain (22%) resistant to conventional analgesics especially when acute or extending to the mesenteric veins to cause intestinal ischemia, 45% is asymptomatic and 30% may present with upper gastrointestinal tract bleeding.

Choice of anticoagulants in cirrhotic patients with PVT

Choice of anticoagulants is difficult in cirrhotic patients due to problems in monitoring and the existing coagulopathy. Vitamin K antagonists have a rate of complete PV recanalization in cirrhotics between 40% and 45% after a mean duration 8.1 months of anticoagulation therapy [11]. The problem encountered is monitoring INR value which is altered in cirrhosis [5].

Low molecular weight heparin (LMWH) as enoxaparin has also been used to treat PVT in cirrhotic individuals, with complete PV recanalization in 33% after 6 months of treatment and in 75% of the cases when therapy was extended to another 6 months (median 6.5 months) [12].

The problems encountered are difficult dose calculation due to increased volume of distribution because of ascites and edema [13] and monitoring of anti-Xa cannot be used to guide therapy as it is dependent on antithrombin-III (AT) level, which is decreased in cirrhotic patients [13], also renal function is often impaired in cirrhotic patients and as LMWH is eliminated by the kidneys, their half-life will be increased.

The use of direct thrombin inhibitors as Dabigatran is an interesting subject; the potential advantage is that their mechanism of action is independent of AT. The rates of intracranial bleeding were significantly lower than in warfarin, but significantly higher with regard to gastrointestinal bleed

[14] and the lack of an antidote, however a promising agent such as Andexanet Alfa is currently being evaluated in two randomized, double-blind, placebo-controlled Phase 3 studies.

The optimal duration of anticoagulation therapy was not determined but partial response to anticoagulation at 6 months of therapy can get benefit from prolonged therapy up to 12 months [15], continuation of anticoagulation after 12 months in nonresponders was associated with a decreased risk of thrombosis progression [16].

As regards complications under anticoagulation therapy in cirrhotic patients; A platelet count <50,000 was the only factor more frequently associated with bleeding. It was shown that bleeding secondary to portal hypertension was more frequent in cirrhotic individuals with PVT without previous anticoagulation therapy [16].

It is preferable to screen for varices before starting anticoagulation. Patients with previous variceal bleeding, grade II or more esophageal varices with mucosal risky signs should be treated by esophageal varices banding (EVL) before anticoagulation together with nonselective beta-blockers. Anticoagulation therapy then will be initiated within 15 days after the procedure, some authors prefer to postpone the initiation of anticoagulation till eradication of esophageal varices to avoid post EVL bleeding but this will affect the rate of portal vein recanalization.

Case Report

46 year old female patient presented for medical evaluation before splenectomy due to pancytopenia. The family history was noncontributory, specifically for bowel disease or bowel cancer, and negative for any history of bleeding or clotting disorders.

On physical examination, the patient was afebrile with normal blood pressure 110/60 mmHg; heart rate 68 b/min, Specific examination findings was unrevealing except for palpable spleen. She did not demonstrate signs of anaemia or parenchymatous liver cell failure as jaundice, astrexis, ascites or lower limb oedema. Laboratory studies included complete blood count; WBCs 2300 cell/ul, platelets 34,000/ul, prothrombin concentration 42%, INR 1.9. Virology as HBsAg, HBcAb, and HCV Ab were negative. Markers of immune liver diseases as ANA, anti dDNA, AMA were negative, hemoglobin electrophoresis was normal, ferritin, serum copper and ceruloplasmin was normal. The patient was positive for antibilharzial antibodies and circulating bilharzial antigen. AFP was 5.6ug/dl, Bone marrow aspiration showed normal blood elements indicating peripheral destruction. Reticulocytic count was normal. Abdominal ultrasonography revealed cirrhotic liver with complete portal vein thrombosis, no focal lesions and splenomegally as shown (Figures 1,2).

Triphasic CT was performed and revealed complete PVT with intact mesenteric circulation and no hepatic focal lesion. At the time of examination, the patient was asymptomatic without abdominal pain, however the patient mentioned that she developed 6 months ago an attack of severe periumbilical

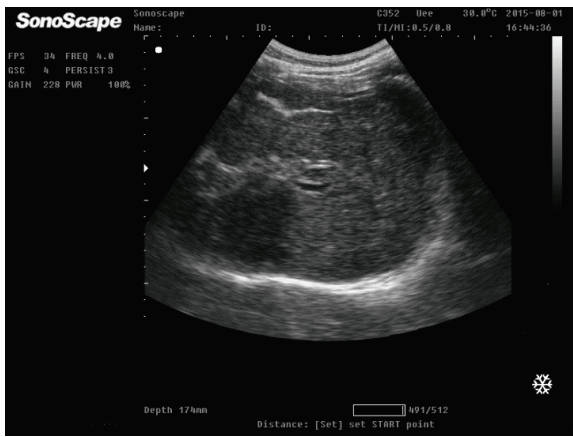


Figure 1: Abdominal ultrasonography reveals cirrhotic liver with complete portal vein thrombosis.

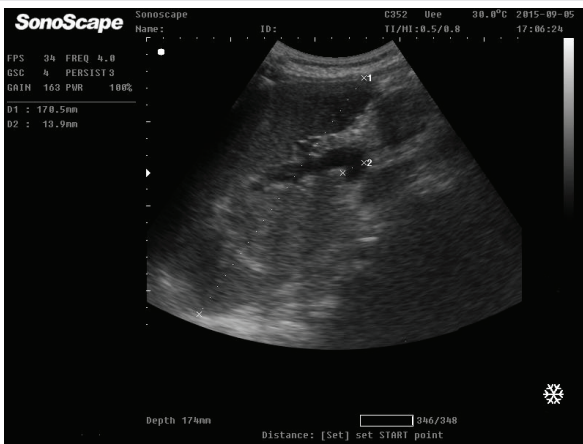


Figure 2: Abdominal ultrasonography revealed splenomegaly with bipolar diameter 170.5mm (normal up to 130 mm) and increased splenic vein diameter 13.9mm (normal up to 8-10mm).

abdominal pain 1 week after the development of thrombosed internal piles which lasted for 2 weeks but not investigated. Factor V Leiden and prothrombin gene 20210 were performed and the patient was positive for prothrombin gene 20210 polymorphism.

The diagnosis suggested is portal vein thrombosis induced by portal pyemia due to infected and thrombosed internal piles augmented by the thrombotic tendency due to positivity of prothrombin gene 20210.

Liver biopsy and the intention to treat by oral anticoagulation were deferred due to severe thrombocytopenia and INR prolongation. Upper GIT endoscopy was performed and revealed grade II-III esophageal varices which were banded in 2 sessions. 2 months later, the patient developed decompensation with ascites that responded well to torsamide 10 mg and spironolactone 100mg. the patient now on liver support and is preparing for liver transplantation.

Discussion

The false fixed belief that prolonged prothrombin time may enhance the tendency of bleeding in cirrhosis is now changing, complex and multifactorial processes make this hemostatic

dysequilibrium; both bleeding and coagulation tendency can occur in liver cirrhosis. Parenchymatous decompensation, severity of portal hypertension, sepsis and renal impairment increase the risk for bleeding [17].

The low protein C and S, the increase in the endothelium derived factors as factor VIII and von Willebrand factor (vWf) together with the sluggish portal blood flow in cirrhosis may enhance clotting [18].

A Platelet count more than $50,000/m^3$ in liver cirrhosis is adequate for a normal hemostasis as the high level of VWF can replace the platelet defect for thrombin generation [19].

Among the most common hereditary causes of venous thrombosis are Factor V Leiden (FVL) G1691A, prothrombin gene G20210A [20]. The gene that codes the Factor V Leiden protein is (F5) and is due to a mutation in exon 10 as a missense substitution of base A to base G, and this will change the protein's amino acid from arginine to glutamine, the mutation prevents efficient inactivation of factor V [20].

Prothrombin gene mutation is caused by G→A transition at nucleotide 20210 leading to elevation of plasma prothrombin levels [21].

Portal vein thrombosis is a quite uncommon situation and is associated with liver cirrhosis or prothrombotic disorder. Patients with acute PVT may present clinically acute abdominal pain unresolved with conventional analgesics, acute ascites or life threatening mesenteric ischemia with nausea and vomiting [22].

If hypercoagulable states are documented, then and patients are subjected to a long-term anticoagulation with the goal of complete recanalization of the portal vein otherwise, anticoagulation should be stopped within 3–6 months.

In conclusion, Portal vein thrombosis represents a life threatening clinical problem and should be treated urgently depending on its onset, associated vascular and parenchymatous complications.

References

- Chawla YK, Bodh V (2015) Portal Vein Thrombosis. *J Clin Exp Hepatol* 5: 22–40. [Link: https://goo.gl/wqjwSF](https://goo.gl/wqjwSF)
- Plessier A, Rautou PE, Valla DC (2012) Management of hepatic vascular diseases. *Journal of Hepatology* 56: 25-38. [Link: https://goo.gl/ubjTQD](https://goo.gl/ubjTQD)
- Senzolo M, Sartori T, Rossetto V, Burra P, Cillo U (2012) Prospective evaluation of anticoagulation and transjugular intrahepatic porto-systemic shunt for the management of portal vein thrombosis in cirrhosis. *Liver International* 32: 919-927. [Link: https://goo.gl/q2bPp1](https://goo.gl/q2bPp1)
- Valla DC (2008) Thrombosis and anticoagulation in liver disease. *Hepatology* 47: 1384-1393. [Link: https://goo.gl/rLH2eg](https://goo.gl/rLH2eg)
- Tripodi A, Anstee QM, Sogaard K, Valla DC, Primignani M (2011) Hypercoagulability in cirrhosis: causes and consequences. *Journal of Thrombosis and Haemostasis* 9: 1715-1723. [Link: https://goo.gl/bdV9o2](https://goo.gl/bdV9o2)
- Tripodi A, Primignani M, Lemma L, Chantarangkul V, Mannucci PM (2013) Evidence that low protein C contributes to the procoagulant imbalance in cirrhosis. *J Hepatol* 59: 265-270. [Link: https://goo.gl/LKZs3j](https://goo.gl/LKZs3j)

7. Tripodi A, Mannucci PM (2011) The coagulopathy of chronic liver disease. *The New England Journal of Medicine* 365: 147-156. [Link: https://goo.gl/GjfsYY](https://goo.gl/GjfsYY)
8. Plessier A, Darwish-Murad S, Hernandez-Guerra M, Fabris F, Heller J, et al. (2010) Acute portal vein thrombosis unrelated to cirrhosis: a prospective multicenter follow-up study. *Hepatology* 51: 210-218. [Link: https://goo.gl/ghnrF](https://goo.gl/ghnrF)
9. Delgado MG, Seijo S, Yepes I, Achécar L, Catalina MV, et al. (2012) Efficacy and safety of anticoagulation on individuals with cirrhosis and portal vein thrombosis. *Clinical Gastroenterology and Hepatology* 10: 776-783. [Link: https://goo.gl/V26am2](https://goo.gl/V26am2)
10. Amitrano L, Guardascione MA, Scaglione M, Menchise A, Martino R, et al. (2012) Splanchnic vein thrombosis and variceal rebleeding in patients with cirrhosis. *Eur J Gastroenterol Hepatol* 24: 1381-1385. [Link: https://goo.gl/8uaEfZ](https://goo.gl/8uaEfZ)
11. Khoury T, Ayman AR, Cohen J, Daher S, Shmuel C, et al. (2016) The Complex Role of Anticoagulation in Cirrhosis: An Updated Review of Where We Are and Where We Are Goings. *Digestion* 9s3: 149-159. [Link: https://goo.gl/68WAKQ](https://goo.gl/68WAKQ)
12. Senzolo M, Ferronato C, Burra CP, Sartori MT (2009) Anticoagulation for portal vein thrombosis in cirrhotic patients should be always considered. *Internal and Emergency Medicine* 4: 161-162. [Link: https://goo.gl/Q1iGN7](https://goo.gl/Q1iGN7)
13. Bechmann LP, Sichau M, Wichert M, Gerken G, Kröger K, et al. (2011) Low-molecular-weight heparin in patients with advanced cirrhosis. *Liver International* 31: 75-82. [Link: https://goo.gl/g5DeZF](https://goo.gl/g5DeZF)
14. Patel MR, Mahaffey KW, Garg J, Pan G, Singer DE, et al. (2011) Rivaroxaban versus warfarin in nonvalvular atrial fibrillation. *N Engl J Med* 365: 883-891. [Link: https://goo.gl/47j1Bg](https://goo.gl/47j1Bg)
15. Amitrano L, Guardascione MA, Menchise A, Rossana M, Mariano S, et al. (2010) Safety and efficacy of anticoagulation therapy with low molecular weight heparin for portal vein thrombosis in patients with liver cirrhosis. *Journal of Clinical Gastroenterology* 44: 448-451. [Link: https://goo.gl/tDPPA8](https://goo.gl/tDPPA8)
16. Senzolo M, Sartori T, Rossetto V, Burra P, Cillo U, et al. (2012) Prospective evaluation of anticoagulation and transjugular intrahepatic porto-systemic shunt for the management of portal vein thrombosis in cirrhosis. *Liver International* 32: 919-927. [Link: https://goo.gl/pfqCew](https://goo.gl/pfqCew)
17. Caldwell SH (2014) Management of Coagulopathy in Liver Disease. *Gastroenterol Hepatol* 10: 330-332. [Link: https://goo.gl/t97ufZ](https://goo.gl/t97ufZ)
18. Lisman T, Caldwell SH, Burroughs AK, Northup PG, Senzolo M, et al. (2010) Coagulation in Liver Disease Study Group. Hemostasis and thrombosis in patients with liver disease: the ups and downs. *J Hepatol*. 53: 362-371. [Link: https://goo.gl/dgK2AN](https://goo.gl/dgK2AN)
19. Tripodi, F. Salerno, V. Chantarangkul, Clerici M, Cazzaniga M, et al. (2005) Evidence of normal thrombin generation in cirrhosis despite abnormal conventional coagulation tests. *Hepatology* 41: 553-558. [Link: https://goo.gl/ok9THT](https://goo.gl/ok9THT)
20. Hirmerova J, Seidlerova J, subrt I (2014) The association of factor V Leiden with various clinical patterns of venous thromboembolism - the factor V Leiden paradox. *Q J Med* 107: 715-720. [Link: https://goo.gl/KnccaV](https://goo.gl/KnccaV)
21. Prat M, Morales-Indiano C, Jimenez C, Mas V, Besses C, et al. (2014) "20209C-T" a variant mutation of prothrombin gene mutation in a patient with recurrent pregnancy loss. *Ann Clin Lab Sci* 44: 334-336. [Link: https://goo.gl/nt7hqZ](https://goo.gl/nt7hqZ)
22. James AW, Rabl C, Westphalen AC, Fogarty PF, Posselt AM, et al. (2009) Portomesenteric venous thrombosis after laparoscopic surgery: a systematic literature review. *Archives of Surgery* 144: 520-526. [Link: https://goo.gl/V7wahg](https://goo.gl/V7wahg)

Copyright: © 2017 Hanafy AS. This is an open-access article distributed under the terms of the Creative Commons Attribution License, which permits unrestricted use, distribution, and reproduction in any medium, provided the original author and source are credited.