

Bar Ronen and Braverman Itzhak\*

Otolaryngology Head and Neck Surgery, Hillel-Yaffe Medical Center, Affiliated with the Rappaport Faculty of Medicine, The Technion, Haifa, Israel

**Dates:** Received: 17 August, 2015; Accepted: 19 October, 2015; Published: 21 October, 2015

\***Corresponding author:** Braverman Itzhak, Assistant Professor and Chairman Otolaryngology Head & Neck Surgery, Hillel-Yaffe Medical Center, Hadera Israel. P.O.Box 169. Hadera 38100, Israel, Tel: 972-4-6188216; Fax: 972-4-6304885; E-mail: Braverman@hy.health.gov.il

[www.peertechz.com](http://www.peertechz.com)

ISSN: 2455-1759

**Keywords:** Tonsillectomy; Bleeding; Haemostatic Materials

## Case Report

# The Risks of Hemostatic Material in Tonsillectomy

### Abstract

**Importance:** Surgicel is an effective hemostat either for intra or post-operative bleedings, but should be used cautiously in the case of tonsillectomy. Some surgeons choose to leave pieces of surgicel in the tonsils bed for a continuous haemostatic effect. The material when left in the tonsils fossa is no different than other foreign body and put the patient in a significant risk of suffocation.

**Observations:** four years old girl was admitted to the E.R with multiple complaints and rapid deterioration of her physical state few days after tonsillectomy. Bulky Haemostatic Material spheres almost completely blocked the oropharynx. The foreign material was removed and the complaints resolved, with full recovery.

**Conclusions and Relevance:** leaving surgicel impactions in the oropharynx upon completion of tonsillectomy operation should be avoided.

## Introduction

Surgicel (Ethicon, USA) is a haemostatic agent made of an oxidized cellulose polymer, manufactured by Johnson and Johnson's Ethicon subsidiary. It was first introduced into practice in 1947. Its main usage was to control intra-operative bleeding. For example, surgicel is widely used in oral and maxillofacial surgery in order to control intra-osseous hemorrhage [1].

## Case Report

A 4 year old girl was admitted to the E.R at Hillel Yaffe Medical Center with the complaints of fever,odynophagia, malaise, difficulty opening the mouth and muffled voice. The complaints started 4 days earlier, after tonsillectomy and adenoidectomy in another hospital. Upon physical examination the findings were signs of dehydration, muffled voice, and a refusal to open the mouth. When the child finally opened her mouth, we noted two round solid packing, one at each tonsil bed. The packing was removed and inspected thoroughly (Figure 1). The packing was a round condensed Surgicel, which was pre-formed by the surgeon to fit the size and shape of the tonsil beds. The surgeon put the material on both tonsil beds at the end of the surgery to create a prolonged haemostatic effect. The surgeon sutured the anterior and posterior pillars to apply local pressure and cease the ongoing oozing of blood on both sides. Unfortunately the partial dehiscence of the suture line exposed the foreign material, which was only partly anchored and bulged into the lumen on both sides. Thus put the child in a risk of aspiration and suffocation and contributed to the deterioration in her general condition. Rapid recovery was made once the Surgicel spherical foreign bodies were removed.

The institutional ethical committee approved the publication of this case report.

## Discussion

There are few references reporting the use of haemostatic material in tonsillectomy. The main benefit of surgicel is in controlling the non-

focal oozing of blood into the tonsil fossa at the end of the operation.

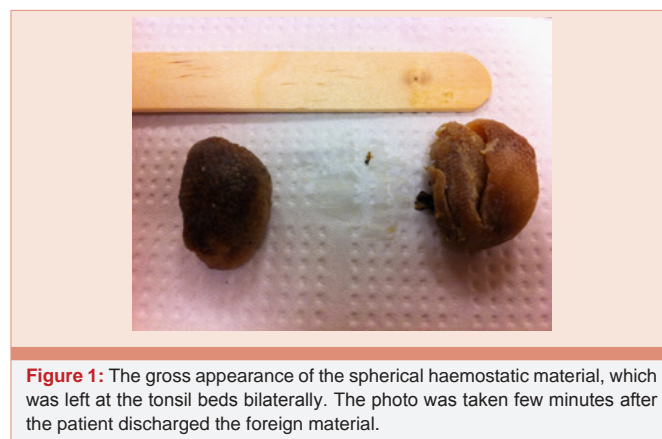
This is in contrary to focal bleeding which would be stopped by clamping the vessel by various techniques [1].

Abdumohsain and Yaseen described a technique for hemorrhage control, using a piece of Surgicel in the dimensions of 5×7.5 centimeters for both fossa. The tonsil fossa is coated with the Surgicel absorbable piece for complete adherence. It is left in the fossa until complete absorption [2].

Others mandate either suturing the Surgicel to the fossa, or obliterating the fossa with sutures between the anterior and posterior pillars, to prevent migration of the foreign material from the fossa and aspiration to the airway [3].

In the past, non-absorbable Surgicel gauze was in use, and remained sutured to the tonsil bed for few days to prevent the ongoing bleeding.

When the haemostatic effect was achieved the fossa was exposed and the Surgicel gauze removed [2,3].



**Figure 1:** The gross appearance of the spherical haemostatic material, which was left at the tonsil beds bilaterally. The photo was taken few minutes after the patient discharged the foreign material.

There are reports of post-operative bleeding that occurred several days after tonsillectomy that was halted with Surgicel.

One should remember that complete absorption takes 28 to 72 days, hence leaving the Surgicel in the tonsil bed put the patient in a risk of foreign body with the potential to dislodge into the airway [1].

For this reason, the minimum should be left in the fossa, attached to the surrounding tissues [1,4].

In this case, the surgeon rolled the Surgicel into a tufted ball, and left it in the fossa. The pillars were sutured with absorbable sutures. On the post-operative course these sutures partially dissolved due to the increased pressure caused by the hydrated Surgicel on the suture line. The result was a medial dislodgement of the round Surgicel impactions to the oropharynx lumen, blocking incompletely the passage of air and food. This obstruction was the reason for the complaints that the patient had. The foreign material posed a risk of either aspiration or swallowing of the Surgicel impactions, which could result in suffocation and death.

## Conclusion

Our recommendation is to minimize the use of haemostatic

material as a bulky substance left in the tonsil bed in tonsillectomy. When no alternative exist due to profound blood oozing, the fossa should be carefully packed with Surgicel pieces that are substantially anchored to the tonsil bed with sutures. The Surgicel should be used unfolded in its mono-layer form. Avoid condensed spherical shapes that would accumulate secretions and enlarge significantly post-operatively. In these cases further inspection should be scheduled to the third or fourth day post-operative to verify that the Surgicel is still in the fossa with the option of removing emerging Surgicel pieces.

## References

1. Goodman RS (1996) Surgicel in the control of post-tonsillectomy bleeding. *Laryngoscope* 106: 1044-1046.
2. Abdulmohsain EH, Yaseen HA (2009) Hemostasis with surgicel for tonsillectomy: a pilot study. *Bas J Surg* 15.
3. Grainger J, Nico J Pediatric tonsillectomy. Open access atlas of otolaryngology, head & neck operative surgery By Johan Fagan (Editor) johannes.fagan@uct.ac.za is licensed under a Creative Commons Attribution - Non-Commercial 3.0 Unported License 1-9.
4. Randall DA, Hoffer ME (1998) Complications of Tonsillectomy and Adenoidectomy. *Otolaryngol Head Neck Surg* 118: 61-68.