

Case Series

Natural facelift longevity: A unique observation in a deep plane facelift case series

Brian P Dickinson* and Peter F Giacobazzi

M.D. Inc. Newport Beach, CA, USA

Received: 03 July, 2020

Accepted: 13 July, 2020

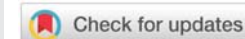
Published: 14 July, 2020

*Corresponding author: Brian P. Dickinson, M.D., Inc, 351 Hospital Road, Suite 415, Newport Beach CA 92663, USA, Tel: 949-612-8632; Fax: 310-861-1478; E-mail: drdickinson@drbriandickinson.com

Keywords: Facelift; Rhytidectomy; Secondary facelift; Deep plane facelift

ORCID: <https://orcid.org/0000-0001-7185-0860>

<https://www.peertechz.com>



Abstract

Background: Facelift procedures are technically challenging and are difficult procedures to consistently achieve good results. Critical evaluation of one's facelift results in their practice over time is helpful to evaluate progress and to find areas to improve upon so that we can optimize patient results. We evaluated our charts and before and after photographs to improve our quality and examined healing time and long term results. During our review, we discovered a unique observation where we compared the deep plane facelift results to subcutaneous or limited Superficial Musculoaponeurotic System (SMAS) facelifts.

Methods: A retrospective chart review was conducted on all patients who underwent deep-plane facelift by the junior author between 2008 and 2020 and the senior author between 1978 and 2015. Patient satisfaction was measured subjectively in chart review. During the course of the review, so the junior author could learn, the junior author reviewed the senior author's results. In the learning process, we encountered four patients who underwent a subcutaneous or limited SMAS facelift years prior to their deep-plane rhytidectomy and then compared the photographs with regard to the neck, jowls, nasolabial folds, and malar fat pad at an equivalent interval post-op deep plane facelift. In this manner the patient served as their own internal control and the deep plane had actually been performed later in life.

Results: The recovery time was comparable to subcutaneous or SMAS facelifts. Four patients had undergone a deep plane facelift and a prior subcutaneous or limited SMAS facelift. The follow-up ranged from 3 to 10 years post deep plane facelift. Photographic comparison consisted of the pre-operative deep plane photograph which was also frequently defined as the time post-operatively from the patient's previous subcutaneous or limited SMAS facelift. The deep plane facelift appeared to have maintained correction over time with regard to the neck, jowls, nasolabial folds, and malar fat pad at an equivalent or greater time interval despite the patient being older.

Conclusion: The deep plane facelift is a safe and durable method to address the aging changes of the neck, jowls, nasolabial fold, and malar fat pad. The technique is helpful to avoid a previously created surgical plane in secondary facelifts. We present a unique observation in this series where the deep plane technique tended to show long lasting results when compared to the subcutaneous facelift in the same individual.

Introduction

Aesthetic & reconstructive surgery of the face and oncologic reconstruction of the head and neck remains one of the most interesting surgical specialties as there are ample difficult surgical challenges. The field of preservation rhinoplasty advances aesthetic nose surgery results with elevation of soft tissue structures off periosteum or perichondrium to preserve soft tissue characteristics and prevent unfavorable scarring, with the intention to produce longer lasting results that are less subject to change over time [1]. As the field of rhinoplasty advances, so does facial rejuvenation surgery with the intention to produce similar long lasting youthful changes to the face that are not subject to long-term scarring changes. Translating

the preservation rhinoplasty concepts to the face, the deeper dissection can theoretically lead to more predictable long term results.

The deep plane facelift technique was first described by Hamra [2], where a sub-SMAS dissection creates a skin flap that can release the retaining ligaments of the face and rejuvenate the nasolabial fold caused by ptosis of the malar fat pad. The deep plane facelift technique with platysmal dissections in the neck results in a musculo-fasciocutaneous flap with excellent blood supply [3]. In his own evaluation of cases, Hamra conceded recurrence of the nasolabial fold after one to two years post deep plane facelift, despite continued improvement in the periorbital regions [4]. Despite this, in the

past two decades, comparisons have been made with the deep plane facelift technique to other rhytidectomy techniques [5-18]. Comparison of techniques in surgery is challenging as there is variability among patients, variation in techniques among surgeons, identical twins undergoing different techniques are few in number, and various factors contribute to healing and recurrence.

We present an observation where the deep plane technique demonstrates longevity in patients who had a previous subcutaneous or limited SMAS facelifts by comparing photographs of patients who underwent a deep plane facelift and a previous subcutaneous facelift such that the patients served as their own control.

Methods

The deep plane facelift technique used during the period was standard among all patients. The subcutaneous dissection started at the ear for three centimeters and then transitioned to a sub-SMAS dissection to the zygomaticus major and the upper lip. The dissection remained subcutaneous above the level of the zygomatic arch to the orbicularis oculi. The subcutaneous dissection was then joined to the sub-SMAS dissection in the cheek after transecting the malar retaining ligaments so that the cheek could be elevated. The SMAS flap was then pulled posteriorly and superiorly and sutured to the SMAS anterior to the tragus and to the mastoid posteriorly.

A retrospective chart review was conducted on all patients who underwent deep-plane rhytidectomy by the junior author between 2008 and 2020 and the senior author between 1978 and 2015. No patients received facial resurfacing except for perioral fractional CO₂ in one patient in the photographs. In the chart review, we selected random patients to evaluate healing time to determine photographically if healing was prolonged.

During the course of the review, so the junior author could learn, the junior author reviewed the senior author's results and techniques. In the course of the review and learning process, we encountered four patients who underwent a subcutaneous or limited SMAS rhytidectomy years prior to their deep plane rhytidectomy and then compared the photographs with regard to the neck, jowls, nasolabial folds, and malar fat pad at an equivalent post-op time interval. In this manner the patient served as their own internal control and the deep plane had actually been performed later in life. The photographs were evaluated for signs of facial aging with regard to the nasolabial folds and jowls.

Results

Satisfaction was high with the deep plane facelift. Examination of before and after results yielded natural looking results with correction of the neck, jowls, nasolabial folds, and malar fat pad. The deep plane facelift showed stable results at one year post-operatively (Figures 1-4).

To assess speed of recovery we evaluated photographs at early post-op intervals. The rate of post operative swelling and bruising were similar to subcutaneous or limited SMAS facelifts during the early postoperative period (Figure 5-8). On average, patients were off of narcotic pain medication after 2

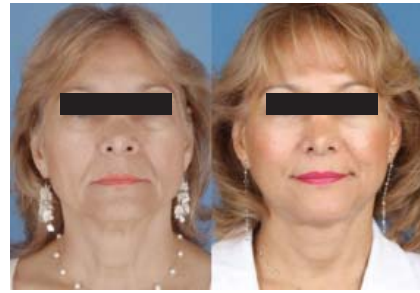

Figure 1: At one year the deep plane facelift showed natural results with correction of the malar fat pad, nasolabial folds, jowls, and neck.

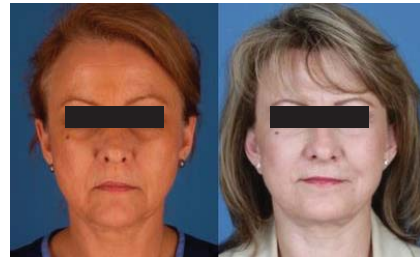

Figure 2: Upper and lower blepharoplasty in combination with the deep plane facelift keeps the face appearing rejuvenated at one year of follow-up.

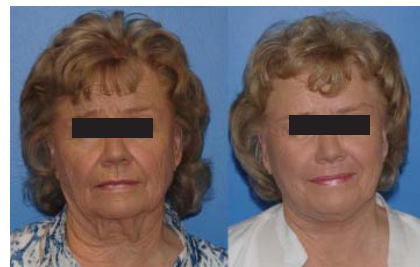


Figure 3: At one year follow-up the anterior plication of the platysma in conjunction with the pull of the deep plane allows for good correction of the neck and for excision of facial rhytids.

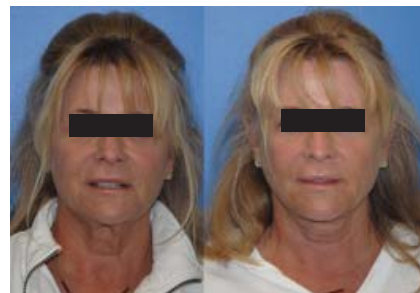

Figure 4: The deep plane facelift maintained the improvement in the malar fat pad, nasolabial fold, jowls, and neck at the one year mark.

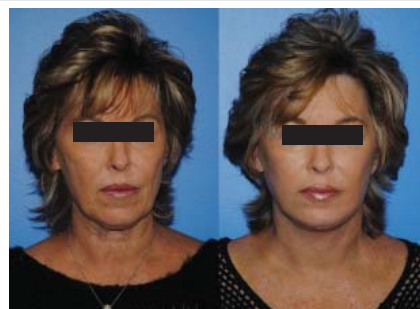

Figure 5: To assess speed of healing, photographs were taken in the early post-op period. At one week the patient demonstrates excellent healing with minimal bruising.

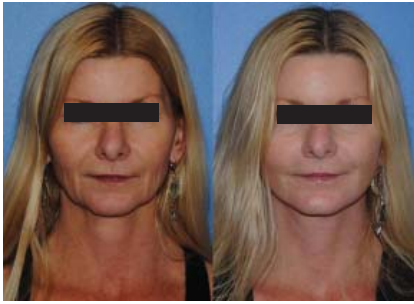

Figure 6a: The patient is one week post-operatively from a deep face lift with minimal bruising and an appropriate amount of swelling.

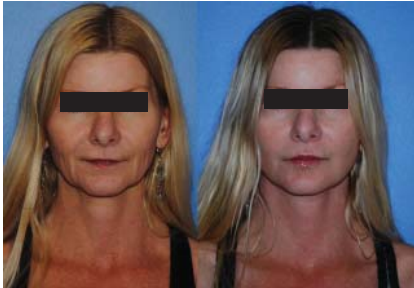

Figure 6b: At one year the deep plane facelift maintains its correction.

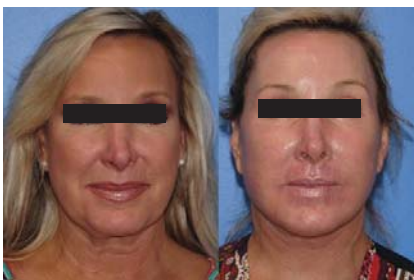

Figure 7a: Five days postoperatively from a deep plane facelift and perioral CO2 laser skin resurfacing .

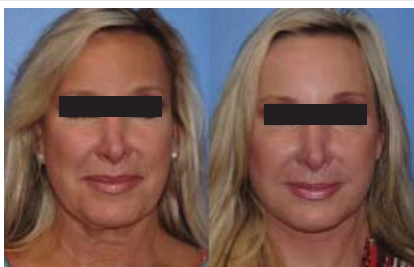

Figure 7b: At one year post-operatively, the deep plane facelift maintains the correction of facial aging.

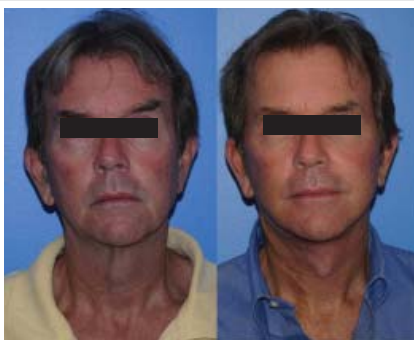

Figure 8: Two weeks postoperatively from a facelift in a male patient.

days. In general, we encouraged patients to restrict activity in the two week post-operative period as patients healed quickly and often wished to resume exercise prematurely.

When we then examined the four patients during the study period who had undergone a deep plane rhytidectomy and prior subcutaneous or limited SMAS rhytidectomy. This subset of four patients did not undergo skin resurfacing of any type.

The first photograph in the series is of a 52 year old woman who is 3 years post-operative from a subcutaneous rhytidectomy and in the next series she is 55 years old and 3 years post-operatively from a deep plane rhytidectomy (Figure 9). The nasolabial folds and jowls remained corrected 3 years post-operatively from the deep plane compared to the subcutaneous rhytidectomy despite being three years older.

The second photograph in the series is a 70 year old woman who is 2 years post subcutaneous rhytidectomy and in the second set of photographs, she is 73 years old and 3 years post deep plane rhytidectomy (Figure 10). Again, notice that the jowls and nasolabial folds remain corrected after the deep plane rhytidectomy despite being 3 years older.

The third patient in the photographic series is 58 years old and 10 years post a subcutaneous rhytidectomy and in the second series, she is 68 years old and 10 years post a deep plane rhytidectomy (Figure 11). The nasolabial folds and jowls remain more youthful after the deep plane rhytidectomy.

The last patient in the photographic series is 58 years old and 6 years post subcutaneous rhytidectomy and in the second series, she is 64 years old and 6 years following a deep plane rhytidectomy (Figure 12).

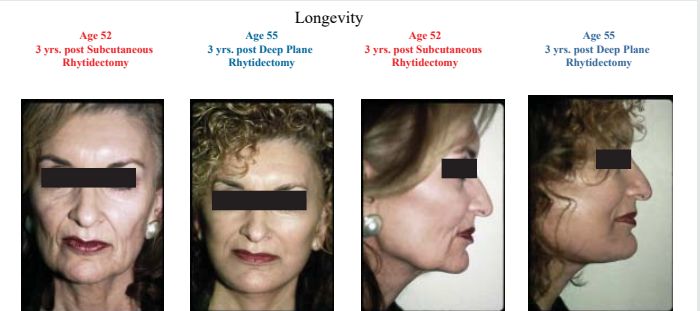

Figure 9: Longevity. In the before photograph, the patient is 52 years old and 3 years post-op from subcutaneous rhytidectomy, liposuction of nasolabial fold. In the after photograph the patient is 62 years old and 3 years post-op from deep plane rhytidectomy.

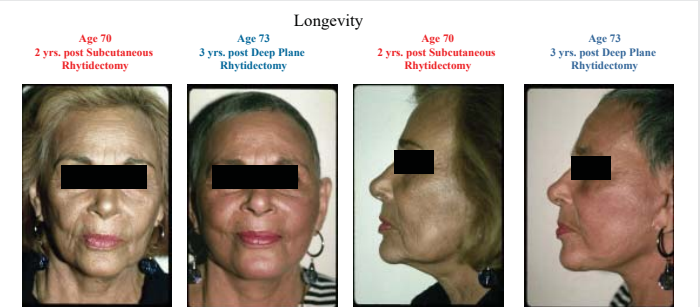

Figure 10: Longevity. In the before photograph, the patient is 70 years old, 2 years post-op from subcutaneous rhytidectomy. In the after photograph, the patient is 73 years old, 3 years post-op from deep plane rhytidectomy.

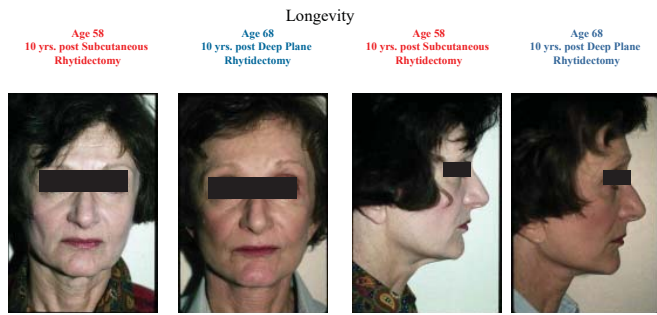


Figure 11: Longevity. In the before photograph, the patient is 58 years old, 10 years post-op from subcutaneous rhytidectomy and blepharoplasty. In the after photograph, the patient is 68 years old, 10 years post-op from deep plane rhytidectomy and coronal brow lift.

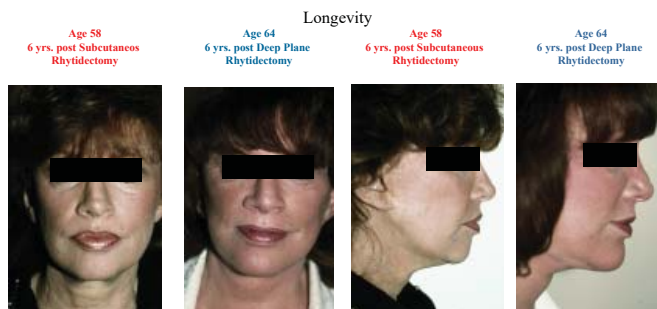

Figure 12: Longevity. In the before photograph, the patient is 58 years old 6 years post-op from subcutaneous rhytidectomy and blepharoplasty. In the after photograph, the patient is 64 years old 6 years post-op from deep plane rhytidectomy and coronal brow lift.

Discussion

There are many different facelift techniques used by aesthetic, plastic & reconstructive, and facial plastic surgeons. There is no technique that is absolutely the best, for there are multiple variables, such as surgeon experience and subjectivity regarding facial aesthetics, and patient-dependent issues such as differences in skin quality, overall health, and the facial aesthetic issues and expectations of each patient. There has been a tendency in the past toward limited dissections based on the preconceived premise that extensive sub-SMAS dissection leads to a higher likelihood of facial nerve injury, more bruising and swelling, and an overall prolonged recovery time. In our experience nerve injury did not occur and recovery time was not prolonged. There were no episodes of hematoma in the face as there is no subcutaneous dead space with the deep plane technique. Hematomas in the neck can occur as a separate subcutaneous space is created.

Traditional rhytidectomy techniques are effective at addressing aging changes of the lower face and neck, and are less effective in addressing aging changes of the midface and melolabial folds. Often adjunctive measures such as fat transfer are used in the cheek to augment volume or reposition volume more superiorly. These techniques are helpful adjuncts.

Repositioning of the malar fat pad with the deep plane technique can accomplish the same effect and in the same surgical field. Some surgeons believe that the deep plane or composite facelifts lead to longer lasting results [4-17]. Despite

these beliefs, proving the durability of a facelift is difficult. Critics of the technique state that there is a higher complication rate, longer down time, and no difference in results. We do not find any higher complication rate, no increase in down time, and good results with repositioning of the malar fat pad.

In our experience, there were no episodes of preauricular skin ischemia and this was our impetus in using the deep plane technique. The thick myocutaneous flap has a robust blood supply and not only maintains stable healing, but stable soft tissue with more predictable healing. Just as preservation rhinoplasty intends to prevent long term subcutaneous changes in the nose, the deep plane facelift is the analogous facial rejuvenation technique. Post-auricular ischemia can occur with the deep plane technique as with other techniques and usually resolves with local wound care. Overall, we believe that the deep plane rhytidectomy is safe.

It is our opinion that the goal of rhytidectomy is not to change identifying features of the face, but rather to allow the patient to look like a younger version of themselves for a longer period of time. In the deep plane facelift, the malar fat pad is separated from its attachments to the zygomaticus muscles, which is joined with sub-SMAS dissection in the lower face. The result is a composite flap that includes the malar fat pad, which now is mobilized and can be repositioned to restore youthful contour to the face. When the short and long-term photographic results were examined the patients who had the deep plane facelifts had a natural “undone” appearance. In our experience with the deep plane facelift, because more soft tissue can be mobilized with less tension on the skin, the rhytidectomy has a more natural-appearing look, and fewer secondary signs of rhytidectomy.

We concede that there are few patients in our comparison to observe and this is an obvious limitation of our chart review. However, from our observations we believe that the deep plane facelift exhibits longer lasting results than the subcutaneous facelift. When we compared the photographs of those patients who underwent a deep plane facelift and who had a prior subcutaneous facelift at the same postoperative interval, it appeared that the rejuvenated appearance persisted longer despite the patient also being older. Some have postulated that the deep plane is a robust musculocutaneous flap that is better vascularized and retains the original continuity between the subcutaneous tissues and the SMAS. The lack of disruption of these structures may be important in decreasing the recurrence of ptosis in the post-operative years.

While we find our observation unique and significant, we understand that there are limitations to our study. The most obvious limitation, as stated earlier is that we have only four patients to make this comparison. Secondly, we do not have any patients to compare the opposite scenario, that is those individuals who underwent a deep plane facelift followed by a subcutaneous facelift. Thirdly, not all the previous subcutaneous operations were performed by the same surgeon and create a greater variability. We do not wish to conclude that any facelift technique is superior, but simply in this small patient group the deep plane technique appeared to provide



a long lasting result in patients who underwent a secondary facelift using a different surgical plane and it was completed safely.

Summary

The deep plane facelift appears to give highly durable results, a natural-appearing facelift result, and an adequate acceptable recovery time with patient satisfaction.

References

- Daniel RK (2018) The Preservation Rhinoplasty: A New Rhinoplasty Revolution. *Aesthet Surg J* 38: 228-229. [Link: https://bit.ly/2ZnJMa3](https://bit.ly/2ZnJMa3)
- Hamra ST (1990) The deep plane rhytidectomy. *Plast Reconstr Surg* 86: 53-61. [Link: https://bit.ly/3fqOyZL](https://bit.ly/3fqOyZL)
- Schuster RH, GambleWB, Hamra ST, Manson PN (1995) A Comparison of Flap Vascular Anatomy in Three Rhytidectomy Techniques. *Plast Reconstr Surg* 95: 683-690. [Link: https://bit.ly/32d6H9y](https://bit.ly/32d6H9y)
- Hamra ST (2002) A Study of the Long-Term Effect of Malar Fat Repositioning in Face Lift Surgery: Short-Term Success But Long-Term Failure. *Plast Reconstr Surg* 110: 940-951. [Link: https://bit.ly/3eswtJn](https://bit.ly/3eswtJn)
- Ivy EJ, Lorenc ZP, Aston SJ (1996) Is there a difference? A prospective study comparing lateral and standard SMAS facelifts with extended SMAS and composite rhytidectomies. *Plast Reconstr Surg* 98: 1135-1143. [Link: https://bit.ly/3039Ru6](https://bit.ly/3039Ru6)
- Ivy EJ, Lorenc ZP, Aston SJ (1996) Is there a difference? A prospective study comparing lateral and standard SMAS lifts with extended SMAS and composite rhytidectomies (discussion). *Plast Reconstr Surg* 98: 1135-1143. [Link: https://bit.ly/2WdsJ8u](https://bit.ly/2WdsJ8u)
- Wulu JA, Spiegel JH (2018) Is deep plane rhytidectomy superior to superficial musculoaponeurotic system plication facelift?. *Laryngoscope* 128: 1741-1742. [Link: https://bit.ly/20IMHJK](https://bit.ly/20IMHJK)
- Alpert BS, Baker DC, Hamra ST, Owsley JQ, Ramirez O (2009) Identical Twin FaceLifts with Differing Techniques: A 10-Year Follow-Up. *Plast Reconstr Surg* 123: 1025-1033. [Link: https://bit.ly/3evExcJ](https://bit.ly/3evExcJ)
- Adamson PA, Dahiya R, Litner J (2007) Midface effects of the deep-plane vs the superficial musculoaponeurotic system plication face-lift. *Arch Facial Plast Surg* 9: 9-11. [Link: https://bit.ly/3iXxigT](https://bit.ly/3iXxigT)
- Bassichis BF, Bassichis BA (2004) Deep plane face-lift vs superficial musculoaponeurotic system plication face-lift: a comparative study. *Arch Facial Plast Surg* 6: 8-13. [Link: https://bit.ly/2WgbbZg](https://bit.ly/2WgbbZg)
- Kamer F, Frankel A (1998) SMAS rhytidectomy versus deep plane rhytidectomy: an objective comparison. *Plast Reconstr Surg* 102: 878-881. [Link: https://bit.ly/2ZZT7DU](https://bit.ly/2ZZT7DU)
- Adamson PA, Litner DR (2007) Midface effects of the deep-face vs. the superficial musculoaponeurotic system plication face-lift. *Arch Facial Plast Surg* 9: 9-11. [Link: https://bit.ly/2ZYF4OY](https://bit.ly/2ZYF4OY)
- Alsaraf R, Johnson CM (2000) The face lift: technical considerations. *Facial Plast Surg* 16: 231-238. [Link: https://bit.ly/308Rdki](https://bit.ly/308Rdki)
- Hamra ST (2006) 25,000 and still counting. *Plastic and Reconstructive Surgery* 118: 801-804. [Link: https://bit.ly/3j0o4jV](https://bit.ly/3j0o4jV)
- Tremolada C, Fissette J, Candiani P (1994) Anatomical basis for a safe and easier approach to composite rhytidectomy. *Aesthetic Plastic Surgery* 18: 387-391. [Link: https://bit.ly/2WdJZdY](https://bit.ly/2WdJZdY)
- Gentile RD (2005) Subperiosteal deep plane rhytidectomy: the composite midface lift. *Facial Plast Surg* 21: 286-295. [Link: https://bit.ly/2DCoyN6](https://bit.ly/2DCoyN6)
- Baylis HI, Goldberg RA, Shorr N (2000) The Deep Plane Facelift: A 20-year Evolution of Technique. *Ophthalmology* 107: 490-495. [Link: https://bit.ly/2WbAOL2](https://bit.ly/2WbAOL2)
- Alsarraf R, To WC, Johnson CM (2003) The deep plane facelift. *Facial Plast Surg* 19: 95-105. [Link: https://bit.ly/3fjUEuW](https://bit.ly/3fjUEuW)

Discover a bigger Impact and Visibility of your article publication with Peertechz Publications

Highlights

- ❖ Signatory publisher of ORCID
- ❖ Signatory Publisher of DORA (San Francisco Declaration on Research Assessment)
- ❖ Articles archived in worlds' renowned service providers such as Portico, CNKI, AGRIS, TDNet, Base (Bielefeld University Library), CrossRef, Scilit, J-Gate etc.
- ❖ Journals indexed in ICMJE, SHERPA/ROMEO, Google Scholar etc.
- ❖ OAI-PMH (Open Archives Initiative Protocol for Metadata Harvesting)
- ❖ Dedicated Editorial Board for every journal
- ❖ Accurate and rapid peer-review process
- ❖ Increased citations of published articles through promotions
- ❖ Reduced timeline for article publication

Submit your articles and experience a new surge in publication services (<https://www.peertechz.com/submit>).

Peertechz journals wishes everlasting success in your every endeavours.

Copyright: © 2020 Dickinson BP, et al. This is an open-access article distributed under the terms of the Creative Commons Attribution License, which permits unrestricted use, distribution, and reproduction in any medium, provided the original author and source are credited.

Citation: Dickinson BP, Giacobazzi PF (2020) Natural facelift longevity: A unique observation in a deep plane facelift case series. *Arch Otolaryngol Rhinol* 6(3): 066-070. DOI: <https://dx.doi.org/10.17352/2455-1759.000125>