



Case Report

Lessons from COVID-19 plain chest radiographs on pathophysiology, early diagnosis and therapeutics

Ndaba Sibusiso¹, Sabela Tholakele¹, Mnqwazi Chizama¹,
Sithole Sthembiso¹, Sithole Nokwanda¹, Mashigo Boitumelo¹,
Mhlana Nontembiso¹ and Ntshalintshali Sipho^{1,2*}

¹Department of Internal Medicine, Tygerberg Hospital, Stellenbosch University, Cape Town, South Africa

²Division of Rheumatology, Tygerberg Hospital, Stellenbosch University, Cape Town, South Africa

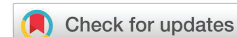Received: 09 May, 2020

Accepted: 22 June, 2020

Published: 23 June, 2020

*Corresponding author: Ntshalintshali Sipho, Division of Rheumatology, Tygerberg Hospital, Stellenbosch University, Cape Town, South Africa, Tel: +27638044024; E-mail: sipho.duncan@gmail.com; 24106143@sun.ac.za

<https://www.peertechz.com>



Abstract

Introduction: There are multiple radiographic manifestations of COVID-19 described in recent literature on plain chest radiographs and lung CT scans. We discuss observations on apparent similarities and differences seen on plain chest radiographs of confirmed COVID-19 cases with clinically mild, moderate and severe form of disease.

Material and method: We randomly selected 3 cases of COVID-19 with mild, moderate and severe disease, and compared the radiological findings on plain chest radiographs.

Results: The radiographic observations suggest that poorly aerated regions of the lung are affected early during the disease course. The inference is that improving the degree of lung aeration may limit the spread of the disease on the remainder of the lung parenchyma. Therefore, early oxygen supplementation therapy may prevent progression of a clinically mild COVID-19 case to moderate or severe form of disease.

Conclusion: Early plain chest radiographs may assist to increase the index of suspicion in a COVID-19 Patient Under Investigation (PUI) with pending RT-PCR results. The degree of lung aeration in COVID-19 correlates with the disease severity. Early oxygen therapy in mild cases may prevent progression of COVID-19. Larger studies are recommended to ascertain the statistical significance of these findings.

Abbreviations

ACE2: Angiotensin Converting Enzyme 2; COVID-19: Coronavirus Disease 2019; FiO₂: Fraction of inspired oxygen; HbA_{1c}: Glycated Hemoglobin; ICU: Intensive Care Unit; PUI: Patient Under Investigation; RT-PCR: Reverse Transcription Polymerase Chain Reaction; SARS-CoV-2: Severe Acute Respiratory Syndrome Coronavirus 2

Introduction

The early confirmation of a COVID-19 diagnosis in suspected patients is a challenge with the backlog of SARS-CoV-2 RT-

PCR tests in various laboratories in South Africa. Although chest CT scans are favoured as a better radiological modality than plain chest radiographs for COVID-19, the latter may be the only tool accessible to most clinicians in most developing countries. A plain chest radiograph can assist in increasing the index of suspicion while RT-PCR results delay. Additionally, many lessons can be adopted from plain chest radiographs about SARS-CoV-2 and the lung as discussed on this article.

Material and method

We observed frequent similarities and differences on chest radiological findings from a total of 15 confirmed COVID-19



patients that correlated with clinical severity. We randomly selected 3 cases of COVID-19 with mild, moderate and severe disease to compare these radiological findings. We divided each lung field into apical, perihilar, peripheral or subpleural, and basal regions. We noted the distribution of pulmonary infiltrates on each plain chest radiograph, compared and correlated with among the 3 COVID-19 cases with different clinical severity.

Index cases

We discuss 3 confirmed cases of COVID-19 that presented to Tygerberg Hospital in the Western Cape, South Africa in April 2020. These were a 42 years old female, 56 years old male, and a 63 years old male with mild, moderate and severe clinical forms of disease respectively. They presented with clinical features on history and examination suggestive of COVID-19 hence they were subjected to testing. They all had a positive RT-PCR on a nasal swab. They had no previous lung pathology until the recent diagnosis of COVID-19. The 42 years old female was discharged after 1 day of admission and sent home for self-isolation. The 56 years old male with moderate disease recovered well after a week of supplementary oxygen that was initially at 40% FiO2 and weaned off slowly until his discharge.

The 62 years old male with the severe form of disease had a recent travel history to the United States. He had a medical history of diabetes mellitus with an HbA1C of 7.3% and hypertension without any target organ damage. On examination he had an increased abdominal circumference of >100 cm, and mild pedal edema. His vital signs were stable initially but complicated overnight developing a tachypnoea with oxygen saturations < 90% while on oxygen supplementation with FiO2 > 80%, and a sinus tachycardia. He was admitted to ICU for ventilatory support. He was mechanically ventilated for 2 weeks, and demised.

The chest radiological findings of these patients were ranging from clear to multifocal lung involvement (**Figure 1**). Of note is that the mild case of COVID-19 had a pristine chest radiograph. The moderate case, representing the majority of the cases that we see had the peripheral and basal regions of the lungs affected, with minimal involvement of the perihilar and apical regions of the lungs. The chest radiograph of the severe case taken while he was on mechanical ventilation revealed diffuse lung involvement bilaterally.

Discussion

SARS-CoV-2 virus has been identified to bind to the ACE2 receptors found in multiple organs including the lung. These receptors on the lung specifically were found to be concentrated in both type I and type II pneumocytes on the alveolar epithelia on immunostaining [1]. Therefore, the distribution of lung lesions on chest radiographs of COVID-19 patients is unlikely to be due to the distribution of ACE2 receptors which are evenly distributed on the lung parenchyma.

Normally and poorly aerated regions of the lung have been associated with early inflammation in porcine lungs with ventilator induced lung injury when compared with areas of tidal hyperinflation [2]. The regions of the lung that are said to be physiologically poorly aerated include the subpleural regions; seen as the peripheral region of the lung on chest radiographs and the bases. These regions participate partially during a normal tidal breath, and are only fully recruited during deep breathing, or with mechanical ventilation [3].

The clinical classification of COVID-19 ranges from mild to critical depending on presenting symptomatology and organ involvement. The degree of severity has been correlated with age and multiple co-morbid conditions [4]. Chest radiographical

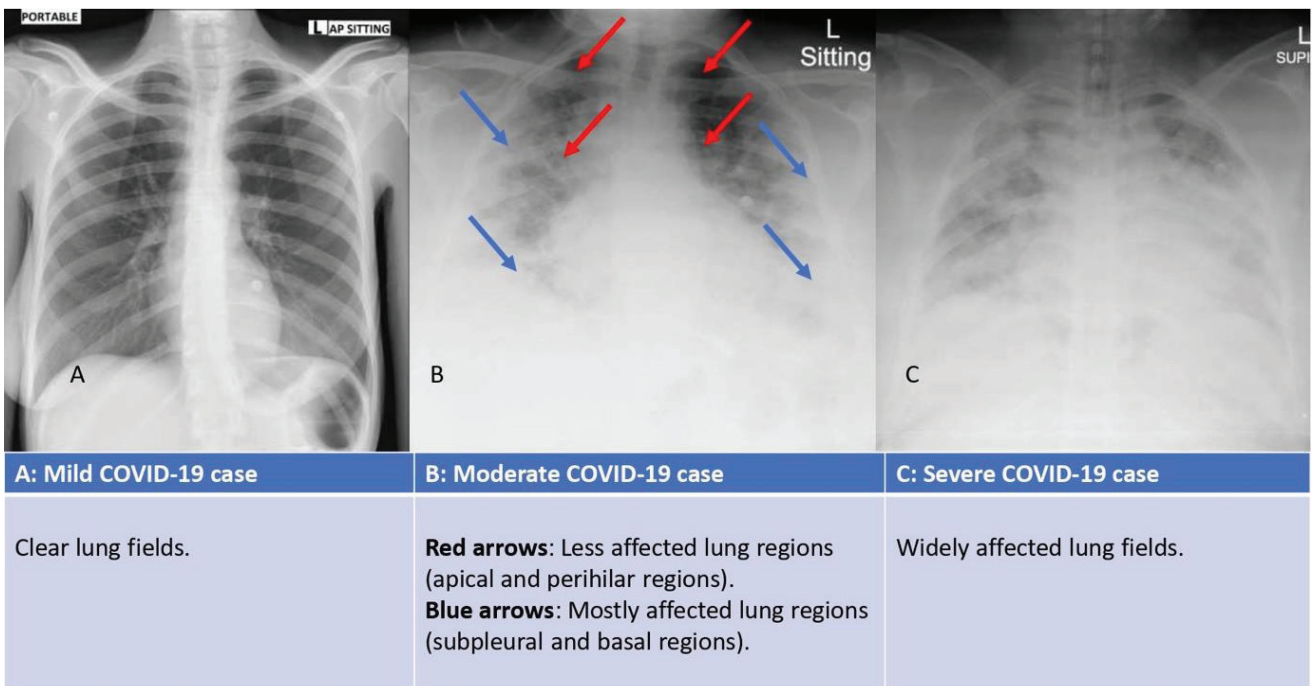


Figure 1: Plain chest radiographs of COVID-19 patients.



findings from confirmed and symptomatic patients with COVID-19 can range from being pristine as most studies have demonstrated so far, to mildly abnormal and severely abnormal. The most frequent findings are airspace opacities, described as consolidation or less commonly, ground glass opacities. The distribution is most often bilateral, subpleural and peripheral with a predominance of lower zone involvement especially the posterior segments [5]. The initial involvement is focal in approximately half of patients, multifocal in the remainder and between 6–12 days after onset of symptoms chest radiographical findings show multifocal involvement [6].

Conclusion

The distribution of the myriad radiological lesions on chest radiographs of COVID-19 patients have a common pattern of progression. Areas of the lung that are highly aerated such as the apical and the perihilar regions seem to be affected later on as the disease progresses. This finding may suggest pathophysiological relationship between the degree of lung aeration and SARS-CoV-2 infection. Early oxygen supplementation in mild disease might delay the progression towards a more severe subtype of COVID-19. Further studies need to be conducted to ascertain the significance of these observations and suggestions.

Learning points

Early plain chest radiographs may provide clues of COVID-19 infection before RT-PCR results are available in resource limited settings. This may help to expedite timeous isolation and contact tracing.

There may be a pathophysiological relationship between the SARS-CoV-2 viral spread on the lung parenchyma and the degree of lung parenchymal aeration. Poorly aerated regions of the lung seem to be affected early on in the disease course as seen on plain chest radiographs.

Early oxygen supplementation may delay or arrest the worsening of clinically mild COVID-19 cases.

References

1. Hamming I, Timens W, Bulthuis MLC, Lely AT, Navis NJ, et al. (2004) Tissue distribution of ACE2 protein the functional receptor for SARS coronavirus. A first step in understanding SARS pathogenesis. *J Pathol* 203: 631-637. [Link: https://bit.ly/3dmNxQH](https://bit.ly/3dmNxQH)
2. Borges JB, Costa ELV, Suarez-Sipmann F, Widström C, Larsoon A, et al. (2014) Early inflammation mainly affects normally and poorly aerated lung in experimental ventilator-induced lung injury. *Cri Care Med* 42: e279-e287. [Link: https://bit.ly/2Ni9e9V](https://bit.ly/2Ni9e9V)
3. Reber A, Engberg G, Wegenius G, Hedenstierna G (1996) Lung Aeration. The effect of pre-oxygenation and hyperoxygenation during total intravenous anesthesia. *Anaesthesia* 51: 733-737. [Link: https://bit.ly/2YXU4fy](https://bit.ly/2YXU4fy)
4. Huang C, Wang Y, Li X, Ren L, Zhao J, et al. (2020) Clinical features of patients infected with 2019 novel coronavirus in Wuhan, China. *Lancet* 395: 497-506. [Link: https://bit.ly/2NhrDbZ](https://bit.ly/2NhrDbZ)
5. Hosseiny M, Kooraki S, Gholamrezaezhad A, Reddy S, Myers L (2020) Radiology perspective on Coronavirus Disease 2019 (COVID-19): Lessons from severe acute respiratory syndrome and Middle East Respiratory Syndrome. *AJR Am J Roentgenol* 214: 1078-1082. [Link: https://bit.ly/3f0UA6r](https://bit.ly/3f0UA6r)
6. Wong KT, Antonia GE, Hui DS, Lee N, Yuen EHY, et al. (2003) Severe acute respiratory syndrome: radiographic appearances and pattern of progression in 138 patients. *Radiology* 228: 401-406. [Link: https://bit.ly/2B0z6V8](https://bit.ly/2B0z6V8)

Discover a bigger Impact and Visibility of your article publication with Peertechz Publications

Highlights

- ❖ Signatory publisher of ORCID
- ❖ Signatory Publisher of DORA (San Francisco Declaration on Research Assessment)
- ❖ Articles archived in worlds' renowned service providers such as Portico, CNKI, AGRIS, TDNet, Base (Bielefeld University Library), CrossRef, Scilit, J-Gate etc.
- ❖ Journals indexed in ICMJE, SHERPA/ROMEO, Google Scholar etc.
- ❖ OAI-PMH (Open Archives Initiative Protocol for Metadata Harvesting)
- ❖ Dedicated Editorial Board for every journal
- ❖ Accurate and rapid peer-review process
- ❖ Increased citations of published articles through promotions
- ❖ Reduced timeline for article publication

Submit your articles and experience a new surge in publication services (<https://www.peertechz.com/submit>).

Peertechz journals wishes everlasting success in your every endeavours.

Copyright: © 2020 Sibusiso N, et al. This is an open-access article distributed under the terms of the Creative Commons Attribution License, which permits unrestricted use, distribution, and reproduction in any medium, provided the original author and source are credited.

Citation: Sibusiso N, Tholakele S, Chizama M, Sthembiso S, Siphon N, et al. (2020) Lessons from COVID-19 plain chest radiographs on pathophysiology, early diagnosis and therapeutics. *Arch Pulmonol Respir Care* 6(1): 048-050. DOI: <https://dx.doi.org/10.17352/aprc.000052>