

Muhamad Abu-Hussein^{1*}, Nezar Watted² and Dror Shamir³

¹Department of Pediatric Dentistry, University of Athens, Greece

²University Hospital of Würzburg Clinics and Policlinics for Dental, Oral and Maxillofacial Diseases of the Bavarian Julius-Maximilian-University Würzburg, Germany and Center for Dentistry research and Aesthetics, Jatt, Israel

³Department Oral and Maxillofacial Surgery, Bnai Zion Medical Center, Haifa, Israel

Dates: Received: 21 June, 2016; Accepted: 07 July, 2016; Published: 09 July, 2016

*Corresponding author: Abu-Hussein Muhamad, DDS, MScD, MSc, M Dent Sci (Paed Dent), FICD, 123 Argus Street, 10441 Athens, Greece, E-mail: abuhusseinmuhamad@gmail.com

www.peertechz.com

ISSN: 2455-4634

Keywords: AL-Technology Implant; Single tooth replacement; Success rate

Research Article

A Retrospective Study of the AL Technology Implant System used for Single-Tooth Replacement

Abstract

Objective: The objective of this retrospective study was to evaluate the success rate of AL-Technology implants used for single tooth replacement after a minimum of three years of loading at Center for Dentistry, Research & Aesthetics, Jatt, Almothalath, Israel.

Method: Dental records for 43 patients who underwent single tooth replacement using AL-Technology implant system at Center for Dentistry, Research & Aesthetics, Jatt, Almothalath, Israel during a three years period (2010-2012) were retrospectively analyzed. Only implants that were functioning for at least three years were included.

Results: 152 AL-Technology implants were used for the replacement of single teeth in 43 patients, 114 (75%) implants were placed in the posterior regions, and 38 (25%) implants were placed in the anterior regions. All implants were restored with cement-retained crowns and have been in function for at least three years. Out of the total 152 implants, two (1,3%) were considered failures as a result of significant radiographic bone loss. Therefore, the survival rate at three years was 98,7%.

Conclusion: The results of this study suggested that AL-Technology implants could be a satisfactory choice for anterior and posterior single tooth restorations.

Introduction

The clinical success of dental implants is dependent on successful osseointegration. An important parameter for achieving osseointegration is the establishment of direct contact between the surface of the implant and the surrounding bone. There have been numerous studies indicating that implant surface roughness affects the rate of osseointegration [1-4].

Dental implants represent the state-of-the-art treatment for replacing single missing teeth, as demonstrated by several long-term follow-up studies, with satisfactory high survival rates [1-4]. However, biological and prosthetic complications still affect single crowns (SCs) supported by dental implants [2,5-10]. Biological complications include complications that affect only soft tissues (such as pain and swelling after surgery, or peri-implant mucositis) and complications that affect both soft and hard tissues (such as peri-implantitis) [5,6,10]. Prosthetic complications include mechanical complications (i.e. complications that affect prefabricated implant components, such as screw or abutment loosening, screw or abutment fracture) and technical complications (i.e. complications that affect superstructures, such as fracture/chipping of veneering materials and the need for recementation) [9-13].

In general, prosthetic complications, such as abutment screw loosening, loss of retention and fracture of the veneering material are the most frequent complications encountered [2,6-10,13-17]. Clinical studies on single-unit restorations have reported abutment screw loosening percentages between 5% and 48% [2,6-10,13-16]. These complications seem to affect mostly the posterior chewing, where the mechanical loads are higher [9,10,14-16].

Although abutment screw loosening may not lead to implant failure, it represents a problem, because it takes time to remove the crown and screw it again; moreover, where frequent, screw loosening may adversely affect the patient's satisfaction with the implant treatment [5,6,12,13]. Now-a-days, in fact, patients have high functional and esthetic expectations in relation to dental therapies [5]. Since patient satisfaction is a key, it is therefore very important to minimize the incidence of complications [5]. Screw loosening has been generally related to the type of implant/abutment connection used. Screw type connections, such as butt-joint indexed external or internal connections, are still the most commonly used in the market [14-16]. These connections are mainly stabilized by the axial preload of the abutment screw: as a consequence, optimum preload is critical for joint stability [14-16]. The stability of butt-joint connections can be challenged by occlusal loads: when these exceed the resistance of the torqued implant-abutment system, screw may lose or break [14-16]. In addition, screw loosening may occur as a result of fatigue, when lower masticatory forces, applied repeatedly, surpass the failure threshold of the assembly [14-16].

The objective of the present study was to evaluate the success rate of AL-Technology implants used for single-tooth replacement after a minimum of three years of loading at Center for Dentistry, Research & Aesthetics, Jatt, Almothalath, Israel.

Materials and Methods

All patients planned for replacement of missing teeth by dental implants were assessed clinically by our clinical team carefully before initiating their treatment. Patients were selected on the basis of the following inclusion criteria:

- Patient age \geq 19
 - o The presence of one or two missing teeth per edentulous space.
 - o Adjacent teeth structurally sound and esthetically acceptable to the patient.
 - o Maladaptive experience or refusal to wear a removable partial prosthesis or conventional bridges.
 - o Adequate interarch space for abutments, prosthetic components, and prosthesis.
 - o The vital anatomic structures are far away to the proposed implant site.
 - o Physically and psychologically able to tolerate conventional surgical and restorative procedures

Exclusion criteria

- Women who report a current pregnancy
 - o All patients with chronic diseases like uncontrolled diabetes or psychiatric illness.
 - o Unrealistic patient expectations of the treatment with respect to esthetic comfort and function.
 - o Insufficient bone dimension for implants.
- loss or damage of the buccal bone crest (>5 mm) after extraction of the failing tooth
- need for major bone augmentation procedures with autogenous bone or bone substitutes prior to implant insertion, to obtain an ideal position for the implant (although a minor augmentation procedure to cover exposed threads or interproximal/ buccal grafting owing to hard tissue deficiency was not an exclusion criterion)
- radiotherapy in the maxillofacial region
- treatment with intravenous amino-bisphosphonates
- chemotherapy
- parafunctions (bruxism or clenching)

Patients were seeking treatment to restore the missing teeth created by tooth loss resulting from caries, periodontics, endodontics complications, trauma, and congenital deficiency. The edentulous areas that were to receive the implants, as well as the adjacent structures, were evaluated using an appropriately prescribed combination of periapical, occlusal, panoramic radiographs. Before applying each implant, orthopantomogram was carried out for each patient, sometimes completed with intraoral x-ray images. In order to find out the thickness of alveolus, we made use of dental CT analysis or mapping the gingiva, using a hypodermic needle with a rubber disc. Most patients were instructed on dental hygiene. Recall examinations were carried out according to the previously published scheme.

Dental records for 43 patients who underwent single tooth replacement using AL-Technology implant system at Center for

Dentistry, Research & Aesthetics, Jatt, Almothalat, Israel during a four year period (2010-2012) were retrospectively analyzed. Only implants which were functioning for at least three years were included. For the objective of this study, the success rate was recorded according to the criteria suggested by Albredtsson et al., as follows: The unattached implant is immobile when tested clinically, no evidence of peri-implant radiolucency appeared radiographically, vertical bone loss is less than 0.2mm annually after the implants' first year of service, absence of persistent and/or irreversible signs and symptoms such as pain, infection, neuropathies, paresthesia, or violation of the mandibular canal [17].

The patients were recalled one week, four weeks, and eight weeks following screw implant insertion in the bone. The second stage started after eight weeks in order to fabricate the final prosthesis. After placement of final crowns, all patients were reviewed at two weeks, three weeks, and six months. The condition of the prosthesis, implant stability and adjacent mucosa were all evaluated at each recall appointment, patient symptoms were also recorded and used along with the clinical and radiographic signs to diagnose the implant status.

Success criteria

The following success criteria were applied in evaluating each implant: (1) No clinically detectable mobility when tested with opposing instrument pressure; (2) No evidence of peri implant radiolucency on periapical radiographs; (3) No recurrent or persistent peri-implant infection; (4) No pain at the site of treatment; (5) No neuropathies or paraesthesia; (6) Crestal bone loss not exceeding 1.5 mm by the end of the first year of functional loading, and less than 0.2 mm/year in the following years .[17]

Surgical procedures

AL-Technology implants were used in all cases. The length and the diameter of each implant were determined by bone quality and quantity at each surgical site. The surgical protocol required crestal implant placement, and following manufacturer's instructions. Primary stability was assessed using a torque wrench, based on Testori's scores.[18,19]

Prosthetic procedures

The treatment objective involved delivery of the provisional prosthesis within 4 hours of implant placement, by utilizing a prosthetic procedure that best fits the individual clinical condition.

The design of the prosthesis was determined by collaboration between the treating doctors, so it is consistent with the study's objectives. A metal reinforced acrylic provisional bridge was used for cement-retained restorations. A resin hybrid restoration was used for screw retained restorations. The occlusion was carefully adjusted.

Follow-up procedures

No specific diet was recommended to the patients. The patients were on a strict recall program during the first 6 months: every week during the first month, and every month between the second and sixth months. Panoramic radiographs and radiovisiography were obtained for image analysis immediately after implant placement, so per implant marginal bone changes can be recorded.

Study implants

AL-Technology was founded in 2001 as an association of mechanical engineers, dental technicians, experienced dentists and oral surgeons. The result of this combination of experience and knowledge are excellent dental products, particularly in the field of implantology. AL-Technology manufactured on modern and special CNC-controlled machines. The special shape of the implants, especially the conical offers easy implantation, maximum mechanical strength, stability immediately after implantation, and high bone integration.

The special treatment of the surface ((SLA: sand blasted, Large grit, Acid-etched), the special packaging of the implants in glass vials without plastics, in a sterile environment, guaranteed ALTechnology implants of excellent quality and the highest success rate. Implants material: Titanium alloy Ti-6Al-4V ELI, Grade-5. AL-Technology Dental Devices implants and abutments are made of titanium alloy Ti-6Al-4V ELI.

All implants used in the study are the AL-Technology implant system having a titanium-alloy threaded-body design with an internal connection feature. Implants were supplied in lengths of 8, 10, 11.5, and 13 mm and diameters of 3.3,3.75,4.2 and 5 mm.

Postoperative treatment

Ice packs were provided postoperatively. The patients were given anti-inflammatory and analgesic medication, consisting of 100 mg nimesulide every 12 h for 2 days. All patients received oral antibiotics, amoxicillin and clavulanic acid, 2 g each day for 6 days. Chlorhexidine 0.12% mouth rinses were prescribed for 2 weeks to enhance plaque control. Patients were instructed to eat a soft diet for 7 days and maintain daily hygiene after surgery. Smokers were told to avoid smoking for 48 h postoperatively. Patients were then observed after 2 weeks for a postoperative control and sutures were removed (if present).

Final restorative phase

After 3 months, the provisional restoration was replaced by a final restoration. Briefly, the final implant impression was made with individual trays using polyvinylsiloxane or polyether. A standard pre-fabricated titanium abutment was prepared, finished and tightened to 25 N/cm² torque. The final restorations comprised metal-ceramic crowns and zirconium-ceramic crowns, depending on patient requirements, which were screwed to the implants.

The occlusion was checked using standard occluding papers all final restorations were carefully evaluated for proper occlusion, and protrusion and laterotrusion were assessed on the articulator and also intraorally. The restorations needed to have occlusal surfaces similar to those of natural teeth, with occlusal contacts in maximum intercuspation and with functional contacts during lateral and protrusive excursions. Finally, an intraoral radiograph was made to check final restoration seating. Patients were included in a maintenance program to achieve optimal hard and soft tissue healing, which comprised professional oral hygiene every 6 months

Statistical analysis

Data analysis was performed by an independent investigator who was not directly involved in the study. Databases were created with Excel 2003 (Microsoft Excel; Microsoft Corporation, Redmond, WA, USA) and used for the analysis.

Results

Out of the total 43 patients, there were 29 females (67%) and 14 males (33%). The minimum age of the participants was 19 yrs, and the maximum age was 72 yrs 3 months (mean, 44,3 yrs). 7 patients were smokers. 152 single tooth implants were placed, 114 implants were placed in the posterior region, and 38 were placed in the anterior region. 59 implants were placed in the mandible (39%) and 93 implants were placed in the maxilla (61%). Data regarding the number of implants and duration of placement are presented in **Tables 1-3**.

All implants were restored with a cemented restoration using the solid conical abutment. The predominant type of implants placed was the solid screw. Regarding the length and diameter of the implants, 28 implants were 3,3 mm in diameter and 8,10,11.5, 13mm in length (18%), 91implants implants were 3,75 mm in diameter and 8,10,11,5,13mm in length(60%), 18 implants were 4,2 mm in diameter and 8,10,11,5, 13mm in length (12%), and 15 implants were 5mm in diameter and 8,10,11,5,13mm in length (10%) (**Table 1**), (**Figure 1**).

Two implants (1,3%) were considered as failures till the time of this report. One implant was lost while two implants exhibited significant bone loss. Radiographic failure was noted in one of the

Table 1: Implant distribution by length and diameters and the area of placement.

Diameter	Length/mm				No. of implants	%	Area of placement	
	8 mm	10 mm	11.5 mm	13 mm			anterior	posterior
3,3	2	4	11	11	28	18%	18	10
3,75	4	11	40	36	91	60%	16	75
4,2	4	4	5	5	18	12%	4	14
5,0	6	1	6	2	15	10%	0	15
					152	100%	38	114

Table 2: Number of implants and patients over 3 Years.

Year	implants	patients
2010	36	11
2011	52	15
2012	64	17
Total	152	43

Table 3: Number of implants max, and mand. (N=152).

N=152	amount	%
Max.	93	61%
Mand.	59	39%
Total	152	100%

mandibular sites (right first molar), and one of the implants (second right maxillary molar) was lost during abutment connection due to poor quality of bone at this site.

The results of this study revealed that the short-term survival rate of the 49 implants loaded for a minimum of three years was 98,7%. Two implants (1,3%) were considered failures; the reason for the first implant failure could be related to the quality of the bone since this implant was placed in the upper second molar region.

For placed implants' diameter, 28(18%) of 3.3 mm, 91(60%) of 3.75 mm, 18(12%) of 4.2mm, and 15(10%) of 5 mm were used. And for their length, 16 of 3.3 mm, 20 of 10.0 mm, 62 of 11.5 mm ,and 54 of 13mm were used (Table 1), (Figure 2).

Among the total 152 implants, the location implant maxillary were 6 (7%)implants central incisor, 14(15%) implants lateral incisors, 4 (4%)implants canine, 31(33%) implants premolar, and 38 (41%)implants molar. The location implants mandibular were 3(5%) implants central incisor, 5(8%) implants lateral incisors,6 (10%) implants canine, 24(41%) implants premolar, and 21(36%) implants molar (Tables 4-7).

From 152 implanys, 24 implanys were placed in anterior maxilla, 69 implants in the posterior maxilla, 14 implants in the anterior mandible, and 45 implants in the posterior mandibular, all implants included in the study had ISQ scores of at least 55 and an insertion torque of 35 N.cm on the day of the implant placement (Figures 3-5).

At the end of this study, an overall 3-year cumulative survival rate of 98.7% (patient-based) were reported, respectively. In the maxilla posterior zone, the cumulative survival rate was 99,65%, with

Table 4: Number of implants maxillary and mandibular.

Zone	Max.	Mand.	Total
anterior	24	14	38
posterior	69	45	114
Total	93	59	152

Table 5: The location of the max. Implants.

Central	lateral	canine	premolar	molar
6	14	4	31	38

Table 6: The location of the mand. Implants.

Central	lateral	canine	premolar	molar
3	5	6	24	21

Table 7: The location of the Implants maxillary and mandibular.

	Central	lateral	canine	premolar	molar
Max.	6	14	4	31	38
Mand.	3	5	6	24	21

1 failures. In the mandible posterior zone, the cumulative survival rate was 99,65%, with 1 failures. In aneroid zone maxillary and mandibular all implants were clinically stable and met the success criteria. The overall implant success rate was 100%.

Discussion

In dentistry, prosthetic treatment decisions are based on long-term considerations. Statements of the potential time of function must rely on results from long term studies. Thus, retrospective and prospective studies are, at this point, the most important sources of information for verification of the success or failure of tooth replacement.16 At the same time, reaction of the marginal periodontium and, in the case of endosseous implants, marginal bone resorption after prosthetic reconstruction, is well described in the literature [20-22].

Retrospective and prospective studies on single tooth replacement by implants are the most important source of information about this treatment modality. Results of these reports demonstrate a favorable survival rate and patient satisfaction when the AL-Technology implants was used to replace missing teeth [14,15].

The results of this study revealed that the short-term survival rate of the 49 implants loaded for a minimum of three years was 98,7%. Two implants (1,3%) were considered failures; the reason for the first implant failure could be related to the quality of the bone since this implant was placed in the upper second molar region. Although initially the peri- apical radiograph showed integration around all the implant surfaces, when abutment connection was done using torque device to tighten it in a 32 Ncm, the solid screw implant rotated with the device which necessitated its removal three days later. Cylindrical root-form dental implants are considered to be state-of-the-art implant dentistry. Advantages include adaptability to multiple intraoral locations, uniformly precise implant-site preparation, and comparatively low adverse consequences similar to that experienced

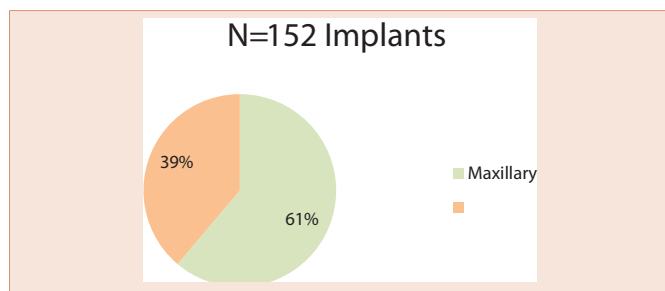


Figure 1: Number of implants max, and mand. (N=152).

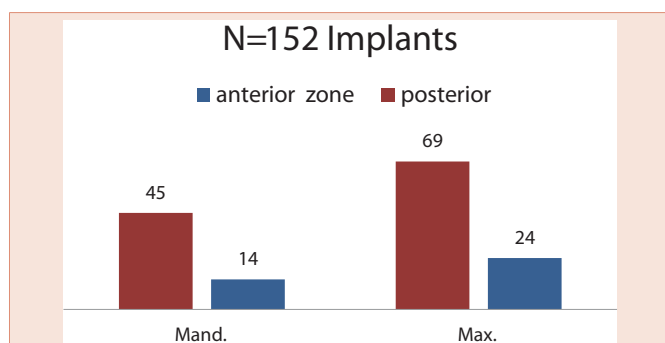


Figure 2: Number of implants maxillary and mandibular.

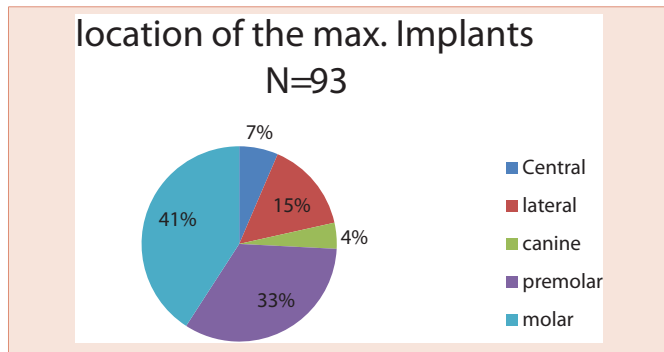


Figure 3: The location of the max. Implants.

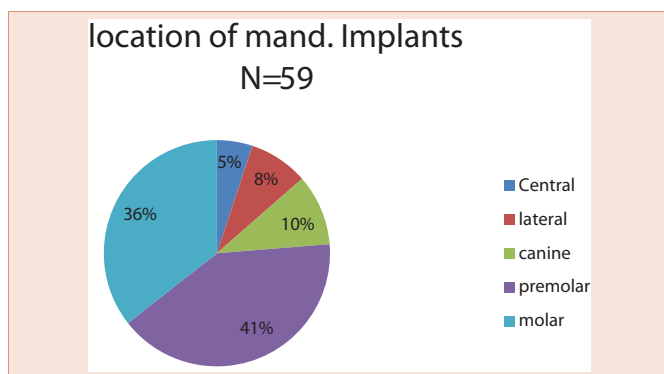


Figure 4: The location of the mand. Implants.

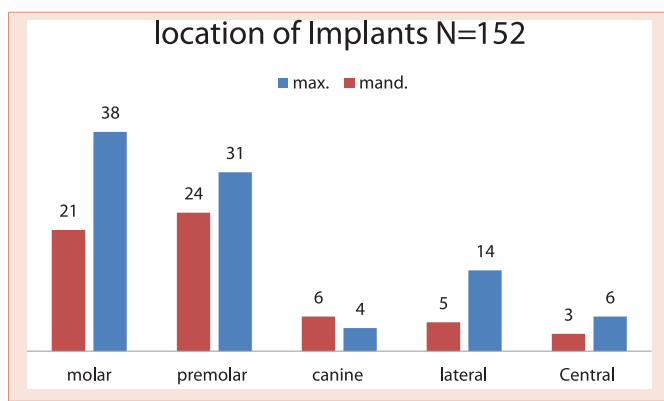


Figure 5: The location of the Implants maxillary and mandibular.

when a tooth is lost. Most root forms are made of titanium or titanium alloy with or without hydroxyapatite coating, materials that are perceived to have the highest bio functionality. Both threaded and non-threaded designs are available and are quite popular. Today many of the titanium implants are grit blasted or acid etched to roughen the surface and increase the area for bone contact [23,24].

The NIH consensus conference' in 1988 reported that root-form implants already constituted 78% of the implant market. This trend is credited to the Branemark system, which set the precedent for surgical techniques and restorative procedures that result in predictably successful implants. Two of the most important additions from the

Swedish research team, led by PI. Branemark, were atraumatic implant placement and delayed implant loading. These factors contributed to a remarkably increased degree of implant predictability. The original Branemark success rate of 91% in the mandible over 15 years' has become the benchmark by which other implant systems are judged." Many of the other root-form implant systems are also believed to have reached or exceeded this high level of long-term success [25].

Implant success reported from major research institutions is quite high. However, meticulous attention to the procedures of patient selection, diagnosis, and treatment planning is required to duplicate this success. Indications for dental implant treatment in the partially edentulous patient [23,24].

A combined surgical and restorative treatment plan must be devised for prospective implant patients. Feasible non implant alternatives should be included in the overall treatment discussions. Patients need to be evaluated preoperatively and assessed as to whether they will be able to tolerate the procedure. The predictable risks and expected benefits should be weighed for each person. Although the placement of dental implants does entail some risks, they are relatively minor. Absolute contraindications, based on immediate surgical and anesthetic risks, are limited to individuals who are acutely ill, individuals with uncontrolled metabolic disease, and pregnant women (contraindications that apply to virtually all elective surgical procedures) [23-27].

Evaluation of the planned implant site begins with a thorough clinical examination. This examination will determine whether there is adequate bone and will identify anatomic structures that could interfere with ideal implant placement. Visual inspection and palpation allow the detection of flabby excess tissue, bony ridges, and sharp underlying osseous formations and undercuts that would limit implant insertion. However, clinical inspection alone may not be adequate if there is thick overlying soft tissue that is dense, immobile, and fibrous [15-17,23,24].

To maximize the chance of success, the implant should be placed entirely within bone and away from significant anatomic structures (e.g., the inferior alveolar canal). Ideally, 10 mm of vertical bone dimension and 6 mm of horizontal should be available for implant placement. These dimensions will prevent encroachment on anatomic structures and allow 1.0 mm of bone on both the lingual and the facial aspect of the implant. There should also be adequate space between adjacent implants [24]. The minimum recommended distance varies slightly among implant systems but is generally accepted as 3.0 mm. This space is needed to ensure bone viability between the implants and to allow adequate oral hygiene once the restorative dentistry is complete. Specific limitations due to anatomic variations among different areas of the jaws also must be considered. These include implant length, diameter, proximity to adjacent structures, and time required for integration [23,24].

The anterior maxilla, posterior maxilla, anterior mandible, and posterior mandible each require special considerations in placing implants. Some common guidelines include staying 2.0 mm above the superior aspect of the inferior alveolar canal, 5.0 mm anterior to the mental foramen, and 1.0 mm from the periodontal ligament of adjacent natural teeth [28].

Anterior Maxilla: The anterior maxilla must be evaluated for proximity to the nasal cavity. A minimum of 1.0 mm of bone should remain between the apex of the implant and the nasal vestibule. Due to resorption of the anterior maxilla, the incisive foramen may be located near the residual ridge, especially in patients whose edentulous maxilla has been allowed to function against a natural mandibular anterior dentition. Anterior maxillary implants should be located slightly off midline, on either side of the incisive foramen [10,11,14,15,24].

Posterior Maxilla: Implant placement in the posterior maxilla poses two specific concerns: First, the bone of the posterior maxilla is less dense than that of the posterior mandible. It has larger marrow spaces and a thinner cortex, which can affect treatment planning, since increased time must be allowed for integration of the implants and additional implants may be needed. A minimum of 6 months is usually needed for adequate integration of implants placed in the maxilla. In addition, one implant for every tooth that is being replaced is normally recommended, especially in the posterior maxilla [10,11,24].

The second concern is that the maxillary sinus is close to the edentulous ridge in the posterior maxilla. Frequently, because of the resorption of bone and increased pneumatization of the sinus, only a few millimeters of bone remain between the ridge and the sinus. In treatment planning for implants in the posterior maxilla, the surgeon should leave 1.0 mm of bone between the floor of the sinus and the implant so the implant can be anchored apically into cortical bone of the sinus floor.

Adequate bone height for implant stability can usually be found between the nasal cavity and the maxillary sinus. If there is not adequate bone for implant placement and support, bony augmentation through the sinus should be considered [10,11,24].

Anterior Mandible: With respect to anatomic limitations, the anterior mandible is usually the most straightforward area for treatment planning. It usually has adequate height and width for implant placement, and the bone quality is normally excellent, which makes it require the least amount of time for integration. Some success with immediate loading of implants in the anterior mandible has even been reported.

When possible, an implant in the anterior mandible should be placed through the entire cancellous bone so the apex of the implant will engage the cortex of the inferior mandibular border [14].

In the premolar area, care must be taken that the implant does not impinge on the inferior dental nerve. Since this nerve courses as much as 3.0 mm anterior to the mental foramen before turning posteriorly and superiorly to exit at the foramen, an implant should be at least 5.0 mm anterior to the foramen [10,11,24].

Posterior Mandible: The posterior mandible poses some limitations on implant placement. The inferior alveolar nerve traverses the mandibular body in this region, and treatment planning must allow for a 2.0-mm margin from the apex of the implant to the superior aspect of the inferior alveolar canal. This is an important guideline: disregarding it can cause damage to the nerve

and numbness of the lower lip. If adequate length is not present for even the shortest implant, nerve repositioning, on lay grafting, or a conventional nonimplant-borne prosthesis must be considered.

Implants placed in the posterior mandible are usually shorter, do not engage cortical bone inferiorly, and must support increased biomechanical occlusal forces once they are loaded due to their location in the posterior area. Consequently, allowing slightly more time for integration may be beneficial [10,11,24].

In addition, if short implants (8 to 10 mm) are used, “over engineering” and placing more implants than usual to withstand the occlusal load is recommended.

Short implants are often necessary because of bone resorption, thus increasing the crown-to-implant ratio when the normal plane of occlusion is reestablished [14-17].

Albrektsson in a study reported gingival complications in the form of mucosal perforations and fistulae showed an incidence of 38 to 39 observations in 11 team study. Mechanical complications such as fracture of abutment screw, fixture, or prosthesis was reported to occur in 3 to 5 % of the cases [29].

G.A. Zarb and Schmitt reported that Osseo integrated implant is a predictably safe analogue for tooth root, capable of supporting prostheses in edentulous jaws [30].

Zarb and Schmitt reported salient aspects which impact upon decision making with implant supported prosthesis. He emphasizes the predominance of bone structure in selecting the most likely favorable treatment outcome [31].

D. van Steenberghe did a retrospective multicenter evaluation of survival rate of osseointegrated fixtures supporting fixed partial prostheses in the treatment of partial edentulism. The most failures occurred before prosthetic rehabilitation. The mean maximum between the margin of the bone and the fixture abutment junction was 2.5 mm. Since only two of the 53 fixed prostheses were lost during observation period and since most fixture losses occurred before prosthetic phase of the treatment this study supports the concept that osseointegrated prostheses can also be applied in the rehabilitation of partial edentulism [32].

Lars W. Lindquist et al., reported that bone loss around Osseo integrated titanium fixtures supporting mandibular fixed prostheses has been measured by means of stereoscopic intraoral radiography. The bone loss was small; during first post-surgical year. Poor oral hygiene and clenching of teeth significantly influenced bone loss [33].

Ann M. Parein et al., evaluated the long term outcome the type and prevalence of prosthetic complications in a series of patients treated consecutively with Branemark implants in the partially edentulous mandible. Significantly fewer major complications were found in prostheses supported by one or more implants, located exclusively in premolar sites, versus prostheses supported by either molar implant or both premolar and molar implants. In single tooth restorations fewer major complications were seen in the cemented restorations, compared with screw retained [34].

Esposito M, Hirsch J-M, Lekholm U, Thomsen p have presented review regarding factors associated with the loss of oral

implant. The review identifies following factors – medical status of patients, smoking, bone quality, bone grafting, irradiation therapy, parafunction, operator experience, degree of surgical trauma, bacterial contamination, lack of preoperative antibiotic, immediate loading, non-submerged procedure, number of implant supporting a prosthesis, implant surface characteristic and design [35].

Charles J. Goodarce reported that following 6 categories of clinical complications are associated with implant prosthesis: surgical, implant loss, bone loss, peri implant soft tissue complication, mechanical complication, and esthetic/phonetic complication. The most common is surgical complication [36].

John C. Keller has reported that osteoporosis like bone conditions affects the Osseo integration characteristic of implant, but long term biomechanical stability under forces of mastication is unknown as yet [37].

Marco Esposito et al reported implant with relatively smooth (turned) surface is less prone to lose bone due to chronic infection (Perimplantitis) than with the rougher surface.

Levin L, Hertzberg R, Har-Nes S, Schwartz-Arad D reported Long term marginal bone loss around single dental implants affected by current and past smoking habits. Former smokers still demonstrated an increase in marginal bone loss as compared with nonsmokers. There was no difference in implant survival in relation to smoking habits [38].

Claudia cristina Montes reported that most patients presented no clinical cause for implant failure. These result suggested that host factor, not clinically identified clinically, can contribute to an increased risk for implant loss [39].

Periklis Proussaefs et al., evaluated the clinical parameters of immediately loaded single threaded hydroxyapatite coated root form implants. He concluded that single root form implants may be immediately loaded when placed in the maxillary premolar region [40].

Jemt et al., is the location of the implant placement. In their study, no maxillary molars were included, and only five mandibular molars at one year with three mandibular molars at three years examination were included [41].

The present study revealed successful treatment with short implant (10mm or less) since they represent all of the implants. Balshi has suggested avoiding short implants (13mm and shorter) posteriorly and recommended the placement of two implants whenever possible for single-molar replacement to better withstand heavy occlusal loading seen in molar areas [22].

Rangert and Sullivan have also reported the fracture of a 3.75mm wide implant resulting from bending movement when one implant is used to replace a single molar. Based on the short-term data of this study using titanium single stage ITI implants, initial findings do not support this suggestion, considering that 34.6% of all implants were placed in molar regions with minimal restoration problems and no complications or implant fracture [42].

Fumihiko Watanabe et al reported that an implant was placed in an incorrect inclination in spite of cooperation between the surgeon

and Prosthodontist. This failure suggested the necessity of clearly presenting the Prosthodontic aspect of treatment to each member of the team before surgical treatment is rendered [43].

W.Chee and S. Jivraj reported most of implant failure can be prevented with proper patient selection and treatment planning [44].

Wael Att et al concluded that when planning dental treatment, practitioner need to consider patient's wishes and requirement [45].

Failure of implant has a multifactor dimension. Often many factors come together to cause the ultimate failure of the implant. One needs to identify the cause not just to treat the present condition but also as a learning experience for future treatments.

These short-term data suggest that the application of AL-Technology implants can be a valid choice for posterior single tooth replacement as well as for anterior single tooth replacement.

Conclusion

The studies reviewed report survival rates from 93.09 to 100 percent. Several review articles also suggest that regardless of surface treatments, most implants on the market are comparable to each other. There is no clear indication that dental implants with a specific morphological characteristic provide any benefits over implants with a different structure. Very minor differences exist in the performance of various implant surface types. Ongoing efforts in the development of surface technology are aimed at enhancing tissue-surface interactions and healing response, with the ultimate goal of improving patient care.

The use of AL-Technology implant system to support fixed crowns appears to be a highly successful treatment alternative for restoration of the partially edentulous patient. Satisfactory treatment outcomes are possible for a broad range of patient as documented in this study. AL-Technology implants could be a satisfactory choice for anterior and posterior single tooth restorations with survival rate at three years was 98.7%.

Disclosure policy

The authors declare no conflict of interest regarding the publication of this paper.

References

1. Dierens M, Vandeweghe S, Kisch J, Nilner K, De Bruyn H (2012) Long-term follow-up of turned single implants placed in periodontally healthy patients after 16-22 years: radiographic and peri-implant outcome. *Clin Oral Implants Res* 23: 197-204.
2. Camargos GDe V, do Prado CJ, das Neves FD, Sartori IA (2012) Clinical outcomes of single dental implants with external connections: results after 2 to 13 years. *Int J Oral Maxillofac Implants* 27: 935-944.
3. Sesma N, Pannuti C, Cardaropoli G (2012) Retrospective clinical study of 988 dual acid-etched implants placed in grafted and native bone for single-tooth replacement. *Int J Oral Maxillofac Implants* 27: 1243-1248.
4. Mozzati M, Gallesio G, Del Fabbro M (2015) Long-term (9-12 years) outcomes of titanium implants with an oxidized surface: a retrospective investigation on 209 implants. *J Oral Implantol* 41: 437-443.
5. Pjetursson BE, Asgeirsson AG, Zwahlen M, Sailer I (2014) Improvements in implant dentistry over the last decade: comparison of survival and complication rates in older and newer publications. *Int J Oral Maxillofac Implants* 29: 308-324.

6. Bragger U, Karoussis I, Persson R, Pjetursson B, Salvi G, et al. (2005) Technical and biological complications/failures with single crowns and fixed partial dentures on implants: a 10-year prospective cohort study. *Clin Oral Implants Res* 16: 326-334.
7. Dierens M, De Bruyn H, Kisch J, Nilner K, Cosyn J, et al. (2014) Prosthetic Survival and Complication Rate of Single Implant Treatment in the Periodontally Healthy Patient after 16 to 22 Years of Follow-Up. *Clin Implant Dent Rel Res* 18: 117-128.
8. Wittneben JG, Buser D, Salvi GE, Burgin W, Hicklin S, et al. (2014) Complication and failure rates with implant-supported fixed dental prostheses and single crowns: a 10- year retrospective study. *Clin Implant Dent Relat Res* 16: 356-364.
9. Walton TR (2015) An Up-to-15-Year Comparison of the Survival and Complication Burden of Three-Unit Tooth-Supported Fixed Dental Prostheses and Implant-Supported Single Crowns. *Int J Oral Maxillofac Implants* 30: 851-861.
10. Rinke S, Roediger M, Eickholz P, Lange K, Ziebolz D (2015) Technical and biological complications of single-molar implant restorations. *Clin Oral Implants Res* 26: 1024-1030.
11. Salvi GE, Bragger U (2009) Mechanical and technical risks in implant therapy. *Int J Oral Maxillofac Implants* 24: 69-85.
12. Jung RE, Zembic A, Pjetursson BE, Zwahlen M, Thoma DS (2012) Systematic review of the survival rate and the incidence of biological, technical, and aesthetic complications of single crowns on implants reported in longitudinal studies with a mean follow-up of 5 years. *Clin Oral Implants Res* 23: 2-21.
13. Zembic A, Kim S, Zwahlen M, Kelly JR (2014) Systematic review of the survival rate and incidence of biologic, technical, and esthetic complications of single implant abutments supporting fixed prostheses. *Int J Oral Maxillofac Implants* 29: 99-116.
14. Abu-Hussein M, Azzaldeen A, Aspasia SA, Nikos K (2013) Implants into fresh extraction site: A literature review, case immediate placement report. *J Dent Implant* 3: 160-164.
15. Abdulgani A, Kontoes N, Chlorokostas G, Abu-Hussein M (2015) Interdisciplinary Management Of Maxillary Lateral Incisors Agenesis With Mini Implant Prostheses: A Case Report. *IOSR-JDMS*14: 36-42.
16. Abu-Hussein M, Abdulgani A, Watted N, Zahalka M (2015) Congenitally Missing Lateral Incisor with Orthodontics, Bone Grafting and Ingle-Tooth Implant: A Case Report. *J Dent Med Scie* 14: 124-130.
17. Albrektsson T, Zarb G, Worthington P, Eriksson AR (1986) The long-term efficacy of currently used dental implants: A review and proposed criteria of success. *Int J Oral Maxillofac Implants* 1: 11-25.
18. Testori T, Wiseman L, Woolfe S, Porter SS (2001) A prospective multicenter clinical study of the Osseotite implant: four-year interim report. *Int J Oral Maxillofac Implants* 16: 193-200.
19. Testori T, Del Fabbro M, Feldman S, Vincenzi G, Sullivan D, et al. (2002) A multicenter prospective evaluation of 2-months Osseotites implants placed in the posterior jaws: 3-year follow-up results. *Clin Oral Implants Res* 13: 154-161.
20. Branemark PI (1959) Vital microscopy of bone marrow in rabbit. *Scand J Clin Lab Invest* 11: 1-82.
21. Branemark PI (1983) Osseointegration and its experimental studies. *J Prosthet Dent* 50: 399-410.
22. Balshi TJ (1994) Candidates and Requirements for single tooth implant prostheses. *Int J Periodont Rest Dent* 14: 316-331.
23. McGlumphy EA, Larsen PE (1998) Contemporary implant dentistry. In Peterson LJ et al, editors: Contemporary oral and maxillofacial surgery, ed 3, St Louis, Mosby.
24. Misch CE (2006) Dental Implant Prosthetics. St Louis: Mosby.
25. (1988) NIH Consensus Development Conference Statement on dental implants June 13-15, 1988. *J Dent Educ* 52: 824-827.
26. Abusalih A, Ismail H, Abdulgani A, Chlorokostas G, Abu-Hussein M (2016) Interdisciplinary Management of Congenitally Agenesis Maxillary Lateral Incisors: Orthodontic/Prosthodontic Perspectives, *Journal of Dental and Medical Sciences* 15: 90-99.
27. Romeo E, Tomasi C, Finini I, Casentini P, Lops D (2009) Implant-supported fixed cantilever prosthesis in partially edentulous jaws: a cohort prospective study. *Clin Oral Implants Res* 20: 1278-1285.
28. Belser UC, Grutter L, Vailati F, Bornstein MM, Weber HP, et al. (2009) Outcome evaluation of early placed maxillary anterior single-tooth implants using objective esthetic criteria: a cross-sectional, retrospective study in 45 patients with a 2- to 4-year follow-up using pink and white esthetic scores. *J Periodontol* 80: 140-151.
29. Albrektsson T (1998) A multicenter report on osseointegrated oral implants. *J Prosthet Dent* 60: 75-84
30. Zarb GA, Schmitt A (1990) The longitudinal clinical effectiveness of Osseointegrated dental implants: The Toronto study. Part I: Surgical results. *J Prosthet Dent* 63: 451-457.
31. Abu-Hussein M, Watted N (2015) Congenitally Missing Upper Laterals. Clinical Considerations: Orthodontic Space Closure. *Int Res Pub Med Sci* 1: 82-89.
32. D van Steenburghe (1989) A retrospective multicenter evaluation or survival rate of osseointegrated fixtures supporting fixed partial denture prosthesis in the treatment of partial edentulism. *J Prosthet Dent* 61: 217-223.
33. Lindquist LW, Rockler B, Carlsson GE (1988) Bone resorption around fixtures in edentulous patients treated with mandibular fixed tissue- integrated prostheses. *J Prosthetic Dent* 59: 59-63.
34. Parein AM, Eckert SE, Wollan PC, Keller EE (1997) Implant reconstruction in the posterior mandible: A long term retrospective study. *J Prosthet Dent* 78: 34-42.
35. Esposito M, Hirsch JM, Lekholm U, Thomsen P (1998) Biological factors contributing to failures of osseointegrated oral implants. (II) Etiopathogenesis. *Eur J Oral Set* 106: 721-764.
36. Goodacre CJ, Bernal G, Rungcharassaeng K, Kan JY (2003) Clinical complications with implants and implant prostheses. *J Prosthet Dent* 90: 121-132.
37. Keller JC, Stewart M, Roehm M, Schneider GB (2004) Osteoporosis-like Bone conditions affect osseointegration of implants. *Int J Oral Maxillofac Implants* 19: 687-694.
38. Levin L, Hertzberg R, Har-Nes S, Schwartz-Arad D (2008) Long-term marginal bone loss around single dental implants affected by current and past smoking habits. *Implant Dent* 17: 422-429.
39. Montes CC, Pereira FA, Thomé G, Alves ED, Acedo RV, et al. (2007) Failing factors associated with osseointegrated dental implant loss. *Implant dentistry* 16: 404-412.
40. Proussaefs P, Lozada J (2004) Immediate loading of hydroxyapatite-coated implants in maxillary premolar area: Three year results of a pilot study. *J Prosthet Dent* 91: 228-233.
41. Jemt T, Linden B, Lekholm U (1992) Failures and complications in 127 consecutively placed fixed partial prostheses supported by Branemark implants: From prosthetic treatment to first annual checkup. *Int J Oral Maxillofac Implant* 7: 40-44.
42. Rangert B, Sullivan R (1993) Preventing prosthetic over load induced by bending. *Nobel Pharma News* 7: 6.
43. Watanabe F, Hata Y, Mataga I, Yoshie S (2002) Retrieval and replacement of a malpositioned dental implant: A clinical report. *J. Prosthet Dent* 8: 255-258.
44. Chee W, Jivraj S (2007) Failures in implant dentistry. *Br Dent J* 202: 123-129.
45. Att W, Stappert C (2003) Implant therapy to improve quality of life. *Quintessence int* 34: 573-581.

Copyright: © 2016 Abu-Hussein M, et al. This is an open-access article distributed under the terms of the Creative Commons Attribution License, which permits unrestricted use, distribution, and reproduction in any medium, provided the original author and source are credited.

Citation: Abu-Hussein M, Watted N, Shamir D (2016) A Retrospective Study of the AL Technology Implant System used for Single-Tooth Replacement. *Int J Oral Craniofac Sci* 2(2): 039-046. DOI: 10.17352/2455-4634.000017