



## Review Article

# Principles and concepts of occlusion in restorative dentistry

Nafeesa Qureshi<sup>1\*</sup> and Zahid Imran<sup>2</sup>

<sup>1</sup>Associate Dentist, City Quay Dental Practice and Implant Centre, Dundee, DD1 3JA, United Kingdom

<sup>2</sup>Dental Surgeon, Kings Cross Hospital, Dundee, United Kingdom

Received: 03 March, 2023

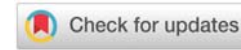
Accepted: 03 April, 2023

Published: 04 April, 2023

\*Corresponding author: Dr. Nafeesa Qureshi, Associate Dentist, City Quay Dental Practice and Implant Centre, Dundee, DD1 3JA, United Kingdom, E-mail: [nafeesa.qureshi@nhs.scot](mailto:nafeesa.qureshi@nhs.scot)

Copyright License: © 2023 Qureshi N, et al. This is an open-access article distributed under the terms of the Creative Commons Attribution License, which permits unrestricted use, distribution, and reproduction in any medium, provided the original author and source are credited.

<https://www.peertechzpublications.com>



## Abstract

The importance of occlusion to practicing dentists is immense as it plays a key role in the success or failure of restorative procedures. This article attempts to demystify and present an overview of the complex topic of occlusion and its principles which are important for the success of restorative procedures. The article discusses the principles of occlusion as these apply to restorative dentistry. It provides a guide as to what is required to optimize the occlusion for restorative treatment outcomes, including conformative and reorganized approaches. Occlusion and its effect on the temporomandibular joint are also presented. The topic is clinically relevant as it will help the practitioners to understand the key concepts of occlusion and help improve the outcome of their restorative dental procedures.

## Introduction

Occlusion may be defined as the way the teeth meet when the mandible and maxilla come together. It is the way teeth contact in any type of functional relationship. Occlusion when working optimally allows oral functions to operate properly, provides the best aesthetics, and helps in preventing any derangements of oral function [1].

Dental occlusion has been described to be much more than the physical contact of the biting surfaces of opposing teeth or replacements like dentures, crowns, or bridges. Occlusion has been defined more comprehensively and biologically as “the coordinated functional interaction between the various cell populations forming the masticatory system as they differentiate, model, remodel, fail, and repair. Morphologic variations are very common and represent the norm” [2].

The range of opinions about the importance of occlusion is enormous within the dental profession. It is very important to have a balanced view of occlusion by all practicing dentists. The study of occlusion is characterised by extremes of views which makes it confusing and difficult for individual dentists to agree with an evidence-based philosophy in line with contemporary good practice [2].

On the contrary, there is a body of opinion that cogitates

occlusion to be a central pillar, and very important for the well-being of our patients. For some occlusion takes on almost a mystic importance and attracts a cult-like devotion [2]. The danger is that both of these approaches lead to inappropriate levels of patient care; patients suffer either over or under-treatment.

In the study of occlusion, there is a need for continuing education and improvement of skills, consideration has to be given to a comprehensive study of occlusion and its impact on the masticatory system as the mandatory element of dental education both at the undergraduate and postgraduate level. It may not be the first thing to be learned, but it is not less important than the other parts of the masticatory system.

## Principles of occlusion

There are 5 principles of occlusion that are essential to keep under consideration when carrying out restorative dental procedures. These are essential for understanding the requirements for long-term occlusion stability and also recognise any instability in occlusion. The aim is to use these principles to carry out an occlusal analysis and design the occlusion in such a way as to reduce stress on the masticatory system including the muscles of mastication, teeth, periodontium, Temporomandibular Joint (TMJ) and on the restorations that are placed for the patient. These principles of

occlusion include:

1. Retruded Axis Position (RAP) or Centric Relation (CR)  
[Retruded Contact Position (RCP) = Inter Cuspal Position (ICP) around RAP]
2. Mutually protected occlusion
3. The importance of anterior guidance
4. Non-working side interferences
5. Posterior stability

At least three of them involve anterior tooth contact; mutually protected occlusion, anterior guidance no non-working side or balancing side contacts. If the anterior tooth contacts are lost, that can be very detrimental for the patient.

### 1. RCP = ICP around RAP

Our current understanding is that RAP is a three-dimensional position, it is described as the rearmost, uppermost, and midmost (RUM) position of the condyles in the glenoid fossa in the temporal bone. While there is an ongoing discussion amongst various groups of experts about the exact definition of RAP, it is generally accepted that the RAP is a reproducible and braced position, when the muscular apparatus is relaxed and it is an area, not a pinpoint position. It's a position of the condyle in the glenoid fossa and it has nothing to do with teeth, it's a position of the mandible to the maxilla, and it is the best possible position of condyle before one can start restorative dentistry. RAP is a stable position, a muscular relaxed position, a bone brace position and it's the ideal starting point and a gateway to good advanced restorative dentistry [3].

The RCP is the first point of contact between the maxillary and mandibular teeth when the patient closes his/her mouth with condyles in RAP. Roughly 10% of patients close directly into ICP when the condyles are in RAP. In the remaining 90% of the population maximum intercuspation occurs slightly forward from the retruded position of the mandible to the maxilla. However, contact between opposing teeth and the resultant proprioceptive response guides the mandible repeatedly into the habitual ICP, so there is a slide from RCP to ICP [4].

### 2. Mutually protected occlusion and anterior guidance

In maximum intercuspation, the posterior teeth protect the anterior teeth, in protrusion the anterior teeth contact with incisal edges protecting the canines and the posterior teeth which have no contact. In lateral movement upper and lower canines contact with each other protecting the anterior and posterior teeth i.e. there is no contact between the anterior and posterior teeth [5].

The vertical loading force is taken up by posterior teeth and during this process, the anterior teeth are protected and the horizontal force is taken up by anterior teeth and in this

process, posterior teeth are protected. Anterior teeth are not designed to take a vertical load [6].

The biting force of 30 pounds/ inch is involved in the normal chewing process as during the daytime proprioception prevents this force to increase beyond this limit. During the night time due to a lack of proprioception, the biting force can increase to 300 pounds/inch which causes severe attrition, cracked teeth and restorations, and TMD in bruxists [7]. This can be prevented by using a Michigan splint, a Tanner splint, etc.

### 3. The importance of anterior guidance

The anterior teeth have a unique relation to the fulcrum of the temporomandibular joint (TMJ) this helps to protect the posterior teeth when in function. The anterior guidance takes on a key role in taming the muscle forces and has the ability to reduce the elevator muscle activity when the jaw is in an excursive position.

When the anterior guidance is in harmony with the function of teeth and the muscular apparatus, then it is in harmony with the "Envelope of Function". The anterior guidance is created by the contact between the mandibular anterior teeth and the lingual surfaces of the maxillary anterior teeth, with a resulting non-interference with the movements of the patient's mandible in function.

Keeping this in mind, when designing occlusal schemes and solving occlusal problems, the establishment of acceptable anterior guidance would be the key initial step that must be taken.

### 4. Nonworking side contacts (interferences)

Normally in a lateral excursion, the nonworking side has no tooth contacts. If the teeth on the non-working side make the first contact this is considered to be non-working side interference. In case opposing teeth need restoring, this should be kept in mind when recreating the occlusal anatomy to avoid introducing an occlusal disharmony which could lead to a range of temporomandibular problems i.e. clicking or muscle pain, etc. For example, in case a lower left second premolar is extracted, the lower left first molar inclines lingually and mesially thus changing the occlusion and causing occlusal interference [8].

### 5. Posterior stability

While restoring a posterior tooth the occlusal anatomy of the teeth should be recreated to copy the morphology of the neighbouring teeth. For maxillary posterior teeth, the buccal incline of palatal cusps can be adjusted. For the mandibular posterior teeth, the palatal incline of buccal cusps can be adjusted [9]. The occlusal stability of the posterior teeth is important in enabling the masticatory system in meeting its functional demands [10].

Difference between gnathology and Pankey Mann Schuyler's (PMS) theory of occlusion [11].

1. There is a belief among Gnathologists that, condyles positioned in retruded axis position and any movement out of this position should dis-occlude the posterior segment, this nullifies any horizontal cusp-fossae area contact.
2. This belief, in combination with the resultant immediate anterior dis-occlusion, forms the basis of a mutually protected occlusion and helps in limiting tooth wear. The PMS occlusal scheme, however, encourages multiple occlusal contacts during lateral movements (group function or wide center) and protrusive movements (long-centric).
3. The PMS occlusal scheme may have the effect of increasing tooth wear. This occlusal scheme recommends that occlusal wear is physiological, not pathological as suggested by gnathologists. Adjustment of the maximum intercuspation contacts at two different locations on an articulator may result in a lack of precision in both locations. However, it is believed that the masticatory system has the ability to adapt to various influences and that the concept of gnathology will produce stable long-term results, some patients may require more freedom in their occlusion and the PMS concepts are not to be dismissed in these cases. Certainly, some PMS occlusal concepts such as waxing up the curve of Spee and the curve of Monson before occlusal rehabilitation are incorporated into everyday occlusal practice.

### Recording Retruded Axis Position (RAP)

Procedure for recording RAP. First of all, the patient needs to be lying down flat on the dental chair also the chin is up in the air. The patient's head should be positioned at the level of the clinician's tummy. Clinician also has to consider hand and finger position. Clinician has to put his thumbs on the symphysis approximately 1 cm apart, three fingers are then placed onto the Bony part of the mandible on both sides. It's to be made sure that the fingers are bent and not squeezing the soft tissues, also needs to make sure that this is comfortable for the patient. Also, it's to be made sure the arms are creating unnecessary excessive force. Next, the aim is to manipulate the lower jaw so the clinician can feel that these condyles are moving into RAP. It's akin to an analogy of opening the door, the clinician can feel the hinge, and this is the gateway to good restorative dentistry. It's to be made sure not to push too far backward, pushing too far back with the thumbs moves condyles into a more retruded position and more inferiorly. So, most of the pressure coming from my fingers has to be directed in up and down up and down direction in a vibratory motion, trying to get closer and closer to the very first point of contact, patient pinpoints the tooth which he/she notices are making the first contact, this is then confirmed with an articulating paper. This first point of contact is the Retruded contact position RCP [12].

### Recording Retruded Contact Position (RCP)

The first point of contact is established by manipulating the

lower jaw and then asking the patient to point to the upper tooth that he/she feels contact first. This is then confirmed with articulating paper. The most common area is the upper premolar tooth contacting the lower canine at some point on its surface, usually on the palatal side. The significance of RCP is that the first point of contact with the condyles in RAP is that during crown preparation inter-occlusal space can easily be lost. During crown preparation that contact is removed which stops the patient's mandible from closing in its ideal position through the normal ideal path of closure. The mandible can reposition, and as the mandible repositions most of the time the mandible and the condyle will reposition in an upwards backward position, which means that the tooth will reposition slightly closer to and further back than it was before; in effect, there is loss of space. For example, in a tooth prepared for a zirconium crown with 1.2 mm off the occlusal clearance, by the time for the impression and bite registration, the condyles have repositioned upwards and backward, the lower jaw has repositioned upwards and backward, the lower tooth has repositioned upwards and backward resulting in the loss of interocclusal space. It is suggested to measure and look and record where RCP is; for the restorative procedure the ideal way to go about it is to do the occlusal adjustment first, take away that contact, let the condyles then resettle in their ideal position and then a couple of weeks later you can come back and carry out the crown preparation [12].

### Examination, identification and classification of the presence of slide from RCP to ICP

It is very important to understand the slide from retreated contact position into the intercostal position and its implications and what it means to a restorative dentist. First of all, we have to establish the first point of contact and RCP, 90% of patients have a slide into the intercourse position and what the clinician has to do is to try to classify that slide. The way we classify this slide from RCP into ICP is based on the observation that this movement or slide is either more vertical or the movement is more horizontal. Whatever movement or slide we can observe, will have a horizontal and vertical component. If the patient is lying flat in the dental chair the horizontal component will move the jaw up or down and the vertical component will move the jaw back and forth sideways. We also have to try in the classification to find out, if the slide is more vertical and less horizontal or more horizontal and less vertical. So, in the classification, the slide is called large vertical small horizontal, or large horizontal small vertical. 90% of the slides are up slides, 90% of those slides will have a larger vertical and smaller horizontal component and these patients are easy to treat. In order to assess the slides properly the clinician needs to look not only from the front but also from the side. It may be very difficult for the clinician to assess how much the jaw is moving horizontally when looking from the front. So the clinician has to assess the horizontal slide looking from the side and assess the vertical slide looking from the front. The aim is to find out which is the bigger movement for example you could have about 1mm vertical slide and about half a millimeter horizontal slide. It is important to understand the relevance of this, most patients have a vertical slide, and

these are easy, quick, and simple treatments. It usually takes a maximum of 10–15 minutes to eliminate the premature contact and may include only one or a few teeth or pairs of teeth that will need adjustment. The elimination of interference may require removing 20 to 30 microns of enamel and then checking again to see if the slide has been eliminated. It is possible that after removing the interference it may go somewhere else and may need to be marked up again and adjusted and it will take a relatively short period of time to eliminate all the interference. After this, the patient should be able to close all of his teeth together in an intercostal position with his condyle seated in that ideal muscular relaxed bone brace position. In the case of a horizontal slide, these are the difficult ones to treat. The clinician has to be very careful in treating such patients. The problem with the horizontal slide is more difficulty in adjusting because more teeth are involved, it could in fact involve all the lower and upper posterior teeth, so it could require adjusting more than 10 teeth. Time wise it is going to take a long time to make these adjustments and it's very easy to lose one's way and one doesn't see the results of the elimination of that slide. The other problems are that the position of the anterior teeth changes because it's a horizontal slide, so the mandible drops backward, and as it dropped backward one can easily lose anterior tooth contact [12].

### Occlusion and its effect on Temporomandibular Disorder (TMD)

Evaluation of the TMJ is critical for the assessment of occlusal stability [13]. Following this can the occlusion be evaluated more effectively for long-term stability and the five principles of occlusion applied to create equilibrium so that the occlusion is in harmony with the TMJs.

Most functional and parafunctional (bruxing and clenching) movements of the mandible take place around the ICP and it is the position of the mandible in which maximum intercuspation of the teeth occurs [14]. In these functional movements, there is a brief contact between maxillary and mandibular teeth, this is usually toward the end of the masticatory cycle. However, during parafunctional activity prolonged periods of forceful tooth contact may be produced [15].

It is very important for the dentist should be able to rule out that the pain for TMD is not due to problems in masticatory system structure and occlusion; it is also important that dentists develop sufficient knowledge and expertise in this field. Dentists who do not feel competent to render adequate treatment should at the very least be able to recognise the occlusal disease in its various forms and can refer the patients to appropriate specialists if signs and symptoms are not within the dentist's field of expertise. Patients have to be informed of the occlusal problems and should be referred appropriately when the need for treatment is evident [16].

### Importance of occlusion in restorative dentistry

Restorations placed in the teeth can have a profound effect on dental occlusion and thus it is of fundamental importance in restorative dentistry. For both direct and indirect restorations,

the occlusal surfaces of the teeth are most often involved. These restorations are planned to conform to an occlusal pattern, and not disrupt it unless it is altered for very specific reasons [17].

It is possible that restorative dental procedures can cause changes in occlusion, resulting in problems with teeth and restorations. Every dentist endeavours to avoid these problems and wishes predictable successful restorations that are placed. Effective management of the occlusion leads to a predictable fitting of restorations and prostheses and their longevity, patient comfort and occlusal stability, and absence of iatrogenic problems [18].

Dentists may not examine and record the pre-existing occlusion before the restoration is placed. Instead, it has become routine to provide the restoration and then examine the occlusion afterward. It can be safely assumed that it is impossible to compare the occlusion after placement of the restoration to the pre-existing occlusion if it was not recorded in the first place [17]. Restorations should be planned, designed, and placed to fit harmoniously with the stomatognathic system without introducing any interferences in the occlusion. A stable posterior occlusion with uninterrupted protrusive and lateral movement of the mandible is ideal but not always possible. Patients with class III occlusion and anterior open bite do not have anterior guidance on the incisors, but teeth further back provide the guidance. In many people, several teeth in each arch share the lateral guidance termed 'group function' and can involve the premolars and canines or another combination of teeth. The lateral guidance may not be the same on both sides of the arch [19]. Once the occlusion has been assessed, it has to be decided as to which approach to the occlusal scheme has to be used for the restorations [9].

### Approaches to occlusal schemes in restorative dentistry

These can be either a conformative approach or a reorganised approach.

**Conformative approach:** In this approach, consideration of the occlusal scheme is made according to the patients existing intercuspation position, and new restorations are provided in harmony with the existing jaw relationships. Ideally, it requires an analysis of the occlusion to ensure that it adequately meets a defined standard. The difficulty is that the standard is not clearly defined in all circumstances with regard to occlusal contacts and the nature and stability of the contact. As an example, the cusp-fossa relationships should ideally exhibit tripodism i.e. a 3 points contact around the cusp; however, the evidence for this is weak. In addition, the phenomenal accuracy that seems to be prescribed does not take into account the state of the periodontium and the effects of any periodontal disease.

### The conformative approach includes two situations:

1. No changes are made in occlusion prior to tooth preparation, although small changes can be made on restorations such as the elimination of the non-working side contacts.



2. Modifications are made in occlusion by localised adjustments to the occluding surface of teeth before tooth preparation, i.e. removal of deflective contacts on the tooth to be restored, shortening of the opposing cusps and elimination of non-working side interferences [20,21]

**Various situations in which a conformative approach can be used are:**

1. The occlusion of the patient appears to be ideal, i.e. centric occlusion coincides within 1 mm of the centric relation with anterior guidance being in the front of the mouth and is free from any posterior interferences.
2. The occlusion of the patient does not appear to be ideal, however, the removal of the existing occluding surface of the tooth on which restoration is to be placed does not inevitably change the patient's centric occlusion or the anterior guidance.
3. There is an absence of any TMD. If the patient has an existing TMD, then a decision has to be taken if it needs to be treated first, since it is possible that the treatment of this condition could result in changes to the patient's occlusion. [17,22].

Improving the occlusion within the boundaries of the conformative approach; the principle of not making any changes in occlusion is paramount within the conformative approach; this is concerning the occlusal contacts of the teeth that are not involved in the proposed restoration. However, it is not mandatory in this approach that the new restoration should reproduce the exact occlusion of the tooth that requires restoration. One of the main purposes of restoring the tooth would probably be lost if that were the case. Improvements in the occlusion that are to be made are best considered within the principles of 'ideal occlusion' as described by Dawson [23]. Any contacts between the opposing teeth that occur on incline surfaces of the cusps are potentially harmful due to the lateral forces that may be generated. As lateral forces on the teeth have harmful sequelae on teeth, the elimination of incline contacts becomes necessary. As long as the jaw relationship is not changed and it remains the same, it is still within the dominion of the conformative approach. Within the envelope of the conformative approach, it is possible to improve the occlusion of the tooth to be restored by the elimination of incline contacts either by careful design of the occlusal surface of the new restoration or by judicious alteration of the opposing tooth [17]; however, it is worth mentioning that studying this phenomenon is very difficult and the level of evidence is quite low.

If the occlusal relationships of the teeth that are not involved in the restoration are required to be changed during the restorative procedure, then the approach no longer conforms to the conformative approach but to a reorganised one. If the reorganised approach is required to be used for the management of the occlusion, it should happen by design and preparation and not by chance [24].

The technique used for the conformative approach: Davies, et al. [17] describes the 'Examine, Design, Execution and Check' (EDEC) principle when considering the provision of restorations to a conformative approach. This principle is a system that describes a logical approach and the sequence of producing a restoration, to the conformative approach.

First of all, both the static and dynamic occlusions are examined before any restorative procedure is carried out; this involves marking up the teeth with different coloured articulating paper for static and dynamic contacts. The design of the cavity preparation is done next, the occlusal marks are either preserved by avoiding them within the preparation, or they are involved in the design. It is possible to modify the occlusal surfaces within the scope of the conformative approach. The execution of the restoration is done next; the finishing of the restoration is also carried out with a definite aim for carving or shaping. Finally, after the placement of the restoration, the occlusion of the restoration is checked again to make sure the restoration permits all the other teeth to occlude in the same way as they did before. This can be done by referring to some diagrammatic record, by reversing the colour of the articulating paper used pre-operatively, or from memory. This principle also applies to indirect restorations; the critical difference is that a second operator is involved, i.e. the laboratory technician. The dentist has to accurately record the results of that examination and then transfer them to the technician. It is also important that the fabrication of the temporary restoration is done so that it will not alter the relationship between the prepared tooth and the adjacent and opposing teeth [24].

Consequences of not conforming to correct occlusion: Restorations and areas of the tooth that were not in occlusion before the restoration was placed may contact prematurely in occlusion resulting in the fracture of the tooth or the restoration. The patient may posture the mandible more anteriorly to avoid premature contact with the restoration resulting in anterior tooth wear. Teeth that were previously sound with relatively small restorations may crack as a result of the newly altered occlusion. Restorations that are left too high are a considerable source of discomfort for the patient and a problem for the dentist. The patient may complain of toothache and occasionally headache, muscle soreness, and TMJ pain. The restoration may break or the cusp may fracture. The surface of the tooth opposing the high restoration may be worn down or the cusp may crack or there may be tooth mobility or drifting. Some of these alterations that will occur in the patient's occlusion may be difficult to correct at a later stage. Occlusal surfaces of indirect restorations should need minimal adjustment. Inaccuracies can occur in the working impression, the opposing impression, the occlusal record, the lab mounting of the casts, and inadequate provisional restoration. If the provisional restoration is poorly made or lost, drifting and overeruption of the prepared or opposing teeth may result. This will result in an indirect restoration that is high and ill-fitting with tight proximal contacts [19].

To avoid restorations that are high on occlusion by deliberately providing restorations that are out of contact

with the opposing tooth and do not contribute to the overall occlusion is not good occlusal practice. It can also cause interferences because the restored tooth and opposing teeth are subject to supra-eruption and drifting. The unpredictable movement of teeth can lead to the disruption of excursive tooth contacts and the introduction of premature contacts, risking problems at a later stage [19].

In the treatment of tooth wear cases, however, an approach of placing a restoration in supra-occlusion has been well documented and follows the principles of the Dahl concept [25]. In these situations, it is expected that through the combined process of dentoalveolar segment intrusion and extrusion respectively, occlusal contact is re-established after a suitable period of time [26,27].

Situations in which a conformational approach is not a prudent option include loss of vertical dimension, severe bruxism resulting in repeated fractures of the teeth or failures of restorations, trauma from occlusion, lack of intercuspal space for restorations, unacceptable function, and aesthetics, presence of developmental anomalies of the jaws resulting in unstable occlusion. A reorganised approach is more suitable in these situations [19].

**Reorganised approach:** This approach is used if the existing occlusal scheme is unsatisfactory for the proposed restorative plan or if there are specific problems that can only be resolved by reorganising the occlusion or when extensive treatment is to be undertaken which results in changes to the patient's occlusal scheme [24].

The treatment objective of a reorganised occlusion is to provide restorations, at an altered occlusion, which is well tolerated by the patient at every level. The principle of using this approach is to provide an occlusion to the patient that is ideal at every level. This ideal occlusion is the one that is within the neuromuscular tolerances of that patient at that point in time. This approach involves extra stages of designing and executing a new occlusion before the provision of definitive restorations. It is not possible to make comprehensive rules for the management of every restorative clinical situation. However, Davies, et al. [24] and Davies [28] have provided guidelines for planning the re-organisation of the occlusion which provides a broadly applicable protocol.

The EDEC sequence used in the reorganised approach differs from that in the conformational approach in the examination and the execution phase. It is to be estimated if the new (centric) occlusion can be made to this ideal jaw relationship; it is optimal if it can be. Recording jaw relationships is much more difficult in this approach. The use of articulators becomes much more critical in achieving an acceptable degree of reproducibility in restorative cases where major changes to occlusal relationships are to be made. The accurate assessment of centric relation is usually made more difficult by the length of time that patients have been living with their less-than-ideal occlusion which has resulted in patients closing in habitual occlusal positions and avoiding any uncomfortable deflective contacts. It is often, necessary to 'de-programme' the musculature for some period

of time before recording centric relation. Some of the methods by which this de-programming can be achieved include 'Bimanual manipulation' or the provision of an anterior bite plane ('Lucia jig'); sometimes even these don't work and a stabilisation splint may have to be employed [24].

For occlusal recording and reconstruction, there is a large choice of articulators available. The Denar semi-adjustable articulator along with a face-bow is the most popular in use for complex restorative treatment.

## Summary

Occlusal considerations are very important in the field of restorative dentistry. Ideal occlusion is a concept in the treatment of a patient who needs multiple restorations. Various occlusal philosophies have been promoted by restorative occlusal experts. The majority of restorative treatments can be carried out using a conformational approach. An advanced restorative treatment plan involving the reorganised occlusal approach is more complicated and is a major challenge for restorative dentists. Assessment and consideration of TMJ are essential in any occlusal planning for any restorative treatment. The successful outcome of treatment involving occlusal considerations depends upon the skill of the dentist and the technician, and also the treatment planning. The main key to success is attention to occlusal detail and the sequential treatment plan.

## References

1. Nelson SJ. Wheeler's dental anatomy, physiology and occlusion-e-book, Elsevier Health Sciences. 2014.
2. Davies S, Gray RM. What is occlusion? Br Dent J. 2001 Sep 8;191(5):235-8, 241-5. doi: 10.1038/sj.bdj.4801151a. PMID: 11575759.
3. Tipton P. Restoration fundamentals. Scottish Dental Magazine. 2013.
4. Hersh HA. Current Concepts in Occlusion, McGill University (Canada). 1971.
5. Tiwari B, Ladha K, Lalit A, Dwarakananda Naik B. Occlusal concepts in full mouth rehabilitation: an overview. J Indian Prosthodont Soc. 2014 Dec;14(4):344-51. doi: 10.1007/s13191-014-0374-y. Epub 2014 Jun 25. PMID: 25489156; PMCID: PMC4257939.
6. Song MY, Park JM, Park EJ. Full mouth rehabilitation of the patient with severely worn dentition: a case report. J Adv Prosthodont. 2010 Sep;2(3):106-10. doi: 10.4047/jap.2010.2.3.106. Epub 2010 Sep 30. PMID: 21165279; PMCID: PMC2994694.
7. Koc D, Dogan A, Bek B. Bite force and influential factors on bite force measurements: a literature review. Eur J Dent. 2010 Apr;4(2):223-32. PMID: 20396457; PMCID: PMC2853825.
8. Singh A, Sangur R, Rao BL, Mahajan T. A clinical study to determine the pattern of occlusal contacts in lateral positions and its validity in classifying guidance patterns. J Indian Prosthodont Soc. 2013 Jun;13(2):101-7. doi: 10.1007/s13191-012-0210-1. Epub 2012 Nov 9. PMID: 24431718; PMCID: PMC3634949.
9. McCulloch AJ. Making occlusion work: 2. Practical considerations. Dent Update. 2003 May;30(4):211-6, 218-9. doi: 10.12968/denu.2003.30.4.211. PMID: 12830699.
10. Bakke M. Mandibular elevator muscles: physiology, action, and effect of dental occlusion. Scand J Dent Res. 1993 Oct;101(5):314-31. doi: 10.1111/j.1600-0722.1993.tb01127.x. PMID: 8248735.



11. Tipton P. Advanced restorative techniques and the full mouth reconstruction: part two – occlusal concepts. Private Dentistry. 2010.
12. Tipton P. Lecture series on occlusion. 2023. <https://tiptontraining.co.uk/>
13. Thomas DC, Briss D, Rossouw PE, Iyer S. Temporomandibular Disorders: Implications in Restorative Dentistry and Orthodontics. Dent Clin North Am. 2023 Apr;67(2):309-321. doi: 10.1016/j.cden.2022.10.003. PMID: 36965933.
14. Capp NJ. Occlusion and splint therapy. Br Dent J. 1999 Mar 13;186(5):217-22. doi: 10.1038/sj.bdj.4800069. PMID: 10205968.
15. Reddy SV, Kumar MP, Sravanthi D, Mohsin AH, Anuhya V. Bruxism: a literature review. J Int Oral Health. 2014 Nov-Dec;6(6):105-9. PMID: 25628497; PMCID: PMC4295445.
16. Dawson PE. Functional occlusion: from TMJ to smile design, Elsevier Health Sciences. 2006.
17. Davies SJ, Gray RM, Smith PW. Good occlusal practice in simple restorative dentistry. Br Dent J. 2001 Oct 13;191(7):365-368, 371-4, 377-81. doi: 10.1038/sj.bdj.4801185. PMID: 11697598.
18. McCulloch AJ. Making occlusion work: I. Terminology, occlusal assessment and recording. Dent Update. 2003 Apr;30(3):150-7. doi: 10.12968/denu.2003.30.3.150. PMID: 12743913.
19. Wassell R, Naru A, Steele J, Nohl F. Applied Occlusion 2nd Edition. Quintessentials of Dental Practice-Prosthodontics. 2015.
20. Celenza FV, Litvak H. Occlusal management in conformational dentistry. J Prosthet Dent. 1976 Aug;36(2):164-70. doi: 10.1016/0022-3913(76)90138-4. PMID: 1068280.
21. Foster LV. Clinical aspects of occlusion: 1. Occlusal terminology and the conformational approach. Dent Update. 1992 Oct;19(8):345-8. PMID: 1291384.
22. Davies SJ, Gray RJ, Qualtrough AJ. Management of tooth surface loss. Br Dent J. 2002 Jan 12;192(1):11-6, 19-23. doi: 10.1038/sj.bdj.4801278. PMID: 11852896.
23. Dawson P. Evaluation, diagnosis and treatment of occlusal problems, Dawson, PE. The CV Mosby company. 1989.
24. Davies SJ, Gray RM, Whitehead SA. Good occlusal practice in advanced restorative dentistry. Br Dent J. 2001 Oct 27;191(8):421-4, 427-30, 433-4. doi: 10.1038/sj.bdj.4801200. PMID: 11720016.
25. Dahl BL, Krogstad O, Karlsen K. An alternative treatment in cases with advanced localized attrition. J Oral Rehabil. 1975 Jul;2(3):209-14. doi: 10.1111/j.1365-2842.1975.tb00914.x. PMID: 1056978.
26. Hemmings KW, Darbar UR, Vaughan S. Tooth wear treated with direct composite restorations at an increased vertical dimension: results at 30 months. J Prosthet Dent. 2000 Mar;83(3):287-93. doi: 10.1016/s0022-3913(00)70130-2. PMID: 10709036.
27. Poyser NJ, Porter RW, Briggs PF, Chana HS, Kelleher MG. The Dahl Concept: past, present and future. Br Dent J. 2005 Jun 11;198(11):669-76; quiz 720. doi: 10.1038/sj.bdj.4812371. PMID: 15951771.
28. Davies S. Good occlusal practice in advanced restorative dentistry. In A Guide to Good Occlusal Practice Cham: Springer International Publishing. 2022; 79-118.

## Discover a bigger Impact and Visibility of your article publication with Peertechz Publications

### Highlights

- ❖ Signatory publisher of ORCID
- ❖ Signatory Publisher of DORA (San Francisco Declaration on Research Assessment)
- ❖ Articles archived in worlds' renowned service providers such as Portico, CNKI, AGRIS, TDNet, Base (Bielefeld University Library), CrossRef, Scilit, J-Gate etc.
- ❖ Journals indexed in ICMJE, SHERPA/ROMEO, Google Scholar etc.
- ❖ OAI-PMH (Open Archives Initiative Protocol for Metadata Harvesting)
- ❖ Dedicated Editorial Board for every journal
- ❖ Accurate and rapid peer-review process
- ❖ Increased citations of published articles through promotions
- ❖ Reduced timeline for article publication

Submit your articles and experience a new surge in publication services (<https://www.peertechz.com/submission>).

*Peertechz journals wishes everlasting success in your every endeavours.*