



Medical Group

# Journal of Cardiovascular Medicine and Cardiology

ISSN: 2455-2976

DOI

CC BY

## Shogo Shimada and Louis Samuels\*

Division of Cardiothoracic Surgery, Department of Surgery, Thomas Jefferson University, Philadelphia, Pennsylvania

**Dates:** Received: 08 September, 2017; Accepted: 20 September, 2017; Published: 21 September, 2017

\*Corresponding author: Louis Samuels MD, Division of Cardiothoracic Surgery, Department of Surgery, Thomas Jefferson University, 1025 Walnut Street, Suite 607 Philadelphia, PA 19107, Tel: (215) 955-6996 Fax: (215) 955-6010; Email: Louis.Samuels@jefferson.edu

<https://www.peertechz.com>

## Case Report

# Right atrial thrombus: A new cause of Paroxysmal complete Heart Block

## Abstract

We present a patient with a large right atrial (RA) thrombus complicated by paroxysmal complete atrioventricular (AV) block requiring urgent surgery. This is a rare complication of RA thrombi with the potential pathogenesis being direct mechanical insult on the AV node by the thrombus. Surgical thrombectomy led to complete resolution.

## Introduction

Right Atrial (RA) thrombi develop in a variety of clinical situations. Most of them are found incidentally by echocardiography and thus, rarely cause obvious clinical symptoms unless they embolize distally. Herein, we report a unique case of a large, well-organized RA thrombus which caused paroxysmal complete AV block.

## Case Report

A 40 year-old woman with a history of ulcerative colitis with recent flare, diabetes mellitus, and morbid obesity (BMI 47) presented to the emergency department with a syncopal episode. She was tachycardic and hypotensive refractory to intravenous fluid resuscitation. She was also found to have pancytopenia and acute kidney injury. She was started on empiric antibiotics and vasopressor support via a central venous catheter. She was admitted to the medical intensive care unit (MICU) with a presumptive diagnosis of sepsis. Microbiologic cultures were positive for *E. coli* bacteremia and *Clostridium difficile* colitis.

In the MICU she developed hypoxic respiratory failure requiring intubation. A non-contrast computed tomography (CT) scan of the abdomen showed colitis with no apparent structural abnormalities around the inferior vena cava (IVC). Duplex ultrasonography of the abdomen and pelvis, however, showed a 4.3 X 2.2 X 2.7 mass at the cavo-atrial junction. Computer Tomography of the chest with contrast was not performed due to renal dysfunction with elevated creatinine. Transthoracic echocardiography (TTE) confirmed the presence of a large, mobile RA mass arising from the uppermost IVC extending into the RA proper. Echocardiographic assessment of the cardiac function was normal, estimation of the pulmonary

artery pressures were within normal limits, and there was no significant tricuspid stenosis or regurgitation. No deep vein thrombosis (DVT) was noted by ultrasonography of the lower extremities. The mass was thought to be a thrombus for which heparin infusion was initiated. Although the sepsis syndrome improved, the clinical course was further complicated by lower GI bleeding necessitating discontinuation of heparin. Repeat TTE showed no change in the RA thrombus and RV function. Furthermore, the patient rhythm demonstrated intermittent conversion from sinus tachycardia (Figure 1A) to paroxysmal complete AV block with simultaneous sinus slowing (Figure 1B). Considering the size and location of the thrombus, it was postulated that the RA thrombus was causing this complication by intermittent mechanical interference with the AV node

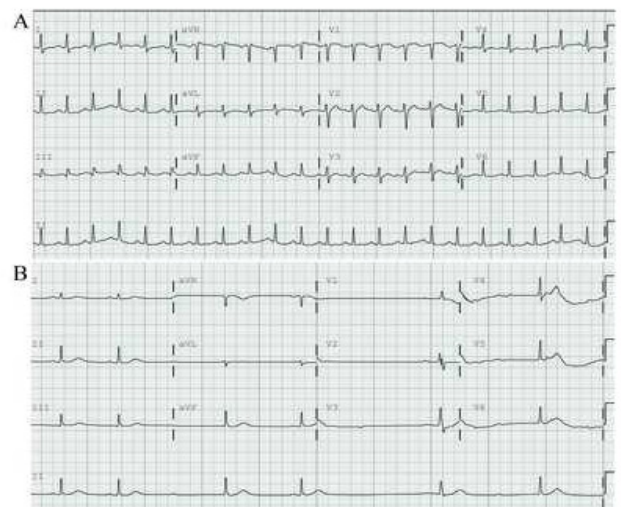


Figure 1A,B: A) EKG showing Sinus Tachycardia. B) EKG showing Complete Heart Block.

within the anatomic Triangle of Koch. The decision was made to proceed with urgent surgical thrombectomy.

Intraoperatively, transesophageal echocardiography (TEE) confirmed the RA thrombus, its origin from the uppermost IVC at the cavo-atrial junction with extension into the RA proper (Figure 2A-D). A median sternotomy was performed and cardiopulmonary bypass (CPB) was established by aortic perfusion and superior vena caval (SVC) drainage. After cardiac arrest was obtained by antegrade cardioplegic solution, a right atriotomy was made. By utilizing pump suckers into the IVC and a brief period of reduced pump flow, the origin of the RA thrombus was identified and removed in its entirety. The resected specimen consisted of a 6 X 1.4 X 2.2 cm, solid, tan-white, cylindrical tissue with a tan-pink hemorrhagic rim (Figure 2E&F). Histological evaluation confirmed a fibrin thrombus. The patient was weaned from CPB without difficulty and was in normal sinus rhythm (CPB time, 30 min; aortic cross clamp time, 12 min). Prophylactic epicardial pacing wires were placed but never utilized—the patient remained in a normal sinus rhythm. An IVC filter was placed postoperatively for DVT/pulmonary embolism (PE) prevention in view of the operative findings, her risk for DVT/PE, and the contraindication for anticoagulation prophylaxis due to her ulcerative colitis with GI bleeding. No formal anticoagulation was initiated. Postoperatively, she experienced prolonged ventilator dependence requiring tracheostomy, but no recurrence of AV block. She was discharged to a nursing home one month postoperatively with a tracheostomy collar. No further episodes of heart block were documented in follow-up.

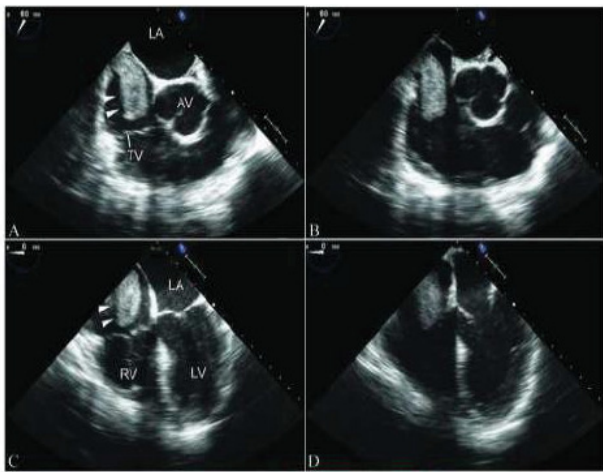


Figure 2A-D: Echocardiogram showing RA thrombus from IVC into RA across Tricuspid Valve.

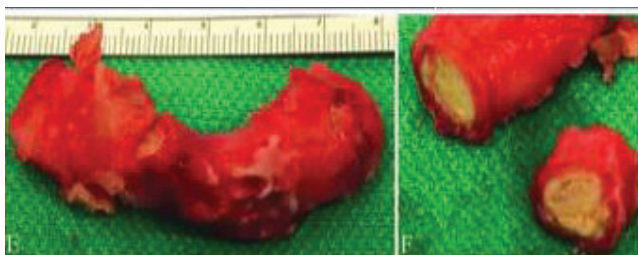

Figure 2E,F: Gross specimen of RA thrombus.

## Comment

RA thrombi associated with complete AV block is an extremely rare occurrence. A few case reports have described that complete AV block could occur as a result of new onset right bundle branch block secondary to RV overload in patients with preexisting left bundle branch block who develop acute PE [1-3]. However, a RA thrombus as the predominant cause for complete AV block has never been reported. We speculated that this complication was a manifestation of intermittent mechanical compression on the AV node by the thrombus and may also explain her initial presentation with syncope. Although paroxysmal AV block with simultaneous sinus slowing is characteristic of vagally mediated AV block [4], direct mechanical insult could not be denied given the proximity of the mass to the AV node as shown on echocardiography (Figure 2A-D).

Although there is no established consensus on the treatment of RA thrombi [5,6], the current case required urgent surgical thrombectomy for several reasons: the thrombus appeared large and mobile with the potential for a saddle embolus, anticoagulation therapy was contraindicated due to active GI bleeding, percutaneous extraction was deemed unsafe, and the mass was causing complete heart block.

The surgical approach took into consideration the patient's body habitus as well as the location of the mass itself. While complete femoral cannulation could have been performed, the large abdominal pannus would have made this approach problematic. In addition, femoral venous cannulation—with guidewire Seldinger-type guidance—may have dislodged the thrombus. As such, the decision was made to establish CPB via direct aortic and SVC cannulation. Once on CPB, the decision was made to cross-clamp and institute cardioplegic arrest, thereby affording complete control of the intracardiac situation. Opening the RA in the arrested heart and lowering the CPB flow with additional drainage into the cavo-atrial junction afforded excellent visualization to remove the mass in its entirety.

The present case is reflective of a diagnostic and therapeutic challenge with multiple factors influencing the decision-making. We believe the patient's respiratory failure was a consequence of her sepsis and not pulmonary emboli or a primary lung-related problem—the preoperative and intraoperative echocardiogram did not suggest RV dysfunction related to a pulmonary embolic pathophysiology. The decision to avoid anticoagulation postoperatively was problematic. However, in view of her aggressive ulcerative colitis with significant GI bleeding, the decision was made to avoid further exacerbation of bleeding by abstaining from initiating anticoagulation.

The uniqueness of the case is not the RA thrombus itself, but the consequences of it. The mass, due to its size and location, could represent a novel pathogenesis of complete AV block. Although the etiology of the thrombus remains uncertain, we do not believe it was related to a previously placed central line for two reasons: 1) the characteristics of the thrombus would suggest that it was several weeks to months old and 2) the

location of the central line placed at the time of her admission was remote from the origin of the thrombus in the IVC/RA junction.

In conclusion, this case represents a unique finding of a cavoatrial thrombus causing intermittent heart block that was resolved with removal of the mass. The management of this condition required thoughtful surgical and medical intervention.

## References

1. Simantirakis EN, Nakou ES, Chrysostomakis SI, Arkolaki EG, Vardas PE (2014) Simultaneous appearance of complete heart block and pulmonary embolism. The riddle of the chicken and the egg. *Int J Cardiol* 173: 610-611. [Link: https://goo.gl/cqQYfD](https://goo.gl/cqQYfD)
2. Marti J, Casanovas N, Recasens L, Comin J, Garcia A, et al. (2005) [Complete atrioventricular block secondary to pulmonary embolism]. *Rev Esp Cardiol* 58: 230-232. [Link: https://goo.gl/whfSsA](https://goo.gl/whfSsA)
3. Wilner C, Garnier-Crussard JP, Huygue De Mahenge A, Gayet C, et al. (1983) [Paroxysmal atrioventricular block, cause of syncope in pulmonary embolism. 2 cases]. *Presse Med* 12: 2987-2989. [Link: https://goo.gl/LALBwq](https://goo.gl/LALBwq)
4. Alboni P, Holz A, Brignole M (2013) Vagally mediated atrioventricular block: pathophysiology and diagnosis. *Heart* 99: 904-908. [Link: https://goo.gl/TwSstx](https://goo.gl/TwSstx)
5. Athappan G, Sengodan P, Chacko P, Gandhi S (2015) Comparative efficacy of different modalities for treatment of right heart thrombi in transit: a pooled analysis. *Vasc Med* 20: 131-138. [Link: https://goo.gl/g6LnzC](https://goo.gl/g6LnzC)
6. Chartier L, Bera J, Delomez M, Asseman P, Beregi JP, et al. (1999) Free-floating thrombi in the right heart: diagnosis, management, and prognostic indexes in 38 consecutive patients. *Circulation* 99: 2779-2783. [Link: https://goo.gl/GGZkSU](https://goo.gl/GGZkSU)