



Case report

# Short implants and tooth-implant connections

Michel Abbou<sup>1,2\*</sup>

<sup>1</sup>Private Practice in Paris, France

<sup>2</sup>Scientific Director of SICT MIEUX, France

Received: 15 June, 2023

Accepted: 29 June, 2023

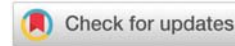
Published: 30 June, 2023

\*Corresponding author: Dr. Michel Abbou, Private Practice in Paris, France,  
E-mail: [drmichel.abbou@orange.fr](mailto:drmichel.abbou@orange.fr),  
[contact@sictmieux.com](mailto:contact@sictmieux.com)

**Keywords:** Short implant; Extra-short implant; Tooth-implant connection; Therapeutic compromise; Tooth-implant supported bridge; Single implant

**Copyright License:** © 2023 Abbou M. This is an open-access article distributed under the terms of the Creative Commons Attribution License, which permits unrestricted use, distribution, and reproduction in any medium, provided the original author and source are credited.

<https://www.peertechzpublications.com>



## Abstract

Both *short implants* (<8mm) and *tooth-implant connections* are, to say the least, controversial therapeutic means. However, if we take a serious look at the data in the scientific literature, we can observe favorable clinical results in both areas, enabling these therapeutic options to be accepted as Evidence-Based Dentistry.

## Introduction

The delicacy of these two therapeutic tools, both in terms of indications and implementation, is indisputable. However, the objections raised in these two fields to prevent patients and practitioners from using them, must be rejected [1-3], especially as they are most often made by people with no clinical experience in the field, as was the case in a “gentle indictment” published in 2016 concerning other types of treatments [4].

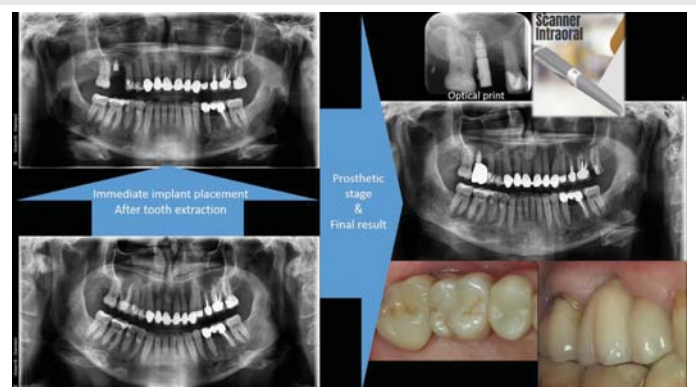
### Short implants

Although they have a statistically slightly lower survival rate after 1 to 5 years [5], they are acceptable and should be used as part of a *therapeutic alternative or compromise* / Figure 1.

The main question is: *where do we place the therapeutic compromise cursor when it turns out that, in atrophic posterior jaws, bone behavior around extra-short implants is finally better than that observed around long implants placed after bone augmentation* [6]?

Thus, beyond the “therapeutic ideal”, we need to bear in mind that our daily practice as therapists is riddled with therapeutic compromises that we implement more or less consciously for various reasons. I personally readily classify many of our so-called “conventional treatments” under the

heading of “*therapeutic compromises*”, whereas many of my colleagues consider them to be part of “*therapeutic orthodoxy*”, because they are officially taught as such as part of our university curriculum. Among these treatments, let's mention partial and complete removable dentures (which never represent the ideal treatments as envisaged by our patients!), or conventional bridges that “sacrifice” teeth adjacent to the edentulous zone to be compensated.



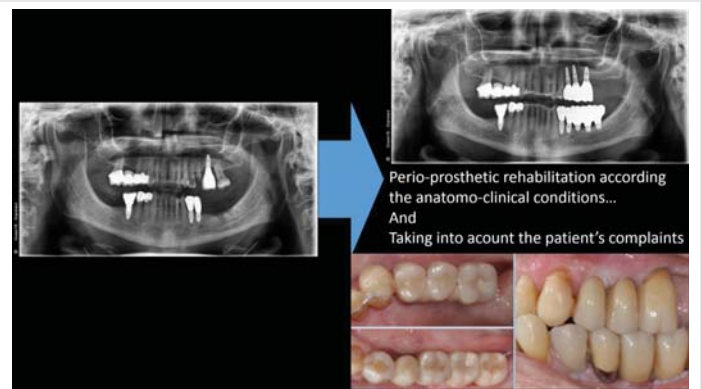
**Figure 1:** Immediate implant placement with a Magix® 8mm implant (Cortex Ltd) in the upper molar zone: it is a delicate but acceptable alternative treatment (1, 2) for this 65 years-old man who didn't want a dental bridge (he already feels not comfortable with the one in he's lower jaw) nor any bone graft.

All this to say that, depending on the point of view and the objectives of our therapeutic means, the notion of compromise becomes very relative [7,8] Figures 2,3.

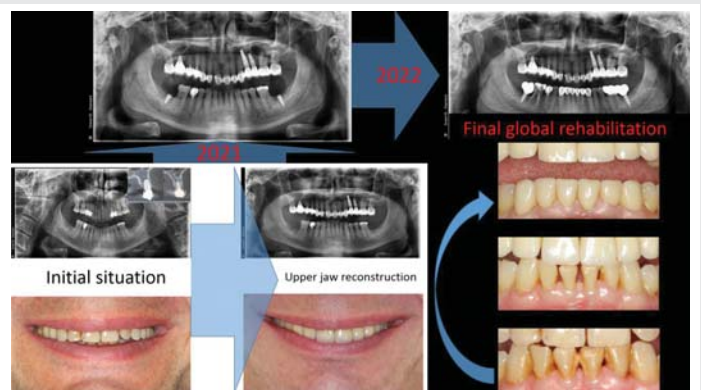
### Tooth-implant connections

In the same chapter of therapeutic compromises, we can also mention *splinting teeth* as clearly accepted part of our periodontal treatments. Studies demonstrate that such connections not only improve the patient daily comfort, but also are not detrimental to the involved teeth [9]. So why should it not be the same for tooth-implant connections which are commonly disparaged? This disparagement is mainly supported by the assumption that the clinical immobility of an implant works to its disadvantage if it is connected to one or more mobile teeth... Except that the same should be true of healthy teeth to which we readily attach mobile teeth with the aim of reducing the mobility of the latter. And if this tooth-implant bonding is to remain a second-line choice, many serious studies carried out over the last 25 years confirm the benefits and the validity of such a therapeutic compromise, especially when we use rigid prosthetic connections [10-13]. My own 30-years clinical experience in this field concurs and a recently published prospective study (over a period of more than 11 years, with a mean follow-up of 4,2 years) confirms the similarity of the results in terms of complications and success rate when using tooth-implant-supported and solely implant-supported double-crown-retained overdentures [14].

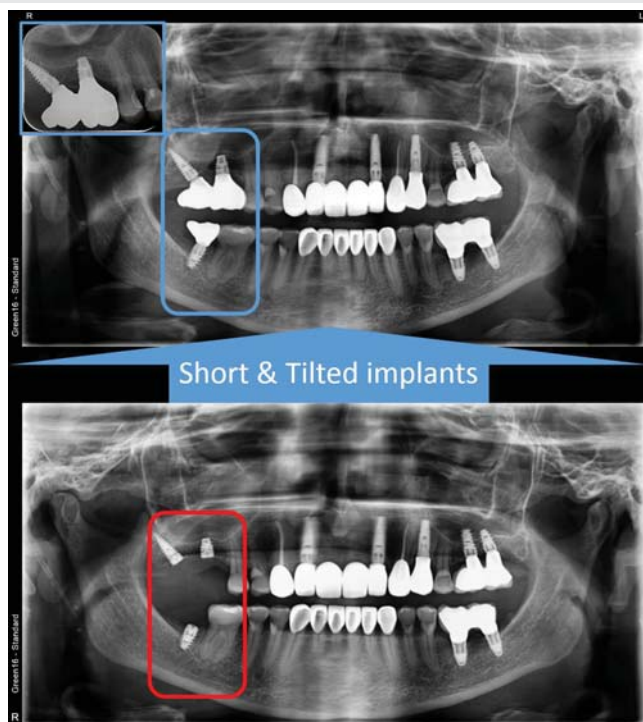
Just as we do with natural teeth [15], it can be concluded that it is in the patient's interest to focus our attention not on the question of validity of tooth-implant connections, but on how to implement them [16,17] Figures 4-7.



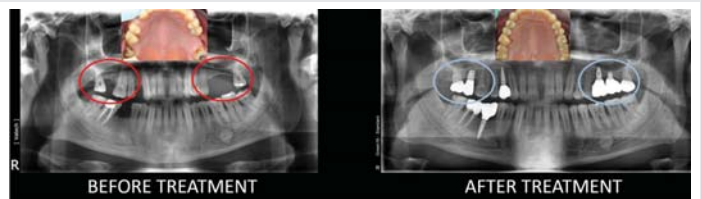
**Figure 3:** Compromised type treatment in this 67 years-old woman, using extra-short 4mm implants (Southern Implants®)... This Might be a better option than doing a bone augmentation followed by longer implants [6].



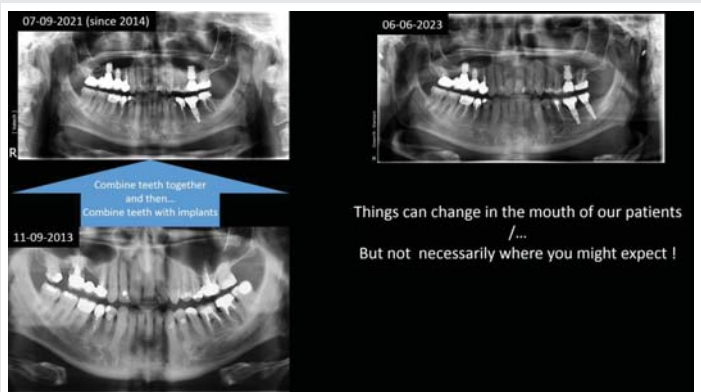
**Figure 4:** 70 years-old man with general periodontal disease + 2 fractured premolars + 2 missing molars. As part of the periodontal treatment, the upper jaw reconstruction was achieved by using prosthetic teeth-splinting in which we incorporated a small implant (4mm Southern Implants®) under the upper right sinus.



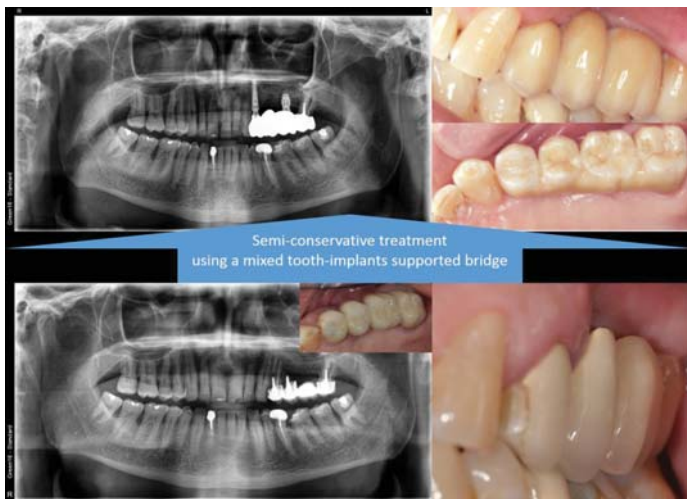
**Figure 2:** Combining short and titled implants is also a reconstructive option as part of a minimally therapeutic approach [7].



**Figure 5:** Bilateral dental deficit in this 68 years-old man: connecting teeth with (short) implants was the best therapeutic way we have chosen to both replace the missing teeth and stem the slight mobility of the 2nd maxillary molars.



**Figure 6:** Connecting teeth and implants is an option just as valid (and even sometimes better) than that of making bridges on natural teeth.



**Figure 7:** This 72 years-old patient was disappointed by his infected bridge on 3 natural teeth. All the corrective options have been proposed to him and the combined tooth-implants supported bridge was the one he has chosen.

## Conclusion

Both *short implants* (<8mm) and *tooth-implant connections* may be considered as second-line therapeutic choices. That doesn't mean they have little chances of success, but that these choices take into account not only the clinical benefit/risk ratio, but also the patient's complaints and the practitioner's skills in order to achieve an acceptable result in line with Evidence-Based Dentistry.

## References

1. Fan T, Li Y, Deng WW, Wu T, Zhang W. Short Implants (5 to 8 mm) Versus Longer Implants (>8 mm) with Sinus Lifting in Atrophic Posterior Maxilla: A Meta-Analysis of RCTs. *Clin Implant Dent Relat Res*. 2017 Feb;19(1):207-215. doi: 10.1111/cid.12432. Epub 2016 Jun 13. PMID: 27295262.
2. Anitua E, Alkhraisat MH, Eguia A. Single-crown restorations in premolar-molar regions: short ( $\leq 6.5$ ) vs longer implants: retrospective cohort study. *Int J Implant Dent*. 2022 Oct 4;8(1):40. doi: 10.1186/s40729-022-00438-y. PMID: 36192573; PMCID: PMC9530083.
3. La Monaca G, Pranno N, Annibali S, Massimo C, Polimeni A, Patini R, Paola Cristalli M. Survival and complication rates of tooth-implant versus freestanding implant supporting fixed partial prosthesis: a systematic review and meta-analysis. *J Prosthodont Res*. 2021 Feb 24;65(1):1-10. doi: 10.2186/jpr.JPOR\_2019\_494. Epub 2020 Sep 9. PMID: 32938874.
4. Abbou M. Clinical common sense against and against institutional dogma. *Dentoscopes*. 2018; 12-26.
5. Paspaspyridakos P, De Souza A, Vazouras K, Gholami H, Pagni S, Weber HP. Survival rates of short dental implants ( $\leq 6$  mm) compared with implants longer than 6 mm in posterior jaw areas: A meta-analysis. *Clin Oral Implants Res*. 2018 Oct;29 Suppl 16:8-20. doi: 10.1111/clr.13289. PMID: 30328206.
6. Chen S, Ou Q, Wang Y, Lin X. Short implants (5-8 mm) vs long implants ( $\geq 10$  mm) with augmentation in atrophic posterior jaws: A meta-analysis of randomised controlled trials. *J Oral Rehabil*. 2019 Dec;46(12):1192-1203. doi: 10.1111/joor.12860. PMID: 31295755.
7. Abbou M. Minimal invasive attitude in implantology. Words from experts. *Dentalespace*, June 2020.
8. Abbou M. Orthodox dentistry versus therapeutic compromises Words of experts. *Dentalespace*. April 2021; online

9. Graetz C, Ostermann F, Woeste S, Sälzer S, Dörfer CE, Schwendicke F. Long-term survival and maintenance efforts of splinted teeth in periodontitis patients. *J Dent*. 2019 Jan;80:49-54. doi: 10.1016/j.jdent.2018.10.009. Epub 2018 Oct 30. PMID: 30389428.
10. Gunne J, Astrand P, Ahlén K, Borg K, Olsson M. Implants in partially edentulous patients. A longitudinal study of bridges supported by both implants and natural teeth. *Clin Oral Implants Res*. 1992 Jun;3(2):49-56. doi: 10.1034/j.1600-0501.1992.030201.x. PMID: 15900668.
11. Abbou M, Chiche F, Picard B, Missika P. Prosthetic connection between implants and natural teeth. Clinical approach, bibliographic and prospective study. *Notebooks of Proth*. 1995; 91: 57-68.
12. Genon P, Genon-Romagna C. The contribution of implants in the treatment of advanced periodontitis. How implants can help improve the prognosis of dentition with reduced periodontium. *Journal of Periodontology and Oral Implantology*, 1997; 16 (2): 177-189.
13. Al-Omiri MK, Al-Masri M, Alhijawi MM, Lynch E. Combined Implant and Tooth Support: An Up-to-Date Comprehensive Overview. *Int J Dent*. 2017;2017:6024565. doi: 10.1155/2017/6024565. Epub 2017 Mar 23. PMID: 28424733; PMCID: PMC5382302.
14. Klotz AL, Fobbe H, Rammelsberg P, Lorenzo Bermejo J, Kappel S. Survival and success of tooth-implant-supported and solely implant-supported double-crown-retained overdentures: A prospective study over a period of up to 11 years. *Clin Oral Implants Res*. 2021 Dec;32(12):1425-1432. doi: 10.1111/clr.13842. Epub 2021 Oct 29. PMID: 34543479.
15. Kathariya R, Devanoorkar A, Golani R, Shetty N, Vallakatta V, Bhat MY. To Splint or Not to Splint: The Current Status of Periodontal Splinting. *J Int Acad Periodontol*. 2016 Apr 8;18(2):45-56. PMID: 27128157.
16. Hoffmann O, Zafiropoulos GG. Tooth-implant connection: a review. *J Oral Implantol*. 2012 Apr;38(2):194-200. doi: 10.1563/AAID-JOI-D-10-00071. Epub 2010 Nov 23. PMID: 21091344.
17. Abbou M. Prosthesis fixed on teeth and implants: proposal and justification of a protocol. *The Dentoscope*, January 2020; 16-23.

Discover a bigger Impact and Visibility of your article publication with Peertechz Publications

### Highlights

- ❖ Signatory publisher of ORCID
- ❖ Signatory Publisher of DORA (San Francisco Declaration on Research Assessment)
- ❖ Articles archived in worlds' renowned service providers such as Portico, CNKI, AGRIS, TDNet, Base (Bielefeld University Library), CrossRef, Scilit, J-Gate etc.
- ❖ Journals indexed in ICMJE, SHERPA/ROME0, Google Scholar etc.
- ❖ OAI-PMH (Open Archives Initiative Protocol for Metadata Harvesting)
- ❖ Dedicated Editorial Board for every journal
- ❖ Accurate and rapid peer-review process
- ❖ Increased citations of published articles through promotions
- ❖ Reduced timeline for article publication

Submit your articles and experience a new surge in publication services (<https://www.peertechz.com/submission>).

Peertechz journals wishes everlasting success in your every endeavours.