



Review Article

Anatomy Respect in Implant Dentistry. Assortment, Location, Clinical Importance (Review Article)

Rawaa Y Al-Rawee^{1*} and Mohammed Mikdad Abdalfattah²¹Department of Oral and Maxillofacial Surgery, Al-Salam Teaching Hospital. Mosul, Iraq²Post Graduate Student in School of Dentistry, University of Leeds. United Kingdom, Ministry of Health, Iraq

Received: 19 August, 2020

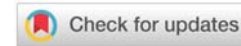
Accepted: 31 August, 2020

Published: 01 September, 2020

*Corresponding author: Dr. Rawaa Y Al-Rawee, BDS, M Sc OS, MOMS MFDS RCPS Glasgow, PhD, MaxFacs, Department of Oral and Maxillofacial Surgery, Al-Salam Teaching Hospital, Mosul, Iraq, Tel: 009647726438648; E-mail: dr.rawarawi@yahoo.com

ORCID: <https://orcid.org/0000-0003-2554-1121>

Keywords: Anatomical structures; Dental implants; Basic implant protocol; Success criteria; Clinical anatomy

<https://www.peertechz.com>

Abstract

Aims: In this article, we will reviews critically important basic structures routinely encountered in implant therapy. It can be a brief anatomical reference for beginners in the field of dental implant surgeries. Highlighting the clinical importance of each anatomical structure can be beneficial for fast informations refreshing. Also it can be used as clinical anatomical guide for implantologist and professionals in advanced surgical procedures.

Background: Basic anatomy understanding prior to implant therapy; it's an important first step in dental implant surgery protocol specifically with technology advances and the popularity of dental implantation as a primary choice for replacement loosed teeth. A thorough perception of anatomy provides the implant surgeon with the confidence to deal with hard or soft tissues in efforts to restore the exact aim of implantation whether function or esthetics and end with improving health and quality of life. Collection and citation of more than eighty published articles discuss anatomical importance in implant dentistry and reviews the clinical importance of each landmarks can affect the dental implant procedures in different situations.

Conclusion: Though knowledge and understanding of the anatomical basics before surgery can reduces unsolicited complications and reducing the success criteria subsequently affect patients satisfactions. However, certain anatomic sites may be challenging concerning treatment plan as maxillary sinus area of inferior alveolar nerve area.

Introduction

In general; there are dozens of studies discussing the dental implants different subjects elaborately; but limited researches focus on clinical importance of anatomical aspect in implants dentistry; in spite of knowing anatomy consider the first step of precise surgeries and is critically important.

Basic anatomy understanding prior to implant therapy; it's an important first step in dental implant surgery protocol specifically with technology advances and the popularity of dental implantation as a primary choice for replacement loosed teeth . Implantologist should be familiar with all anatomical landmarks, muscles attachments, vascularization and innervations for both soft tissues and bone. Good knowledge of oral structures will affect patient assessment and enable

smooth surgical and prosthetic procedures. Furthermore, careful perception of anatomy provides professionals with the confidence to deal with hard or soft tissues in efforts to restore the exact aim of implantation whether function or esthetics and end with improving health and quality of life.

Collection and citation of more than eighty published articles discuss anatomical importance in implant dentistry and reviews the clinical importance of each landmarks can affect the dental implant procedures in different situations.

In this review article, we will reviews critically important basic structures routinely encountered in implant therapy. It can be a brief anatomical reference for beginners in the field of dental implant surgeries. Highlighting the clinical importance of each anatomical structure can be beneficial for

fast informations refreshing. Also it can be used as clinical anatomical guide for implantologist and professionals in advanced surgical procedures.

Maxillary structures

Gingiva and palatal mucosa thickness: Gingiva and palatal epithelium thickness is 0.3 mm [1]. Lamina propria forming the supporting layer of the gingiva, whereas, mucosal layer with the lamina propria is supporting the palatal epithelium. Goaslind GD [2], stated that average gingival thickness ranges from 0.53 to 2.62 mm (mean, 1.56 mm) and Wara Aswapati N, also describe that palatal width varies from 2.0 to 3.7 mm, (2.8 mm forming the mean width) [3]. Periodontal probe with endodontic stopper can be used for palatal tissues thickness calculation (Figures 1,2).

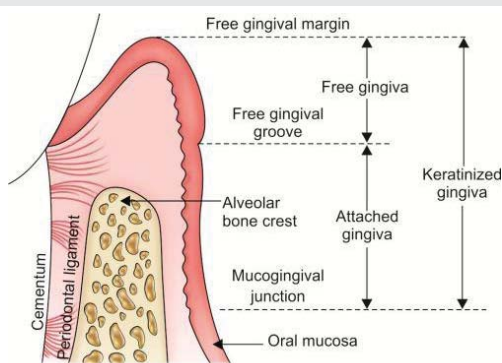


Figure 1: Anatomical Description of gingiva and palatal mucosa.

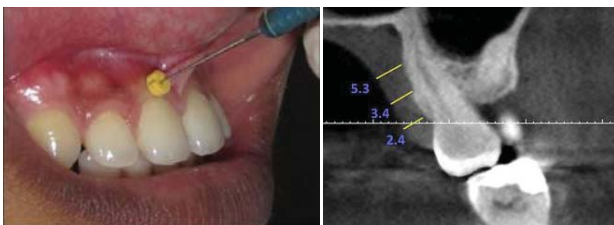


Figure 2: Measurement of thickness of gingiva.

Clinical importance: Abnormal position of implant can affect esthetic because of metal reflection of abutment shadow.

Nasopalatine foramen

Stenson foramen or the more familiar term incisive canals are vital anatomical landmarks forming two lateral canals noticeable in the nasopalatine foramen or incisive foramens [4]. These canals are functioning to transmit descending palatine vessels (anterior branches) and the nasopalatine nerves. In unresorbed ridge nasopalatine foramen situated about 7.4 mm from the labial surface and 4.6 mm wide, mean length 8.1mm as described by Jacobs R [4], exits as the incisive foramen (Figure 3).

Clinical importance: Incisive canal with its position can form obstacle to implant placement in the anterior region (incisor area). Creation of labial incision on the crest;

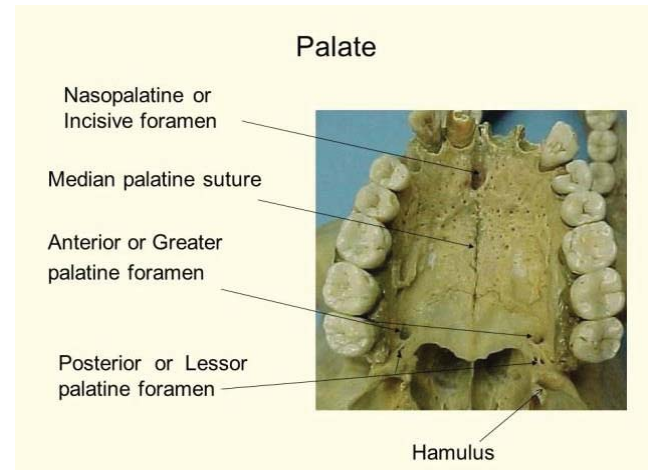


Figure 3: Anatomical Description of Palate.

surrounding the incisive papilla is essential to avoid splitting nasopalatine canal vessels [5]. Although bisecting the canal will not give a detrimental effect, however, numbness of the anterior palatal tissue will result in frequent cases [6]. According to Artzi [7], when a large canal was present, surgeon can move contents of the canal over without elimination and placed an implant. On the contrary, Rosenquist and Nystrom [8] approach and enucleated the contents, inserted a bone graft, and subsequently placed an implant. We usually angulate the implant and avoid the canal.

Infraorbital foramen

Infraorbital foramen is a significant landmark as it's the emergence point of the infraorbital nerve and blood vessels. The direct location of the foramen is in the infraorbital ridge 5mm inferiorly under the pupil of the eye, and easily palpable through the skin of the cheek [9].

Clinical importance: For avoidance of such critical landmark especially in lateral window surgery, 15mm from the alveolar ridge crest usually enough as the average height of the maxillary sinus is 36 to 45 mm [10] (Figure 4). Intraoral flap elevation should cease several millimeters inferior to it. However, in sever resorbed maxilla cases, alertness needs to be exercised avoiding nerve injuries.

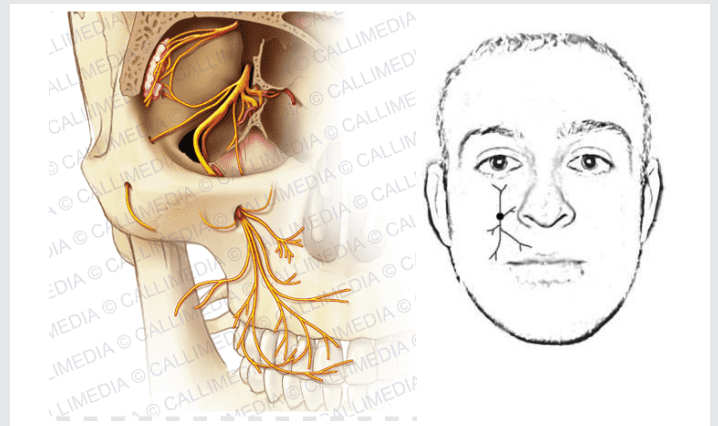


Figure 4: Anatomical Description of infra-orbital region.

Greater palatine foramen

The greater palatine vessels emerge from the foramen and cross the palate in anterior direction and the foramen located in the midway between the crestal bone and the median raphe. Foramen position is different according to articles, eighty six percent (86%) of cases showed the foramen situated opposite the third molar, in 13% between the 2nd and 3rd molar in 13% of cases, and opposite the 2nd molar in 1% of cases [11]. Other investigators [12] observed that the foramen was positioned opposite the 3rd molar in 55% of cases, between the between the 2nd and 3rd molar in 19% of cases, opposite the 2nd molar in 12% of cases, and distal to the 3rd molar in 14% of cases. Wang, [13] stated that 6mm is the mean distance from the center of the greater palatine foramen to the mid-sagittal plane of the hard palate (Figure 5).

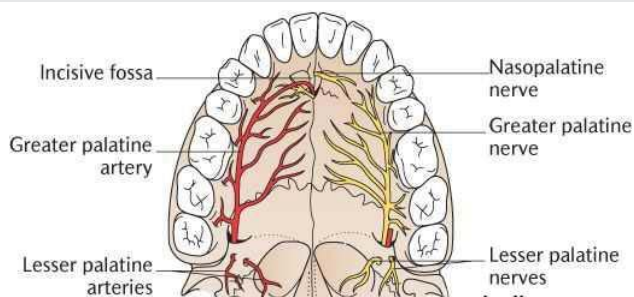


Figure 5: Anatomical Description of greater palatine foramen.

Clinical importance: Palatal artery injury can present a problem, because it can retract into the bone, which prevents ligation. For that precise location of the foramen should be determined prior to surgery.

Blood supply in the maxilla

The internal maxillary artery (Figure 6) arises from the external carotid artery behind the neck of the mandible and provides branches to several regions of the face: mandibular, pterygoid, and pterygopalatine [14].

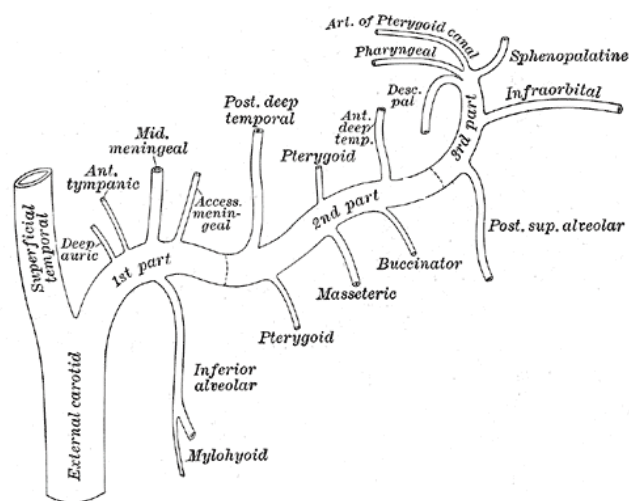


Figure 6: Anatomical Description of maxillary blood supply

Greater palatine artery

Greater palatine foramen is forming the emergence point of the descending palatine artery when the later navigates anteriorly in a slit present in the medial side of the hard palate ends within the incisive canal [15]. After enters the incisive canal it anastomoses with the nasopalatine branch of the sphenopalatine artery. Monnet-Corti, [16] reported that "the distance from the gingival margin to the greater palatine artery ranged from 12.07 – 2.9 mm in the canine area to 14.7 – 2.9 mm at the mid-palatal aspect of the second molar level". Reiser GM stated in his article that distance of palatine artery from the cemento-enamel junction can be calculated depends on palatal vault shape as low vault (flat), average and high vault (U-shaped) respectively (7mm, 12 mm, 17 mm) [17]. The mean palatal vault height for males and females is 14.9 and 12.7 mm, respectively [17].

Clinical importance: With respect to the greater palatine artery, connective tissue graft can be complicated practically if the palatal vault height not assessed precisely. It is advantageous to leave 2 mm distance away from the artery and the end of the surgical incision to perform smooth surgery without causing traumatic injuries to the artery [17].

Spheno palatine artery

The sphenopalatine artery arises from same named foramen pass to insert to the superior meatus of the nose [15,18]. It is branching to posterior and medial lateral nasal arteries. Give supply to conchae, posteromedial and posterior wall of the maxillary sinus.

Clinical importance: In sinus lift surgeries, caution must be exercised to avoid damaging these vessels if the procedure is being extended to the posterior wall of the sinus.

Anterior nasal spine

Sharp bony process formed as forward elongation of the maxillae [19]. It's positioned below the nose at lower margin of the anterior aperture exactly in midline.

Clinical importance: It is used as a landmark for the pre maxilla surgeries in flap advancement preparation. Flaps should not extend beyond the spine because the tissue is thin, and it is possible to penetrate through the tissue into the nose (Figure 7).

Maxillary innervations

Maxillary nerve supply sensation to the palate [20]. Sensory branches are greater palatine nerve supplying the gingiva, mucous membranes, and most of the hard palate glands [20]. Anterior part of the hard plate supplied through nasopalatine on the contrary soft palate innervated by lesser palatine branch [20]. Anterior teeth with the gingival area supplied by infraorbital nerve which also innervate maxillary sinus mucosa, lower eyelid and conjunctiva furthermore supply part of the nose and the superior lip [21]. Maxillary bone posteriorly supplied through posterior superior nerve including sinus, and molar teeth [20] (Figure 8).

Maxillary sinus

One of most imperative anatomical structure located in maxilla is maxillary sinus which considered as hugest paranasal sinus. It shaped as pyramid. Average dimensions are 36–45mm, 25– 35 mm, 38–45 mm respectively (height, width and length) [10]. The sinus known to have opening that situated in the middle meatus of the nose named as the ostium. Ostium is approximately 28.5mm away from the antral floor [22].The maxillary sinus is surrounded by six walls (Figure 9) [23].

Infraorbital nerve and blood vessels seated in the anterior wall of the sinus for this give blood supply anterior region of sinus mucosa through anterior superior alveolar arteries. Thin orbital floor are forming the superior wall, infraorbital canal involved in this wall. Pterygoid fossa separated from the antrum anatomically through the posterior wall (pterygomaxillary region), pterygoid plexus of veins and internal maxillary artery and superior alveolar nerve posterior branch are included in this wall. Medially the sinus is adjacent to the nasal fossa and separated by medial wall. Arterial supply formed from nasal mucosal vasculature, through sphenopalatine artery: posterior lateral nasal and posterior septal branches. Alveolar ridge is the sinus floor; the molar roots in some patients are extending to sinus floor. The floor may be 10 mm below the floor of the nasal cavity. Zygomatic-maxillary process is the lateral wall which provides access for the sinus graft procedure.

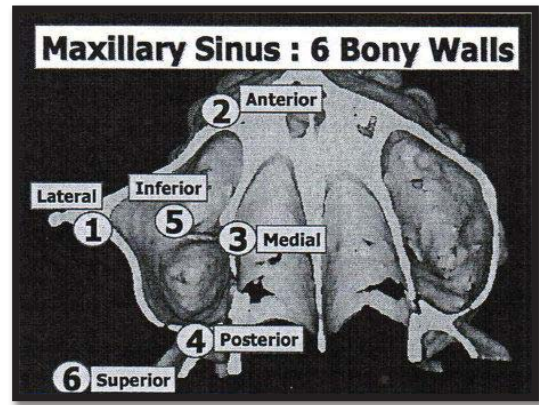


Figure 9: Anatomical Description of maxillary sinus.

Maxillary sinus has special characteristic anatomy in some patients which are special underwood's clefts or septa in 31.7% of cases in the premolar area, and they usually do not divide the antrum [24]. Schneiderian membrane is the soft tissue sac of the antrum with thickness (0.3 to 0.80) mm average [25].

Clinical importance: briefly the surgical anatomical advice is to avoid membrane perforation through sinus floor lifting procedures. As well as avoid overfilling the sinus with graft material more than 15mm to forestall possible obstructing the ostium opening ends with sinusitis. For these two advices; surgeon should proceed in latero-medial direction, because anterior-posterior elevation may be more prone to create a perforation (Figure 10).

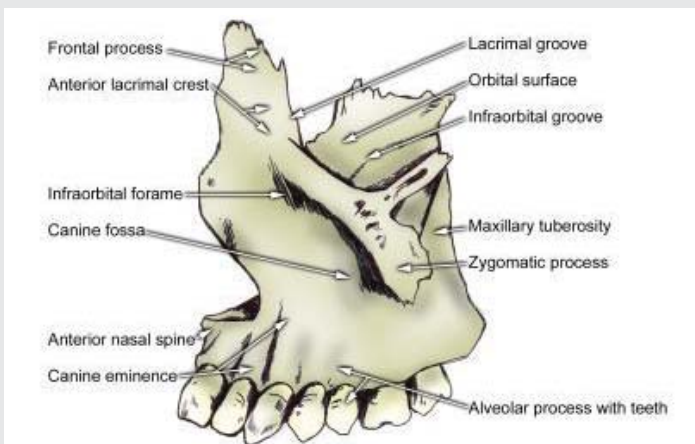


Figure 7: Anatomical Description of anterior nasal spine

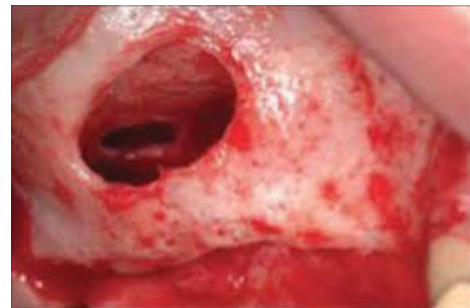

Figure 10: Anatomical Complication of Schneiderian membrane (perforation).

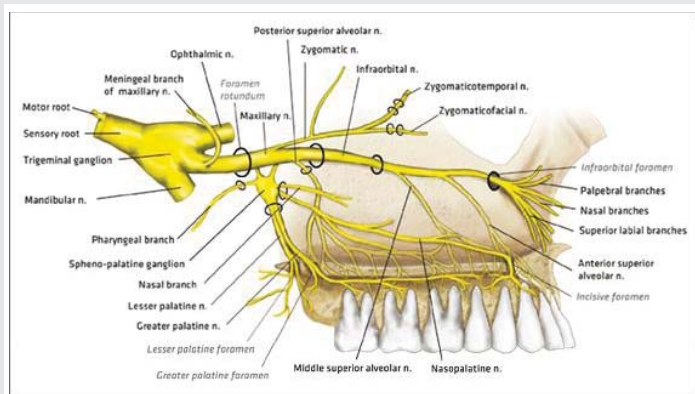


Figure 8: Anatomical Description of maxillary bone innervation.

In presences of multiple septa, operator can approach the sinus through more than one lateral window [24]. Beside, septa can be considered as alarm if an osteotomy for sinus floor elevation procedure is organized because of fracture difficulty of subantral floor beneath them.

There are numerous other relevant disputes of concern in maxillary sinus area dealing. Bony fenestration presence in diagnostic images whether in the alveolar ridge (inferior wall) or the lateral wall. Fugazzotto state that a split-thickness flap needs to be established over these defects avoiding Schneiderian membrane perforations. Consequently, the residual tissue over the bone defects must be pushed into the sinus, because it's difficult to separate lodged residual tissues from membrane [26].

Mandibular structures

Mandibular foramen: Mandibular foramen are inferiorly positioned to occlusal plane in 75% among adults in cadaver while at same level seen in about 22.5% and above it in 2.5%, respectively [27]. In another study [28] were 29.4%, 47.1%, and 23.5%, respectively, this can be related to race and cultural difference. Mandibular foramen length is 21mm on cadaver's assessment [29].

Clinical importance: According to these investigations, occlusal plane level of block injection will be not beneficial it is better to inject 6-10 mm superiorly to occlusal plane [30].

Inferior alveolar canal

Mandibular, maxillary and ophthalmic are branches of trigeminal nerve [31]. Inferior alveolar nerve (IAN) 2.2 mm thick [32] originated from the mandibular nerve which enters the mandibular canal (3.4 mm wide) through the lingual on the ramus medially.

Nerve, vascular bundles, and lymphatic vessels are forming contents of the canal. Nerve and artery run parallel to each other when crosses anteriorly, but its position changeable, superior or inferior to the nerve within the mandibular canal [32]. Cortical bone surrounding the canal which makes it challenged in drilling. The IAN may present in different anatomic configurations. The nerve may lower gently as it proceeds anteriorly, or there can be a sharp drop or the nerve can "drape downward in catenary fashion [curled as hanging between two points]" [33]. The IAN changing direction from lingual to buccal side and at the area of lower 1st molar located in the middle between bony cortical plates (buccal and lingual) [34]. Usually, the IAN (Figure 12) divides into the mental and incisive nerves in the premolar molar region [35]. The mental canal form the emergence of the mental nerve, mandibular canal extended anteriorly and end with as incisive canal [36]. The mandibular canal can show bifurcations in the superior-inferior plane latero-medial plane in 1% of patients which manifested as more than one mental foramen difficult to be diagnosed on panoramic or periapical films. [37]. Denio, et al. [38] evaluated cadavers to determine distance of IAN from the posterior teeth apices. The mean distance to the second molar, first molar, and premolars were 3.7, 6.9, and 4.7 mm, respectively. Similarly, Littner, et al. [39] reported that distance between the upper border of the canal and root apices of first and second molars were 3.5 to 5.4 mm. Other investigators [40] estimate that the canal was in intimate contacts that to the inferior border of the mandible and in some instances to adjacent to the molar teeth apices. Radiographically, Denio, et al. [38] reported that in "28% of patients the mandibular canal could not be clearly identified in the second premolar and first molar region on periapical radiographs". Therefore, panorama is preferable to view the canal than periapical radiographs. Cone beam tomography or CT scan can be used as indicated [41].

Clinical importance: Position variation makes surgeries near the canal is challenges and need skilled hands to avoid

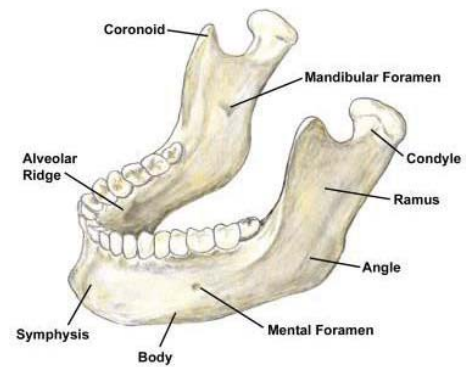


Figure 11: Anatomical Description of mandible.

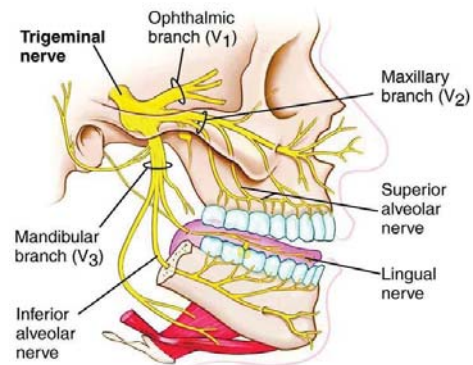


Figure 12: Anatomical Description Inferior Alveolar Canal.

inadvertently penetration ends with neurologic damage without eliciting bleeding and vice versa. Gentle perception is mandatory during nerve translocations procedure prior to implantation, feeling the softer cancellous bone is the termination point of the cortical bone drilling [33].

Anderson LC [33] advice that "during Implants drilling, however, clinicians should not rely on tactile feedback to signal the canal is about to be penetrated, because a twist drill can enter the canal with little warning, a sudden decrease in resistance may give an erroneous impression that the canal has been breached". Therefore, it's crucial for precise radiographic distance details to be used, also drill stopper for safety drilling. For precise estimation of the canal radiographically, professionals can use markers of identified dimension when taking radiographs (e.g., 5-mm-diameter ball bearing).

Bucco-lingual direction of implant positioning in relation to IAN can be unsafe strategy without the support of computed tomography (CT). Canal bifurcations also need to be evaluated before any surgeries in the area [41].

Mental foramen and nerve

Commonly, mental foramen is the emerging point of the mental nerve [36]. Mental nerve are supplying sensation to skin of the mental foramina area, lower lip, chin, mucous membranes, and the gingiva until the 2nd premolar. In some circumstances it supplies the innervation for the incisor teeth [42]. The mental foramen position differs in both horizontally

and vertically, and these variations can be linked to race, for example, horizontally position can be found white individuals flanked by the premolar apices [43] and next to the apex of the second mandibular premolar among Chinese subjects [44]. Atypically, the foramen may be situated by the canine or the first molar [44,45].

The position of the foramina also varies in the vertical plane [43]. Pertinently, in study prepared by Fishel D, [43], for detection of mental nerve of first premolar area in 936 patients, he reported that the foramen was "situated coronal to the apex in 38.6% of cases, at the apex in 15.4% of cases, and apical to the apex in 46.0% of cases. The foramen's location, in relation to the second premolar, was coronal to the apex in 24.5% of cases, at the apex in 13.9% of cases, and apical to the apex in 61.6% of cases". Thus, careful maneuver should be employed, especially in immediate implantations procedures in the premolar area, because of coronally positioned foramen seen in 25% to 38% of cases in relation to bicuspid's apex [43].

As we discuss earlier the IAN loops back to emerge from the foramen when it course inferio-anterioly to the mental foramen. This is known as the anterior loop of the mental foramen [46]. Identifying and measuring the size of the anterior loop is vital and can be done by using varied diagnostic methods: Patients panoramic films, cadaver panoramic films with markers, cadaver periapical films, CT scans of patients, and surgical cadaver dissections [47,48] (Figures 13-15).

Clinical importance: Thus, mental nerve exact location should be identified before implant insertion. First, radiographical determination in relation to premolar region should be utilized. In premolar region creation of a vertical incision mesially to the canine and flap reflected. Wet gauze used to permit safe elevation extend apically and expose the mental foramen roof, then gentle pushing of the gauze by periosteal elevator apically; the nerve is exposed [47]. Direct measurement of the distance is take place between the coronal aspect of the foramen and the alveolar crest by use of a periodontal probe; permit 2mm safety distance in choosing correct implant length from the nerve [47,49].

The mental nerve comes out of the mental canal, which is angled upward from the mandibular canal [50]. Therefore, it should be noted that the inferior alveolar nerve is lateral and apical to the mental foramen. It's preferable to provide safe distance more than 2mm anterior to the mental foramen,

Anterior loop presence should be detected by CT scan if other diagnostic elements fail to notify correctly. In this regard, assess opening of distal aspect of the foramen by curved probe (e.g., Naber's 2N probe) in gentle and careful manner not to injure the nerve.

Mandibular incisive canal

Mandibular canal continued as incisive canal mesial to the mental foramen (Figure 16). It can be seen truly in 80% of cases in middle third of mandible [51]. The incisive nerve supplies innervation to the six anterior teeth. It usually narrows with 1.8

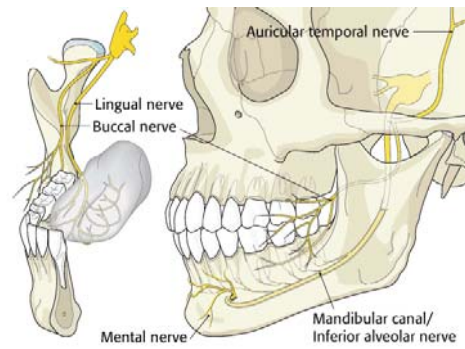


Figure 13: Anatomical Description of Mental Foramen and Nerve.

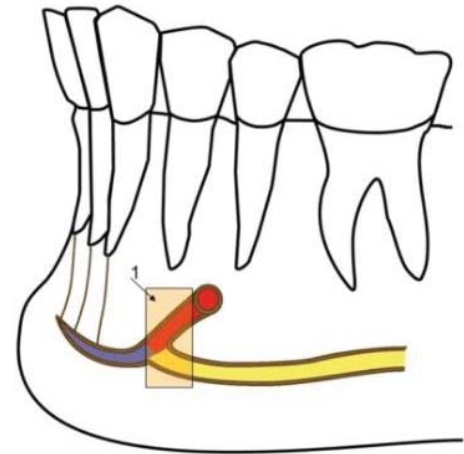


Figure 14: Anatomical Description of mental loop.

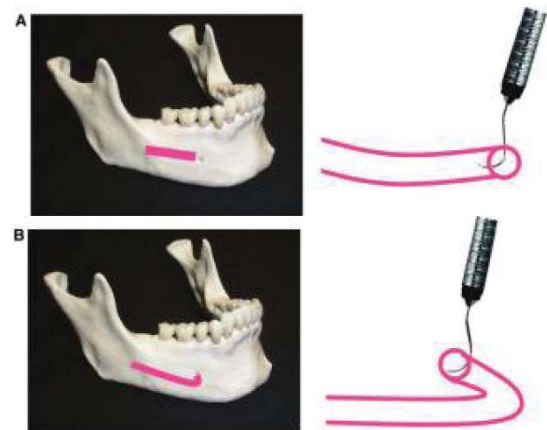


Figure 15: Clinical Examination of mental loop Presence by distal placement of the probe into the mental foramen A) If the probe can enter so reveals that mental canal is patent, no anterior loop (Curvature).

B) If mental canal is not patent, that mean an anterior loop is present. (Figure slightly modified from reference 66).

– 0.5 mm width [52]. The nerve typically terminates apically to either lateral incisor or sometimes central incisor [52]. Jacobs [53] evaluate 545 panoramic films for diagnostic appearance of the incisive canal, he notices that 15% of the films show its presence. On the contrary, it's shown on 93% of CT scans.

Clinical importance: Patients can suffer pain or slight discomfort in presence large incisive nerve canal [54] or

in some cases postoperative pain can be severe need implant removal [55].

Lingual foramen and lateral canals

Minute vascular canals with mean diameter 0.7 mm and 0.6 mm are usually present in the midline and lateral to the midline. One to five canals per patient can be seen as described by Gahleitner [56] (Figure 17). In skull dissection research show that foramen noticed in 99% of the mandibles [57]. While radiographically it noticed in only 49% of the periapical films depending on the beam angulations [56].

Clinical importance: Midline insertion of implants can be complicated by bleeding from this site if larger canal exist [59]. Guide pin use can help to complete the operation.

Submental and sublingual arteries

The submental artery originated from facial artery [60] while lingual artery gives off the sublingual artery, the average both artery diameter is 2mm. [61]. The sublingual artery pass to supply the floor of the mouth crossing over the mylohyoid muscle [61]. The submental artery often navigates in inferior direction crossing mylohyoid muscle but might pierce the mylohyoid muscle as noticed in 41% of cadavers. These arteries pass in close proximity to lingual plate [62] (Figure 18).

Clinical importance: Sublingual or submandibular hematoma in the floor of the mouth can be seen if inadvertent penetration of lingual cortical plate during drilling preparations [63]. Swelling and tongue pressure superior and inferior direction can affect airway causing distress [64,65]. Eventually simple implant procedure can ends with aggressive medical and perhaps surgical maneuvers if an airway crisis sustained. Flap reflection and elevation also can cause arterial injuries in the lingual side, so careful and proper visualization and elevation should be done to avoid unintentional perforations.

Submandibular and sublingual fossae

These two depressions are presented on the mandibular medial surface forming compartments for the salivary glands. Mylohyoid line separates these compartments. Inferiorly to the line submandibular fossa embraces the submandibular gland [66]. On the contrary shallow slit sublingual fossa is positioned superior to the line and contain the sublingual gland [67] (Figure 19). Computerized Tomography Scan (CTS) used to

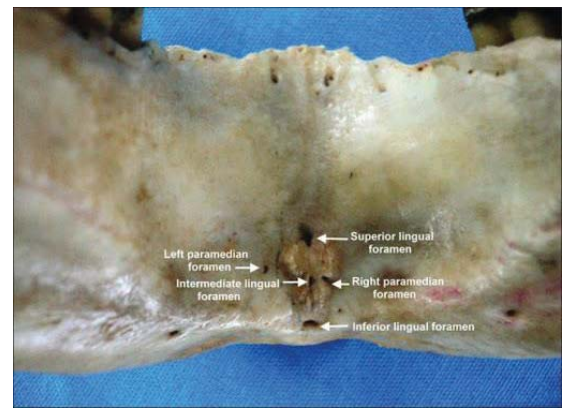


Figure 17: Anatomical Description of Lingual Foramen.

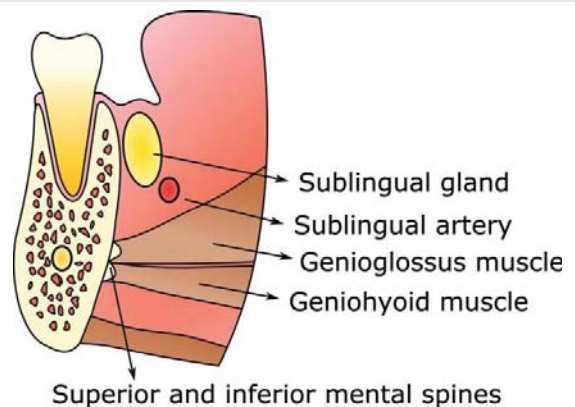


Figure 18: Anatomical Description of blood supply.

evaluate the depth of these concavities show that 6 mm depth were reported in 2.4% [62].

Clinical importance: The submandibular and sublingual fossae must be palpated prior to osteotomy development avoiding inadvertent lingual plate perforations in large undercut presence, resulting in hemorrhaging. A CTS with radiopaque markers provides the most accurate information.

Lingual and mylohyoid nerves

Lingual nerve is branch arise from mandibular nerve [68]. Give sensory supply to anterior two-thirds of the tongue and the lingual tissues. The lingual nerve is usually "located 3 mm apical to the osseous crest and 2 mm horizontally from the lingual cortical plate" [69]. Yet, in 15% to 20% of cases, can give various positions to be at or above the bone crest in wisdom tooth area [70]. (Figure 20).

Clinical importance: Lingual nerve injury can be unwanted complication in implant surgery in the posterior region, when unskilled lingual flap reflection takes place. For avoiding nerve injury, it should be protected gently with elevator to exclude pressure traction. Paresthesia further more vertical relaxant incisions should be avoided. Instead of, buccal incision distal to the second molar can perform safe additional space vision [70].

Mylohyoid nerve is a branch supplying the mylohyoid muscle originated from of the inferior alveolar nerve prior to

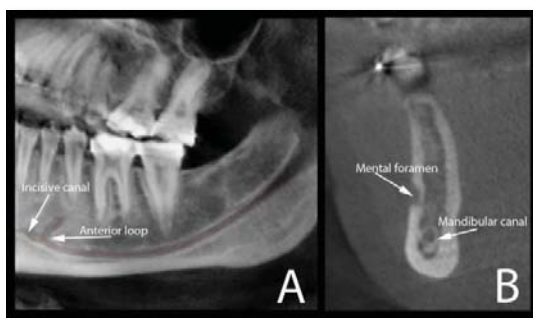


Figure 16: Anatomical Description of Mandibular Incisive Canal.

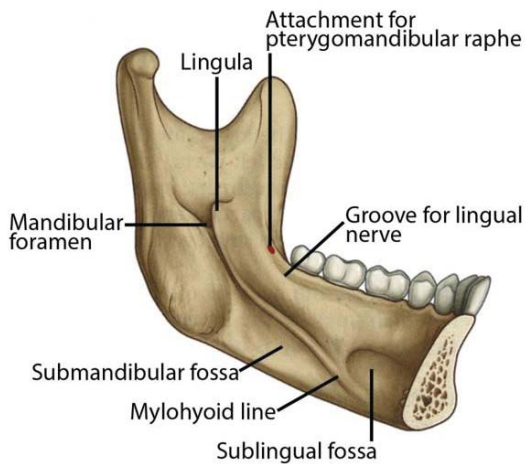


Figure 19: Anatomical Description of Submandibular and Sublingual Fossae.

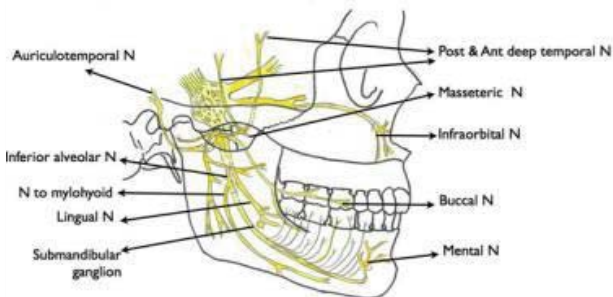


Figure 20: Anatomical Description of Lingual and Mylohyoid Nerves.

mandibular foramen entrance [70]. Also give innervation to the digastric muscle, anterior belly only.

Clinical importance: It can give accessory sensory innervation to mandibular teeth making difficult to perform complete anesthesia [71,72]. Lingual side anesthesia in posterior area can give good solution for such problem [72].

Long buccal nerve

Buccal gingiva and cheek mucosa innervated by long buccal nerve in retromolar area ends in second premolar. Long buccal nerve arise from the infra temporal fossa pass through the heads of pterygoid muscle giving sensory innervation [73].

Clinical importance: Turner's variation presence considered as important complication can face the professional where the nerve emerges from retromolar fossa special foramen so traumatic injury can result in gingiva and mucosa paresthesia [74].

Muscles attached to the mandible

There are 26 muscles attached to the mandible (Figure 21), we discuss the only concerned with dental implants surgeries [75].

Mentalis muscle

Mandibular incisive fossa gives the origin of paired tiny

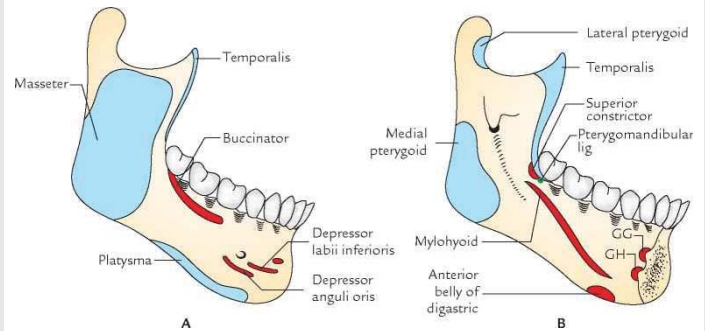


Figure 21: Anatomical Description of Muscles Attached to the Mandible.

muscles known as mentalis muscle which inserts into the chin [76]. The muscle fibers control lower lip elevations as the fibers crosses inferiorly

Clinical importance: Full muscular release from its protuberances can affect facial appearance as consequence to disturbed muscular contraction giving the double chin facial appearance (witch's chin). Avoiding this maneuver tow layers suturing technique should followed

Mylohyoid muscle

Two flat arms serve as sling supporting the floor of the mouth and positioned inferior to the tongue [78]. It has long origin extend along the mandibular body medially from the symphysis to the last molar overlying the digastric muscles given final insertion on the hyoid bone. For this significant position it forms imperative anatomic landmarks separating the sublingual fossa which situated superior to the muscle from the inferiorly seated submandibular fossa.

Clinical importance: Have Limited role in implant surgery, only in certain advanced cases where lingual flap advancement indicated or occasional use of guided bone regeneration procedures (GBR)

Genial tubercles (genioglossus and geniohyoid muscles)

The genial tubercles are tiny, four bony heights, can be seen in the mandibular bone lingually seated on both side near to inferior border. Genial tubercle forming attachment of the geniohyoid and genioglossus muscles [79]. The two superior tubercles serve as the origin of genioglossus muscle while the inferiorly positioned are serve as geniohyoid muscle origin from the inferior genial tubercles. In the center between these tubercles, lingual foramen can be seen. [80].

Clinical importance: If there is progressive bone resorption anteriorly, might alter the superior tubercle height in relation to superior level of the ridge. When flaps elevated surgically for access, avoid complete reflection of the genioglossus muscle from the tubercles because posterior retraction of the tongue to the throat can occur and the airway obstruction can be complicate the procedure [81].

Depressor anguli oris and depressor

Labii inferioris: Mental foramen is surrounded by 2



muscles "depressor anguli oris (triangularis) and depressor labii inferioris (quadratus labii inferioris)" [82].

Clinical importance: In regard to their position it's usual to release them if mental nerve surgeries is needed by using wet gauze pieces to protect the nerve and reflect the muscles smoothly.

Buccinator and orbicularis oris muscles

Strong submucosal attachment to both to the cheek and lip through buccinator muscle and orbicularis oris muscle [82].

Clinical importance: These muscles might be incised if coronal positioned flaps in indicated to promote primary soft tissues closure in advanced surgeries or in case of GBR use

Masseter muscle

The masseter muscle consists of two segments: superficial and deep [83]. The zygomatic arch and zygomatic process of the maxilla are forming the superficial part origin of the muscles [83]. It inserts into the mandibular angle and ramus area, lateral surface. The deep portion arises from the zygomatic arch and inserts into the mandibular ramus superior part and into the coronoid process laterally.

Clinical importance: Masseter muscle can be is freed from the ramus in bone graft harvesting after elevation of the periosteum in this region.

Conclusion

All implantologist seek for high rate success criteria in dental implants; with advanced technology nowadays we can see that dental implant procedures gain more publicity all over the worlds. Though knowledge and understanding of the anatomical basics before surgery can reduces un wanted complications and reducing the success criteria subsequently affect patients satisfactions. However, certain anatomic sites may be challenging concerning treatment plan as maxillary sinus area of inferior alveolar nerve area. For advanced surgeries it's essential and vital to have good anatomical understanding with proper training to perform smooth success implants.

References

- Muller HP (2004) Anatomy and physiology. In: Periodontology: The Essentials. Stuttgart, Germany: Thieme Medical Publishers 5.
- Goaslind GD, Robertson PB, Mahan CJ, Morrison WW, Olson JV (1977) Thickness of facial gingiva. J Periodontol 48: 768-771. [Link: https://bit.ly/32FahrN](https://bit.ly/32FahrN)
- Wara-aswapati N, Pitiphat W, Chandrapho N, Rattanayatikul C, Karimbux N (2001) Thickness of palatal masticatory mucosa associated with age. J Periodontol 72: 1407-1412. [Link: https://bit.ly/3bdfmFTN](https://bit.ly/3bdfmFTN)
- Jacobs R, Mraiwa N, Van Cleynenbreugel J, Sanderink G, Schutyser F, et al. (2004) The nasopalatine canal revisited using 2D and 3D CT imaging. Dentomaxillofac Radiol 33: 396-402. [Link: https://bit.ly/2Z6jpoz](https://bit.ly/2Z6jpoz)
- Sclar AG (2003) Surgical techniques for management of peri-implant soft tissues. In: Soft Tissue Esthetic Considerations in Implant Therapy. Chicago: Quintessence Books 6-62.

- Gary GS, John C, Dennis PT (2008) Practical Application of Anatomy for the Dental Implant Surgeon. J Periodontol 79: 1833-1846. [Link: https://bit.ly/3hMKxA3](https://bit.ly/3hMKxA3)
- Artzi Z, Nemcovsky CE, Bitlitum I, Segal P (2000) Displacement of the incisive foramen in conjunction with implant placement in the anterior maxilla without jeopardizing vitality of nasopalatine nerve and vessels: A novel surgical approach. Clin Oral Implants Res 11: 505-510. [Link: https://bit.ly/3jvclt6](https://bit.ly/3jvclt6)
- Rosenquist JB, Nystrom E (1992) Occlusion of the incisal canal with bone chips. A procedure to facilitate insertion of implants in the anterior maxilla. Int J Oral Maxillofac Surg 21: 210-211. [Link: https://bit.ly/3bnKc4F](https://bit.ly/3bnKc4F)
- Bennet CR (1974) Manheim's Local Anesthesia and Pain Control in Dental Practice. St. Louis: C.V. Mosby 92.
- Van den Bergh JP, Ten Bruggenkate CM, Disch FJ, Tuinzing DB (2000) Anatomical aspects of sinus floor elevations. Clin Oral Implants Res 11: 256-265. [Link: https://bit.ly/3lyAIYR](https://bit.ly/3lyAIYR)
- Sujatha N, Manjunath KY, Balasubramanyam V (2005) Variations of the location of the greater palatine foramina in dry human skulls. Indian J Dent Res 16: 99-102. [Link: https://bit.ly/3lGu2rR](https://bit.ly/3lGu2rR)
- Jaffar AA, Hamadah HJ (2003) An analysis of the position of the greater palatine foramen. J Basic Med Sc 3: 24-32. [Link: https://bit.ly/2EyoAln](https://bit.ly/2EyoAln)
- Wang TM, Kuo KJ, Shih C, Ho LL, Liu JC (1988) Assessment of the relative locations of the greater palatine foramen in adult Chinese skulls. Acta Anat [Basel] 132: 182-186. [Link: https://bit.ly/31Nirzj](https://bit.ly/31Nirzj)
- Gray H (1966) Anatomy of the Human Body, 28th ed. Goss CM, ed. Philadelphia: Lea & Febiger; 590.
- Norton NS (2007) Netter's Head and Neck Anatomy for Dentistry. Philadelphia: Saunders 372.
- Monnet-Corti V, Santini A, Glise JM, Fouque-Deruelle C, Dillier FL, et al. (2006) Connective tissue graft for gingival recession treatment: Assessment of the maximum graft dimensions at the palatal vault as a donor site. J Periodontol 77: 899-902. [Link: https://bit.ly/34MP01X](https://bit.ly/34MP01X)
- Reiser GM, Bruno JF, Mahan PE, Larkin LH (1996) The subepithelial connective tissue graft palatal donor site: Anatomic considerations for surgeons. Int J Periodontics Restorative Dent 16: 130-137. [Link: https://bit.ly/3hJSFkV](https://bit.ly/3hJSFkV)
- Norton NS (2007) Netter's Head and Neck Anatomy for Dentistry. Philadelphia: Saunders 299: 301.
- Norton NS (2007) Netter's Head and Neck Anatomy for Dentistry. Philadelphia: Saunders 287.
- Norton NS (2007) Netter's Head and Neck Anatomy for Dentistry. Philadelphia: Saunders 384.
- Norton NS (2007) Netter's Head and Neck Anatomy for Dentistry. Philadelphia: Saunders 90: 305.
- Uchida Y, Goto M, Katsuki T, Akiyoshi T (1998) A cadaveric study of maxillary sinus size as an aid in bone grafting of the maxillary sinus floor. J Oral Maxillofac Surg 56: 1158-1163. [Link: https://bit.ly/2YR1amH](https://bit.ly/2YR1amH)
- Misch CE (1999) The maxillary sinus lift and sinus graft surgery. In: Misch CE, ed. Implant Dentistry, 2nd ed. St Louis: CV Mosby; 469-470.
- Ulm CW, Solar P, Krennmair G, Matejka M, Watzek G (1995) Incidence and suggested surgical management of septa in sinus-lift procedures. Int J Oral Maxillofac Implants 10: 462-465.
- Mogensen C, Tos M (1977) Quantitative histology of the maxillary sinus. Rhinology 15: 129-140. [Link: https://bit.ly/350StKH](https://bit.ly/350StKH)
- Fugazzotto PA, Vlassis J (2003) A simplified classification and repair system for sinus membrane perforations. J Periodontol 74: 1534-1541. [Link: https://bit.ly/34Ppd9s](https://bit.ly/34Ppd9s)



27. Nicholson ML (1985) A study of the position of the mandibular foramen in adult human mandible. *Anat Rec* 212: 110-112. [Link: https://bit.ly/3IAQUJd](https://bit.ly/3IAQUJd)
28. Mbajjorgu EF, Ekanem AU (2000) A study of the position of the mandibular foramen in adult black Zimbabwean mandibles. *Cent Afr J Med* 46: 184-190. [Link: https://bit.ly/32D2x9S](https://bit.ly/32D2x9S)
29. Menke RA, Gowgiel JM (1979) Short-needle block anesthesia at the mandibular foramen. *J Am Dent Assoc* 99: 27-30. [Link: https://bit.ly/2YOh6Gp](https://bit.ly/2YOh6Gp)
30. Malamed SF (1986) *Handbook of Local Anesthesia*. St Louis: Mosby 183-193.
31. Norton NS (2007) *Netter's Head and Neck Anatomy for Dentistry*. Philadelphia: Saunders 86-96.
32. Ikeda K, Ho KC, Nowicki BH, Haughton VM (1996) Multiplanar MR and anatomic study of the mandibular canal. *AJNR Am J Neuroradiol* 17: 579-584. [Link: https://bit.ly/3gGmzFf](https://bit.ly/3gGmzFf)
33. Anderson LC, Kosinski TF, Mentag PJ (1991) A review of the intraosseous course of the nerves of the mandible. *J Oral Implantol* 17: 394-403. [Link: https://bit.ly/3gRrxU5](https://bit.ly/3gRrxU5)
34. Miller CS, Nummikoski PV, Barnett DA, Langlais RP (1990) Cross-sectional tomography. A diagnostic technique for determining the buccolingual relationship of impacted mandibular third molars and the inferior alveolar neurovascular bundle. *Oral Surg Oral Med Oral Pathol* 70: 791-797. [Link: https://bit.ly/2GdMacd](https://bit.ly/2GdMacd)
35. Wadu SG, Penhall B, Townsend GC (1997) Morphological variability of the human inferior alveolar nerve. *Clin Anat* 10: 82-87. [Link: https://bit.ly/2QBHrmw](https://bit.ly/2QBHrmw)
36. Mraiwa N, Jacobs R, van Steenberghe D, Quirynen M (2003) Clinical assessment and surgical implications of anatomic challenges in the anterior mandible. *Clin Implant Dent Relat Res* 5: 219-225. [Link: https://bit.ly/3IAoM8L](https://bit.ly/3IAoM8L)
37. Dario LJ (2002) Implant placement above a bifurcated mandibular canal: A case report. *Implant Dent* 11: 258-261. [Link: https://bit.ly/3IGw9vN](https://bit.ly/3IGw9vN)
38. Denio D, Torabinejad M, Bakland LK (1992) Anatomical relationship of the mandibular canal to its surrounding structures in mature mandibles. *J Endod* 18: 161-165. [Link: https://bit.ly/2YPjij3](https://bit.ly/2YPjij3)
39. Littner MM, Kaffe I, Tamse A, Dicapua P (1986) Relationship between the apices of the lower molars and mandibular canal – A radiographic study. *Oral Surg Oral Med Oral Pathol* 62: 595-602. [Link: https://bit.ly/3IBJAWH](https://bit.ly/3IBJAWH)
40. Saralaya V, Narayana K (2005) The relative position of the inferior alveolar nerve in cadaveric hemi-mandibles. *Eur J Anat* 9: 49-53. [Link: https://bit.ly/3hMGa80](https://bit.ly/3hMGa80)
41. Misch CE (2008) Diagnostic imaging techniques. In: Misch CE, ed. *Contemporary Implant Dentistry*, 3rd ed. St Louis: CV Mosby 38-67.
42. Pogrel MA, Smith R, Ahani R (1997) Innervation of the mandibular incisors by the mental nerve. *J Oral Maxillofac Surg* 55: 961-963. [Link: https://bit.ly/34MEisr](https://bit.ly/34MEisr)
43. Fishel D, Buchner A, Hershkowitz A, Kaffe I (1976) Roentgenologic study of the mental foramen. *Oral Surg Oral Med Oral Pathol* 41: 682-686. [Link: https://bit.ly/2DeB9GI](https://bit.ly/2DeB9GI)
44. Wang TM, Shih C, Liu JC, Kuo KJ (1986) A clinical and anatomical study of the location of the mental foramen in adult Chinese mandibles. *Acta Anat [Basel]* 126: 29-33. [Link: https://bit.ly/31HCRT8](https://bit.ly/31HCRT8)
45. Ngeow WC, Yuzawati Y (2003) The location of the mental foramen in a selected Malay population. *J Oral Sci* 45: 171-175. [Link: https://bit.ly/2QS8tX7](https://bit.ly/2QS8tX7)
46. Jalbout Z, Tabourian G (2004) *Glossary of Implant Dentistry*. Upper Montclair, NJ: International Congress of Oral Implantologists; 16. [Link: https://bit.ly/2YRsXnb](https://bit.ly/2YRsXnb)
47. Greenstein G, Tarnow D (2006) The mental foramen and nerve: Clinical and anatomical factors related to dental implant placement: A literature review. *J Periodontol* 77: 1933-1943. [Link: https://bit.ly/2G8aEDv](https://bit.ly/2G8aEDv)
48. Mardinger O, Chaushu G, Arensburg B, Taicher S, Kaffe I (2000) Anterior loop of the mental canal: An anatomical-radiologic study. *Implant Dent* 9: 120-125. [Link: https://bit.ly/3bbVZmd](https://bit.ly/3bbVZmd)
49. Misch CE (1999) Root form surgery in the edentulous mandible: Stage I implant insertion. In: Misch CE, ed. *Implant Dentistry*, 2nd ed. St Louis: CV Mosby 347-370.
50. Solar P, Ulm C, Frey G, Matejka M (1994) A classification of the intraosseous paths of the mental nerve. *Int J Oral Maxillofac Implants* 9: 339-344. [Link: https://bit.ly/3jySxeh](https://bit.ly/3jySxeh)
51. Polland KE, Munro S, Reford G, Lockhart A, Logan G, et al. (2001) The mandibular canal of the edentulous jaw. *Clin Anat* 14: 445-452. [Link: https://bit.ly/3bbMYtk](https://bit.ly/3bbMYtk)
52. Mraiwa N, Jacobs R, Moerman P, Lambrichts I, van Steenberghe D, et al. (2003) Presence and course of the incisive canal in the human mandibular interforaminal region: Two-dimensional imaging versus anatomical observations. *Surg Radiol Anat* 25: 416-423. [Link: https://bit.ly/3hM2r5X](https://bit.ly/3hM2r5X)
53. Jacobs R, Mraiwa N, Van Steenberghe D, Sanderink G, Quirynen M (2004) Appearance of the mandibular incisive canal on panoramic radiographs. *Surg Radiol Anat* 26: 329-333. [Link: https://bit.ly/2YRDL99](https://bit.ly/2YRDL99)
54. Romanos GE, Greenstein G (2008) The incisive canal: Considerations during implant dentistry: Case report and literature review. *Int J Oral Maxillofac*; in press. [Link: https://bit.ly/32H06mp](https://bit.ly/32H06mp)
55. Kohavi D, Bar-Ziv J (1996) Atypical incisive nerve. Clinical report. *Implant Dent* 5: 281-283. [Link: https://bit.ly/3406Xxl](https://bit.ly/3406Xxl)
56. Gahleitner A, Hofschneider U, Tepper G, Pretterklieber M, Schick S, et al. (2001) Lingual vascular canals of the mandible: Evaluation with dental CT. *Radiology* 220: 186-189. [Link: https://bit.ly/3ba2DJX](https://bit.ly/3ba2DJX)
57. McDonnell D, Reza Nouri M, Todd ME (1994) The mandibular lingual foramen: A consistent arterial foramen in the middle of the mandible. *J Anat* 184: 363-369. [Link: https://bit.ly/2Gd4geq](https://bit.ly/2Gd4geq)
58. Liang H, Frederiksen NL, Benson BW (2004) Lingual vascular canals of the interforaminal region of the mandible: Evaluation with conventional tomography. *Dentomaxillofac Radiol* 33: 340-341. [Link: https://bit.ly/2QS9oqx](https://bit.ly/2QS9oqx)
59. Longoni S, Sartori M, Braun M, Bravetti P, Lapi A, et al. (2007) Lingual vascular canals of the mandible: The risk of bleeding complications during implant procedures. *Implant Dent* 16: 131-138. [Link: https://bit.ly/3jrvr3m](https://bit.ly/3jrvr3m)
60. Hofschneider U, Tepper G, Gahleitner A, Ulm C (1999) Assessment of the blood supply to the mental region for reduction of bleeding complications during implant surgery in the interforaminal region. *Int J Oral Maxillofac Implants* 14: 379-383. [Link: https://bit.ly/3jdsEsT](https://bit.ly/3jdsEsT)
61. Martin D, Pascal JF, Baudet J, Mondie JM, Farhat JB, et al. (1993) The submental island flap: A new donor site. Anatomy and clinical applications as a free or pedicled flap. *Plast Reconstr Surg* 92: 867-873. [Link: https://bit.ly/2YRtTld](https://bit.ly/2YRtTld)
62. Quirynen M, Mraiwa N, van Steenberghe D, Jacobs R (2003) Morphology and dimensions of the mandibular jaw bone in the interforaminal region in patients requiring implants in the distal areas. *Clin Oral Implants Res* 14: 280-285. [Link: https://bit.ly/3lsPqRb](https://bit.ly/3lsPqRb)
63. Flanagan D (2003) Important arterial supply of the mandible, control of an arterial hemorrhage, and report of a hemorrhagic incident. *J Oral Implantol* 29: 165-173. [Link: https://bit.ly/2Den0ZT](https://bit.ly/2Den0ZT)
64. Kalpidis CD, Setayesh RM (2004) Hemorrhaging associated with endosseous implant placement in the anterior mandible: A review of the literature. *J Periodontol* 75: 631-645. [Link: https://bit.ly/3lGydnx](https://bit.ly/3lGydnx)



65. Niamtu J (2001) Near-fatal airway obstruction after routine implant placement. *Oral Surg Oral Med Oral Pathol Oral Radiol Endod* 92: 597-600. [Link: https://bit.ly/350VMBB](https://bit.ly/350VMBB)
66. Sharawy M (1995) *The Companion of Applied Anatomy*, vol. 1, 5th ed. Augusta, GA: Medical College of Georgia Printing Service 13.
67. Gray H (1966) *Anatomy of the Human Body*, 28th ed. Goss CM, ed. Philadelphia: Lea & Febiger 1196.
68. Norton NS (2007) *Netter's Head and Neck Anatomy for Dentistry*. Philadelphia: Saunders 382.
69. Behnia H, Kheradvar A, Shahrokhi M (2000) An anatomic study of the lingual nerve in the third molar region. *J Oral Maxillofac Surg* 58: 649-651. [Link: https://bit.ly/34MG0tR](https://bit.ly/34MG0tR)
70. Pogrel MA, Goldman KE (2004) Lingual flap retraction for third molar removal. *J Oral Maxillofac Surg* 62: 1125-1130. [Link: https://bit.ly/34J4Omu](https://bit.ly/34J4Omu)
71. Bennett S, Townsend G (2001) Distribution of the mylohyoid nerve: Anatomical variability and clinical implications. *Aust Endod J* 27: 109-111. [Link: https://bit.ly/2QG0DOo](https://bit.ly/2QG0DOo)
72. Stein P, Brueckner J, Milliner M (2007) Sensory innervation of mandibular teeth by the nerve to the mylohyoid: Implications in local anesthesia. *Clin Anat* 20: 591-595. [Link: https://bit.ly/32ESHUX](https://bit.ly/32ESHUX)
73. Norton NS (2007) *Netter's Head and Neck Anatomy for Dentistry*. Philadelphia: Saunders 234.
74. Turner-Iannacci A, Mozaffari E, Stoopler ET (2003) Mental nerve neuropathy: Case report and review. *CJEM* 5: 259-262. [Link: https://bit.ly/32J80vN](https://bit.ly/32J80vN)
75. Gray H (1966) *Anatomy of the Human Body*, 28th ed. Goss CM, ed. Philadelphia: Lea & Febiger 387-394.
76. Norton NS (2007) *Netter's Head and Neck Anatomy for Dentistry*. Philadelphia: Saunders 168.
77. Misch CE (1999) The division C mandible: Mandibular complete and unilateral subperiosteal implants. In: Misch CE, ed. *Implant Dentistry*, 2nd ed. St. Louis: The CV Mosby Company 434-435. [Link: https://bit.ly/3hlzTuh](https://bit.ly/3hlzTuh)
78. Norton NS (2007) *Netter's Head and Neck Anatomy for Dentistry*. Philadelphia: Saunders 356-357.
79. Baldissera EZ, Silveira HD (2002) Radiographic evaluation of the relationship between the projection of genial tubercles and the lingual foramen. *Dentomaxillofac Radiol* 31: 368-372. [Link: https://bit.ly/3hlzTuh](https://bit.ly/3hlzTuh)
80. Yin SK, Yi HL, Lu WY, Guan J, Wu HM, et al. (2007) Anatomic and spiral computed tomographic study of the genial tubercles for genioglossus advancement. *Otolaryngol Head Neck Surg* 136: 632-637. [Link: https://bit.ly/2EGdOhA](https://bit.ly/2EGdOhA)
81. Norton NS (2007) *Netter's Head and Neck Anatomy for Dentistry*. Philadelphia: Saunders 167.
82. Norton NS (2007) *Netter's Head and Neck Anatomy for Dentistry*. Philadelphia: Saunders 389.
83. Gray H (1966) *Anatomy of the Human Body*, 28th ed. Goss CM, ed. Philadelphia: Lea & Febiger 392.

Discover a bigger Impact and Visibility of your article publication with Peertechz Publications

Highlights

- ❖ Signatory publisher of ORCID
- ❖ Signatory Publisher of DORA (San Francisco Declaration on Research Assessment)
- ❖ Articles archived in worlds' renowned service providers such as Portico, CNKI, AGRIS, TDNet, Base (Bielefeld University Library), CrossRef, Scilit, J-Gate etc.
- ❖ Journals indexed in ICMJE, SHERPA/ROMEO, Google Scholar etc.
- ❖ OAI-PMH (Open Archives Initiative Protocol for Metadata Harvesting)
- ❖ Dedicated Editorial Board for every journal
- ❖ Accurate and rapid peer-review process
- ❖ Increased citations of published articles through promotions
- ❖ Reduced timeline for article publication

Submit your articles and experience a new surge in publication services (<https://www.peertechz.com/submit>).

Peertechz journals wishes everlasting success in your every endeavours.

Copyright: © 2020 Al-Rawee RY, et al. This is an open-access article distributed under the terms of the Creative Commons Attribution License, which permits unrestricted use, distribution, and reproduction in any medium, provided the original author and source are credited.