



Case Report

Gingival enlargements: A review

Anuja Namala¹, Dyamavva Halerolli¹, Preethi A Poonja², Prasanna Kumar Rao^{3*} and Raghavendra Kini⁴

¹Intern Student, Oral Medicine & Radiology, AJ Institute of Dental Sciences, Kuntikana, Mangalore 575004, Karnataka, India

²Assistant Professor, Oral Medicine & Radiology, AJ Institute of Dental Sciences, Kuntikana, Mangalore 575004, Karnataka, India

³Professor, Oral Medicine & Radiology, AJ Institute of Dental Sciences, Kuntikana, Mangalore 575004, Karnataka, India

⁴Professor and Head, Oral Medicine & Radiology, AJ Institute of Dental Sciences, Kuntikana, Mangalore 575004, Karnataka, India

Received: 10 February, 2021

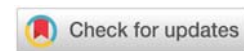
Accepted: 20 March, 2021

Published: 22 March, 2021

*Corresponding author: Dr. Prasanna Kumar Rao, Professor, Oral Medicine & Radiology, AJ Institute of Dental Sciences, Kuntikana, Mangalore 575004, Karnataka, India, Tel: +91 9900151108; E-mail: drjpkrao@gmail.com

Keywords: Generalized; Papillary; Gingival over growth

<https://www.peertechzpublications.com>



Abstract

Alteration in size of gingiva is one of the clinical features of periodontal disease. Increase in size of gingiva, which is termed as gingival enlargement or gingival over growth is a common clinical sign of gingival disease and a matter of great clinical concern. Increase in size alters the physiologic contour of gingiva, creates areas of plaque accumulation, intereferes with regular oral hygiene procedures and creates aesthetic problems. In severe cases, it interefere with mastication and phonation. Enlargement may involve one or more components of gingiva. Depending on the involvement of components of gingiva and distribution, gingival enlargement can be Localized, genaralized, marginal, papillary, diffuse and discrete. Depending on etiology and pathogenesis, it can be classified as inflammatory enlargement, fibrotic enlargement, combined enlargement, enlargement associated with systemic conditions, neoplastic enlargement and false enlargements.

Introducion

Inflammatory gingival enlargement is most common type of over growth, which manifest because of increase in volume of gingival tissue in response to local microbial irritation. Inflammatory enlargement may be acute or chronic. Fibrotic gingival enlargement or non-inflammatory fibrous gingival over growth is belived to be the result of genetic predispostion or adverse effect of drug . Large number of drugs and genetic disorders are associated with occurance of gingival over growth in susceptible individuals. They may be [1],

- Drug induced gingival enlargement
- Idiopathic gingival enlargement

Drug induced gingival enlargement

The drugs that are reported to be associated with gingival over growth are anti-convulsants, immune suppresents and calcium channel blockers (Table 1). Despite their pharmacological

diversity all these drugs have similar mechanism of action at cellular level. They are known to inhibit intracellular calcium ion induced influx. Therefore the clinical features of gingival

Table 1: List of Drugs causes Gingival Enlargement.

Category	Generic Name	Trade Name
Anti-convulsants	<ul style="list-style-type: none"> • Phenytoin • Valproic acid • Carbamazepine • Vigabatrin 	<ul style="list-style-type: none"> • Dilantin • Depakene • Tegretol • sabril
Calcium channel blockers	<ul style="list-style-type: none"> • Amlodipine • Diltiazem • Felodipine • Isradipine • Nicardipine • Nifedipine • Nisoldipine • Verapamil 	<ul style="list-style-type: none"> • Norvasc • Cardizem • Plendil • Dyanacirc • Cardene • Nifedical • Sular • calan
Immunosuppresants	<ul style="list-style-type: none"> • Cyclosporine A • Tacrolimus • Mycophenolate mophetil • serolimus 	<ul style="list-style-type: none"> • Neoral • Prograf • Cellcept • Rapamunel

over growth (Figure 1), by these agents and even the histologic appearance are reported to have common characteristics such as increase in extra cellular ground substance, number of fibroblast and acanthosis of epithelium.

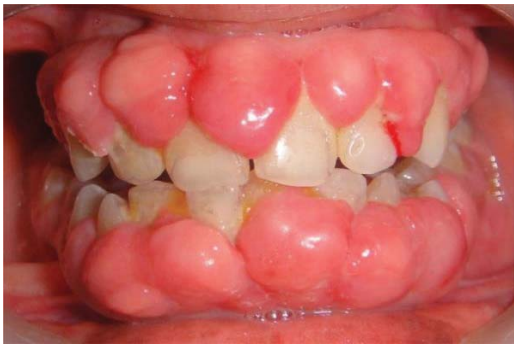

Figure 1: Generalized enlargement of marginal gingiva, attached gingiva and interdental papillae.

Anticonvulsants

These are the drugs which are used to control epileptic seizures. Clinically it may manifest as generalized hyperplasia in mouth, but it is most severe in maxillary and mandibular anterior region. The 1st change noted is a painless bead like enlargement of gingiva, starting with one or two interdental papillae. The surface of gingival shows an increase in stippling and finally a cauliflower, warty or pebbled surface. Hyperplasia may develop massively covering a considerable portion of the crown. They may interfere with occlusion, increase plaque accumulation, resulting in secondary inflammatory process [2].

Laboratory studies on phenytoin induced enlargement have observed fibroblast like cell proliferation, proliferation of epithelium, increased synthesis of Glycosaminoglycans sulfate and reduced degeneration of collagen. Phenytoin induced reduction of folic acid leads to degenerative changes in epithelium exacerbated in presence of inflammatory factors. The increased synthesis of testosterone metabolite by fibroblast can cause gingival enlargement [2].

Some studies have found that pre threshold serum phenytoin was directly associated with enlargement, while no association was found post threshold phenytoin and gingival enlargement. Girgis et al found a direct relationship between gingival enlargement in 50% of patients, while no relationship and even an inverse relationship was found in rest 50% [2].

Studies have demonstrated that oral hygiene procedures may limit the severity of the lesion but are unable alone to lead to the reversal of the condition [2].

Immunosuppressants

Cyclosporine is a potent immunosuppressive agent used to prevent organ transplant rejection and to treat several diseases of autoimmune origin. Clinically it is similar to that induced by dilantin. Mechanism of action of cyclosporine is not fully

understood; however, blood and cellular immunity response seems to be influenced by selective and reversible inhibition of T helper cells. There is disagreement between severity of gingival enlargement in blood and saliva. Some studies have reported that development of gingival enlargement requires a threshold of drug concentration in blood plasma, while its severity is not associated with the dose. The dosage 500mg is considered as threshold [3].

Calcium channel blockers

Calcium channel blockers induce direct dilation of coronary arteries and arterioles, improving the oxygen supply to the heart muscles. It is used in the treatment of acute and chronic coronary insufficiency. Gingival over growth occurs in 20% of cases. The stratified squamous epithelium covering the gingiva is thick and has a keratinized layer. The rete pegs are extremely long sometimes called "test pegs" with considerable confluence seen [4].

Calcium channel blockers affect the Ca metabolism by reducing the intracellular Ca flow and limiting the production of active collagenase. Gingival enlargement occurs by taking 30-100mg Nifedipine per day [4].

Idiopathic gingival enlargement

It is also termed as gingivostomatitis, elephantiasis, idiopathic fibromatosis, hereditary gingival hyperplasia and congenitally familial fibromatosis. It is a proliferative fibrous lesion that causes aesthetic and functional problems. Both genetically and pharmacologically induced forms of gingival enlargement exist. Clinically it is seen on attached gingiva, gingival margin and interdental papilla. It appears as pink, firm and leathery with pebbled surface. Teeth are completely covered. In severe cases jaw appears distorted due to bulbous enlargement [5].

Pregnancy induced gingival enlargement

The prevalence of pregnancy gingivitis changes from 35-100%. The gingiva shows increased level of inflammation often characterized by edema, color and contour change and propensity to bleed on gentle stimulation (Figure 2). The marginal gingiva tends to be more prominent than facial and lingual surfaces. An inflammatory reaction to the local irritants that occurs after 3rd month of pregnancy is called pregnancy tumor. This lesion appears as discrete, mushroom, flattened spherical masses that protrude from the gingival margin, more frequently in the interproximal space and are attached by sessile or pedunculated base [6].

Puberty induced gingival enlargement

It is an inflammatory type of gingival enlargement which occurs in both males and females in pubertal age groups. It involves mainly marginal and interdental gingiva (Figure 3). It is characterized by prominent bulbous interproximal papilla. After puberty the enlargement undergoes spontaneous reduction but does not disappear until local irritants are removed [7].

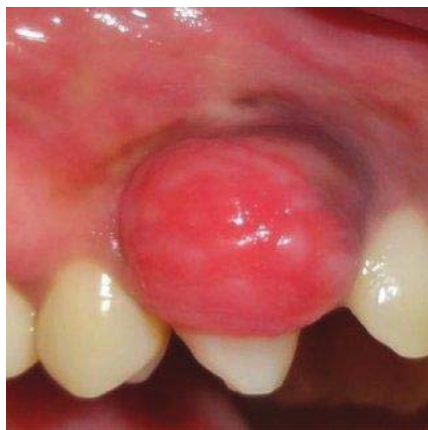

Figure 2: Discrete flattened spherical mass protruding from gingival margin.

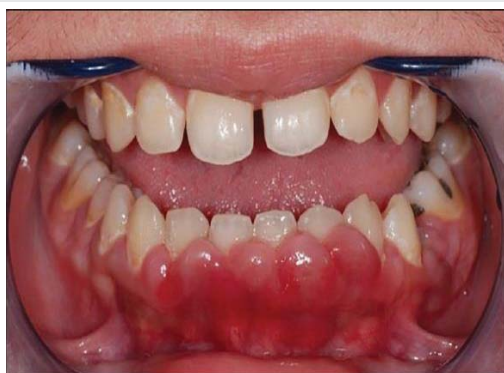

Figure 3: Bulbous enlargement seen in the interproximal area.

Management

Treatment for drug induced hyperplasia includes substitution with another drug. Sodium valproate has been used as alternative to dilantin sodium in management of epilepsy. Anti-hypertensives other than calcium channel blockers may be considered for replacement of Nifedipine. Tacrolimus has

been used successfully as calcium channel blocker. Most of the gingival enlargement during pregnancy can be prevented by removal of local irritants and institution of fastidious oral hygiene. Hyperplasia at puberty can be managed by removal of lesions along with elimination of irritating factors [8].

Conclusion

Gingival enlargement has varied presentations, hence diagnosis of these entities become challenging for the clinician. Detailed investigation is necessary. So prompt diagnosis and removal of the etiologic factors is the main treatment objectives.

References

1. Agrawal AA (2015) Gingival enlargements: Differential diagnosis and review of literature. *World J Clin Cases* 3: 779–788. [Link: https://bit.ly/39325W9](https://bit.ly/39325W9)
2. Bharti V, Bansal C (2013) Drug-induced gingival overgrowth: The nemesis of gingiva unraveled. *J Indian Soc Periodontol* 17: 182–187. [Link: http://bit.ly/3ra4QLy](http://bit.ly/3ra4QLy)
3. Greenberg KV, Armitage GC, Shiboski CH (2008) Gingival enlargement among renal transplant recipients in the era of new-generation immunosuppressants. *J Periodontol* 79: 453-460. [Link: http://bit.ly/3sbgMho](http://bit.ly/3sbgMho)
4. Quach H, Ray-Chaudhuri A (2020) Calcium channel blocker induced gingival enlargement following implant placement in a fibula free flap reconstruction of the mandible: a case report. *Int J Implant Dent* 6: 47. [Link: http://bit.ly/3c61Hlo](http://bit.ly/3c61Hlo)
5. Shah K, Khan K, Pandilwar PK, Unnikrishnan KSA, Sanap M, et al. (2020) Long standing Idiopathic gingival hyperplasia of oral cavity with invasion of maxillary sinus: A rare case report *Int J Surg Case Rep* 77: 62-66. [Link: http://bit.ly/3vMxHcl](http://bit.ly/3vMxHcl)
6. Chauhan SS, Pandey A, Raj A, Raj A (2014) A classical case of pregnancy induced gingival enlargement: A case Report. *Journal of Evolution of Medical and Dental Sciences* 3: 11104-11108. [Link: https://bit.ly/3c4pMiR](https://bit.ly/3c4pMiR)
7. Siddharth T (2017) Puberty Induced Gingival Enlargement. *Biomed J Sci Tech Res* 1. [Link: https://bit.ly/3vL67MJ](https://bit.ly/3vL67MJ)
8. Taylor BA (2003) Management of drug-induced gingival enlargement. *Aust Prescr* 26: 11-13. [Link: https://bit.ly/3cPaAp2](https://bit.ly/3cPaAp2)

Discover a bigger Impact and Visibility of your article publication with Peertechz Publications

Highlights

- ❖ Signatory publisher of ORCID
- ❖ Signatory Publisher of DORA (San Francisco Declaration on Research Assessment)
- ❖ Articles archived in worlds' renowned service providers such as Portico, CNKI, AGRIS, TDNet, Base (Bielefeld University Library), CrossRef, Scilit, J-Gate etc.
- ❖ Journals indexed in ICMJE, SHERPA/ROMEO, Google Scholar etc.
- ❖ OAI-PMH (Open Archives Initiative Protocol for Metadata Harvesting)
- ❖ Dedicated Editorial Board for every journal
- ❖ Accurate and rapid peer-review process
- ❖ Increased citations of published articles through promotions
- ❖ Reduced timeline for article publication

Submit your articles and experience a new surge in publication services (<https://www.peertechz.com/submission>).

Peertechz journals wishes everlasting success in your every endeavours.

Copyright: © 2021 Anuja N, et al. This is an open-access article distributed under the terms of the Creative Commons Attribution License, which permits unrestricted use, distribution, and reproduction in any medium, provided the original author and source are credited.

Citation: Anuja N, Halerolli D, Poonja PA, Rao PK, Kini R (2021) Gingival enlargements: A review. *J Dent Probl Solut* 8(1): 029-031. DOI: <https://dx.doi.org/10.17352/2394-8418.000100>