



Received: 23 August, 2021

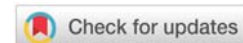
Accepted: 06 September, 2021

Published: 07 September, 2021

\*Corresponding author: Dr. Ifrah Razzaq, General Dentist, Salman Dental Center, Hidd, Bahrain, Tel: 00973-34687228; E-mail: [dr.ifrah.razzaq@gmail.com](mailto:dr.ifrah.razzaq@gmail.com)

**Keywords:** Obstructive sleep apnea; Polysomnography; Cone-beam computed tomography; Continuous Positive Airway Pressure (CPAP); Mini-screw assisted rapid palatal expansion

<https://www.peertechzpublications.com>



## Review Article

# Obstructive Sleep Apnea - A Review

Ifrah Razzaq\*

General Dentist, Salman Dental Center, Hidd, Bahrain

## Abstract

**Introduction:** Obstructive Sleep Apnea (OSA) is a common condition with a higher prevalence in middle-aged men. Even though it is a common condition, OSA is frequently undiagnosed.

**Methods:** This article discusses the prevalence of OSA, common signs and symptoms, complications, screening and diagnosis, and management of Obstructive Sleep Apnea from the current literature.

**Results:** Daytime sleepiness has been reported to be a common symptom in patients with OSA. This has been shown to pose a risk to the patient especially when driving as it may lead to higher rate of automobile accidents. Early screening, Prompt diagnosis and appropriate management can help the patients with OSA at an early stage and prevent the advancement of OSA into advanced stages.

**Conclusions:** Dentists and orthodontists can contribute to the health and well-being of patients with OSA by undertaking screening of such patients and referring to the physicians for an established diagnosis. Furthermore, with the guidance and recommendation of the patient's physician, dentists and orthodontists can play a role in the management of patients with OSA.

## Abbreviations

OSA: Obstructive Sleep Apnea; CPAP: Continuous Positive Airway Pressure; MARPE: Mini-Screw Assisted Rapid Palatal Expansion; RPE: Rapid Palatal Expansion

## Introduction

Obstructive Sleep Apnea (OSA) is a common condition affecting a high percentage of middle-aged males [1]. It is frequently manifested as loud snoring, nocturnal waking, feeling sleepy during the day. It has also been reported that vehicular accidents occur due to OSA. Thus, it is a threat not only to the patients but also to other people. Diagnosing the OSA conditions at an early stage can prevent the negative effects of OSA on other systems of the body [1,2].

## Prevalence

The prevalence of OSA has been reported to be 14% in men and 5% in women [3]. The five year incidence-rates of OSA in middle age patients has been reported to be from 7 percentage

to 11 percentage [4]. The prevalence of OSA in adolescents has been reported to range from 4% to 11%. Although OSA has a high prevalence, it is frequently underdiagnosed. This could be due to the lack of knowledge regarding the common signs and symptoms of OSA. An important reason for this is that the condition develops gradually over years, and so a person's sleepiness develops gradually, almost imperceptibly. Patients thus do not recognize how sleepy they have become. If they do recognize they are sleepy, they tend to make excuses for it to avoid being tested and treated for OSA.

## Materials and methods

The current available literature on obstructive sleep apnea was searched and the information was compiled to provide a comprehensive review of the topic.

## Signs and symptoms

The most common symptoms of OSA are snoring and waking up gasping for breath in the middle of night [1]. Many patients do not get a good night's sleep and thus, wake up tired



and drained. Many patients with OSA report feeling sleepy during the day. It has been reported that the loud snoring that accompanies OSA also bothers the partners for the patients. With respect to symptoms, it is important to recognize two types of symptoms, those reported by sleeping partners, and those reported by the patients themselves. Patient may not recognize the symptoms, so talking to a partner about snoring, stopping breathing during sleep and even sleepiness is important. Overall, OSA has been reported to reduce the quality of life of patients. OSA can be manifested in different types such as apnea meaning complete cessation of breathing, and hypopnea meaning with decrease in the oxygen saturation in the blood. The signs of OSA such as narrow pharynx is important to note during dental examination. If the pharynx appears narrow, then it may be beneficial to inquire about the symptoms of OSA.

### Complications

OSA, if not treated promptly, in adolescents can give rise to brain damage due to insufficiency of oxygen in the children during the growing period [6,7]. This leads to negative effects on their focus, concentration and potential complications later on in life. In adults, OSA has been shown to lead to decrease in cognitive functioning capacity and increased incidence of vehicular accidents. In addition, OSA has shown to increase the tendency for heart-attacks, cardiac arrest, and cerebrovascular strokes. In addition, OSA has been found to be linked with the degenerative diseases such as Alzheimer's disease as well as type 2 diabetes [7,8]. Other complication of OSA include hypertension and atrial fibrillation.

## Results and discussion

### Screening and diagnosis

The early diagnosis of OSA is important for prompt management and preventing the complications arising due to advanced respiratory obstruction. Thus, it is important that clinicians, whether physicians, pediatricians, pedodontists, orthodontists, and general dentists screen their patients for OSA. Several screening tools are available for diagnosing OSA. The American Academy of Sleep Medicine suggests that all adults should be screened for OSA [6]. One way this can be implemented is by inclusion of sleep as a part of the review system. The patients who are found to have positive history or symptoms could be screened further with clinical examination, radiographic, and laboratory tests. The main risk factors for OSA are obesity, body mass index (MNI)  $>35 \text{ kg/m}^2$ , positive family history, mandibular retrognathia, high blood pressure which is resistant to treatment, Congestive heart failure, Atrial fibrillation, Stroke, Type 2 diabetes, Polycystic ovary syndrome, Acromegaly and Down syndrome [9]. Screening tools such as the STOP-BANG questionnaire can be used by medical and dental specialists alike [10]. It includes

### STOP

S Do you snore loudly (louder than talking or loud enough to be heard through closed doors)?

T Do you often feel tired, fatigued, or sleepy during the day?

O Has anyone observed you stop breathing during sleep?

P Do you have or are you being treated for high blood pressure?

### BANG

B Body mass index  $>35 \text{ kg/m}^2$ ?

A Age  $>50$  years?

N Neck circumference  $>40 \text{ cm}$ ?

G Gender male?

\*In a perioperative setting, answering "yes" to  $\geq 3$  questions indicates high risk for obstructive sleep apnea. Answering "yes" to  $\geq 5$  questions indicates high risk for moderate to severe obstructive sleep apnea.

The diagnosis of OSA requires a comprehensive approach. Simple snoring can be distinguished from OSA by asking the patients more details regarding snoring and their sleep. Tishler, et al. reported that patients with OSA have a higher likelihood of loud snoring that can bother others [4]. Increased daytime sleepiness is another findings that can help in diagnosis of OSA. The modified Mallampati classification is used for clinical examination for patients with OSA. This classification is based on the risk associated with the patient for OSA. A higher grade for OSA classification would mean an increased risk for OSA. The classification is graded from grade 1 to grade 5 - Grade I-soft-palate, uvula, tonsillar-fauces, and pillars visible; Grade II- soft-palate, uvula, and tonsillar-fauces visible; Grade III-only soft palate and base of uvula visible; Grade IV-only hard palate visible. In addition, Epworth Sleepiness Scale is routinely used in clinical practice to assess sleepiness. The Epworth Sleepiness scale includes eight different conditions which is rated by the patient from 0 to 3. After the test is finished, the values are added up and the total of the score ranges from 0 to 24. The higher the score, the higher possibility of requirement for medical attention.

Clinical doctors, physicians, dentists, and dental specialists such as pedodontits, orthodontists can play an important role in identifying and screening the patients for OSA. Dentists often record radiographs such as lateral cephalograms which includes airway as a part of the diagnostic records [11]. These radiographs can be used as an additional aid in conjunction with clinical examination and screening questionnaires to identify any visible obstructions in the oro-naso-pharyngeal airway. However, in recent times it has been reported that the conventional two-dimensional (2D) radiographs such as lateral cephalograms do not adequately represent the 3-Dimensional (3D) structures of the head and neck and that there are errors in recording lateral cephalograms based on the patient's head positioning [12]. Recently, 3-D radiographs such as Cone-Beam Computed Tomography (CBCT) has been introduced in the dental world. CBCT is rapidly gaining popularity with dentists, and more specifically orthodontists [13]. CBCT has been shown to allow accurate measurements of dental, skeletal,

and soft-tissues of head and neck [13]. As CBCT does not lead to magnification of structures as found in the 2D radiographs, accurate measurements can be performed easily with the help of CBCT for maxilla, mandibular, airway, and temporomandibular joint. CBCT has also been used to identify the effects of different types of expansion on temporomandibular joint [14].

The diagnosis of OSA is done with Polysomnography (PSG) which is administered in a hospital in the presence of a technician. An alternative is Home Sleep Apnea Testing (HSAT) in which the testing for OSA is performed at home instead of the hospital [15,16]. HSAT is similar to PSG in that HSAT does not include EEG as a part of the testing. HSAT records the oximetry, airflow and chest movement. HSAT is a comparatively cheaper method for assessment of OSA compared to PSG [17]. HSAT also enables the diagnosis of OSA in underserved and remote areas. Home sleep studies vary greatly in what signals are recorded, and they may include all the signals that are used in sleep laboratory polysomnography.

### Management of OSA

Continuous Positive Airway Pressure (CPAP) is the popular treatment option for patients with OSA. However, it has been reported that the treatment with CPAP should be reserved for patients with moderate to severe OSA. Patients who have evident symptoms with OSA can be provided the CPAP treatment [18]. It is beneficial to provide explanation of the benefits of CPAP and the inconvenience caused by CPAP. An informed decision making process can be facilitated by a trial run of providing the CPAP equipment and allowing the patient and their partner to understand the treatment [19].

Surgical methods such as tonsillectomy or adenoidectomy have been suggested as a method to reduce the severity of OSA in adolescent patients [20]. In such patients, enlargement of lymphoid tissues acts as an obstruction which prevents the patients from breathing freely during sleep and leads to increased incidences of apnea [21]. In many patients, the enlarged tonsils shrink down in size once they pass the pubertal period without surgical intervention. Although effective, the disadvantages of this method includes surgical intervention, invasiveness, and potential complications involved with surgery. An alternative method of management of OSA includes orthodontic intervention to move the mandible forward with mandibular advancement devices [22]. The mandibular advancement device is made by recording the patient's bite in a forward position. Such devices usually consist of an acrylic block and as the patient bites into the device at night, it holds the lower jaw of the patient in a forward position [23]. This leads to reduction of airway collapsibility and enlarging the upper airway to facilitate better breathing.

Another method that has been proposed to increased oro-naso-pharyngeal airway dimensions is maxillary expansion, also known as Rapid Palatal Expansion (RPE). It has shown that RPE leads to decreased nasal resistance [24]. Chang, et al. has shown in a recent study that the oropharyngeal and nasopharyngeal airway dimensions have been found to increase immediately after RPE [25]. However, as RPE leads to dental

relapse in the long-term, some authors have shown concerns if the short-term effects of RPE on airway will also relapse in the long-term effects. Thus, to minimize the dental relapse associated with RPE and achieve more skeletal expansion, Mini-Implant Assisted Rapid Palatal Expansion (MARPE) has been introduced [26,27] Mini-implants have changed the way in which contemporary orthodontics is practiced. Mini-implants have been used successfully for the treatment of complicated malocclusions such as open-bite and now are being employed for management of transverse maxillary deficiency with MARPE [28]. Modifications of MARPE for unilateral correction of posterior crossbite have also been developed [29].

However, as MARPE is relatively a new technique compared to RPE, not much information is available in the literature regarding the long-term effects of MARPE as compared to RPE [26,27]. Recently Mehta, et al. showed that MARPE led to increase nasopharyngeal volume in the long-term compared to controls but there was no difference in the airway volume with RPE compared to controls [30]. This is an important finding as higher nasopharyngeal volume in the long-term with MARPE implies that the changes in airway are stable [30]. In the current literature, the longest follow up times available for the effects of MARPE are 2 years, 8 months [30]. Further studies on long-term follow-up would be useful in identifying the long-term effects of RPE and MARPE on airway. However, functional respiratory tests such as rhinometry, rhinomanometry, and nasal flow measurements should be performed to identify whether increased airway volume leads to improved respiratory function.

Another treatment option for patients with OSA is advancement of maxilla and mandible with orthognathic surgery [31]. This method is invasive and can lead to potential complications associated with surgery. However, it has been show to predictably improve the symptoms of OSA and decrease the OHI index in patients with OSA. Other less invasive surgical interventions such as nasal septoplasty or turbinate reduction, have also been suggested for patients with OSA [32]. These procedures also help in increasing the tolerability of the patients to CPAP. Although CPAP is an effective treatment modality, the patient adherence with CPAP is not very high. Thus, different methods to improve the patient compliance with CPAP have been sought after for better treatment outcomes. Another option that can cure OSA is tracheostomy and it is used only in life-threatening situations [31]. In addition, weight loss can benefit the patients with OSA who are obese.

This article highlights the different screening, diagnostic, and management protocols for OSA. Even though OSA is managed primarily by a physician, dentists and orthodontists can play a role in the identification and treatment of such patients. Recent advances in the field of orthodontics have broadened the scope of orthodontists to involve management of patients with OSA. With advances in orthodontics diagnosis, the diagnosis of OSA will be easier in the future [33,34]. In addition, the application of Artificial intelligence for radiographic analysis has provided a new direction to the diagnosis and treatment planning process [35].



## Conclusion

OSA is a common condition with higher prevalence in middle-aged men. It is frequently underdiagnosed. OSA leads to symptoms such as snoring and waking up gasping for air in the middle of the night due to the reduced oxygen saturation in the blood. Excessive sleepiness during the day is a common finding in patients with OSA. In the presence of symptoms, patients with OSA should be treated promptly to prevent any untoward risks such as automobile accidents. Early screening and diagnosis can be helpful in the management of patients with OSA. Orthodontists and dentists can play an important role in the screening of the patients with OSA. In addition, they can work as a valuable team-member with the physician and work under the guidance of the physician for a comprehensive management of patients with OSA.

## References

- Kapur V, Strohl KP, Redline S, Iber C, O'Connor G, et al. (2002) Underdiagnosis of sleep apnea syndrome in U.S. communities. *Sleep Breath* 6: 49-54. [Link: https://bit.ly/3n37CnH](https://bit.ly/3n37CnH)
- Terán-Santos J, Jiménez-Gómez A, Cordero-Guevara J (1999) The association between sleep apnea and the risk of traffic accidents. Cooperative Group Burgos-Santander. *N Engl J Med* 340: 847-851. [Link: https://bit.ly/3h922w2](https://bit.ly/3h922w2)
- Peppard PE, Young T, Barnett JH, Palta M, Hagen EW, et al. (2013) Increased prevalence of sleep disordered breathing in adults. *Am J Epidemiol* 177: 1006-1014. [Link: https://bit.ly/3DMKorX](https://bit.ly/3DMKorX)
- Tishler PV, Larkin EK, Schluchter MD, Redline S (2003) Incidence of sleep-disordered breathing in an urban adult population: the relative importance of risk factors in the development of sleep-disordered breathing. *JAMA* 289: 2230-2237. [Link: https://bit.ly/2YxavTu](https://bit.ly/2YxavTu)
- Somers VK, Dyken ME, Clary MP, Abboud FM (1995) Sympathetic neural mechanisms in obstructive sleep apnea. *J Clin Invest* 96: 1897-1904. [Link: https://bit.ly/3tkneV2](https://bit.ly/3tkneV2)
- Epstein LJ, Kristo D, Strollo PJ, Friedman N, Malhotra A, et al. (2009) Adult Obstructive Sleep Apnea Task Force of the American Academy of Sleep Medicine. Clinical guideline for the evaluation, management and long-term care of obstructive sleep apnea in adults. *J Clin Sleep Med* 5: 263-276. [Link: https://bit.ly/38lbDVY](https://bit.ly/38lbDVY)
- Björnsdóttir E, Janson C, Sigurdsson JF, Gehrman P, Perlis M, et al. (2013) Symptoms of insomnia among patients with obstructive sleep apnea before and after two years of positive airway pressure treatment. *Sleep* 36: 1901-1919. [Link: https://bit.ly/38Yn7VP](https://bit.ly/38Yn7VP)
- Strohl KP, Brown DB, Collop N, George C, Grunstein R, et al. (2013) ATS Ad Hoc Committee on Sleep Apnea, Sleepiness, and Driving Risk in Noncommercial Drivers. An official American Thoracic Society Clinical Practice Guideline: sleep apnea, sleepiness, and driving risk in noncommercial drivers. An update of a 1994 statement. *Am J Respir Crit Care Med* 187: 1259-1266. [Link: https://bit.ly/3jPnhVH](https://bit.ly/3jPnhVH)
- Chung F, Subramanyam R, Liao P, Sasaki E, Shapiro C, et al. (2012) High STOP-Bang score indicates a high probability of obstructive sleep apnoea. *Br J Anaesth* 108: 768-775. [Link: https://bit.ly/2YvfbQa](https://bit.ly/2YvfbQa)
- Pae EK, McKenna GA, Sheehan TJ, Garcia R, Kuhlberg A, et al. (2001) Role of lateral cephalograms in assessing severity and difficulty of orthodontic cases. *Am J Orthod Dentofacial Orthop* 120: 254-262. [Link: https://bit.ly/3jOPhsc](https://bit.ly/3jOPhsc)
- Burstone CJ, James RB, Legan H, Murphy GA, Norton LA (1978) Cephalometrics for orthognathic surgery. *J Oral Surg* 36: 269-277. [Link: https://bit.ly/3h48MLC](https://bit.ly/3h48MLC)
- Mehta S, Dresner R, Gandhi V, Chen PJ, Allareddy V, et al. (2020) Effect of positional errors on the accuracy of cervical vertebrae maturation assessment using CBCT and lateral cephalograms. *J World Fed Orthod* 9: 146-154. [Link: https://bit.ly/3yR80HY](https://bit.ly/3yR80HY)
- Marmulla R, Wörtche R, Mühling J, Hassfeld S (2005) Geometric accuracy of the NewTom 9000 Cone Beam CT. *Dentomaxillofac Radiol* 34: 28-31. [Link: https://bit.ly/3tmcJAY](https://bit.ly/3tmcJAY)
- Mehta S, Chen PJ, Vich ML, Upadhyay M, Tadinada A, et al. (2021) Bone-anchored versus tooth-anchored expansion appliances: Long-term effects on the condyle-fossa relationship. *J World Fed Orthod*. [Link: https://bit.ly/38LzDYk](https://bit.ly/38LzDYk)
- Rosen CL, Auckley D, Benca R, Foldvary-Schaefer N, Iber C, et al. (2012) A multisite randomized trial of portable sleep studies and positive airway pressure autotitration versus laboratory-based polysomnography for the diagnosis and treatment of obstructive sleep apnea: the HomePAP study. *Sleep* 35: 757-767. [Link: https://bit.ly/3j09VZE](https://bit.ly/3j09VZE)
- Kuna ST, Gurubhagavatula I, Maislin G, Hin S, Hartwig KC, et al. (2011) Noninferiority of functional outcome in ambulatory management of obstructive sleep apnea. *Am J Respir Crit Care Med* 183: 1238-1244. [Link: https://bit.ly/2WPZ9ZU](https://bit.ly/2WPZ9ZU)
- Chai-Coetzer CL, Antic NA, Hamilton GS, McArdle N, Wong K, et al. (2017) Physician decision making and clinical outcomes with laboratory polysomnography or limited-channel sleep studies for obstructive sleep apnea: a randomized trial. *Ann Intern Med* 166: 332-340. [Link: https://bit.ly/3leJQmf](https://bit.ly/3leJQmf)
- Barbé F, Durán-Cantolla J, Sánchez-de-la-Torre M, Martínez-Alonso M, Carmona C, et al. (2012) Spanish Sleep And Breathing Network. Effect of continuous positive airway pressure on the incidence of hypertension and cardiovascular events in nonsleepy patients with obstructive sleep apnea: a randomized controlled trial. *JAMA* 307: 2161-2168. [Link: https://bit.ly/3n1kZom](https://bit.ly/3n1kZom)
- McArdle N, Kingshott R, Engleman HM, Mackay TW, Douglas NJ (2001) Partners of patients with sleep apnoea/hypopnoea syndrome: effect of CPAP treatment on sleep quality and quality of life. *Thorax* 56: 513-518. [Link: https://bit.ly/38LH3Ls](https://bit.ly/38LH3Ls)
- Warrier R, Chauhan A, Athale U (2010) Tonsillectomy and adenoidectomy for obstructive sleep apnea in sickle cell anemia. *Indian J Pediatr* 77: 669-672. [Link: https://bit.ly/3zNs3IL](https://bit.ly/3zNs3IL)
- Reckley LK, Fernandez-Salvador C, Camacho M (2018) The effect of tonsillectomy on obstructive sleep apnea: an overview of systematic reviews. *Nat Sci Sleep* 10: 105-110. [Link: https://bit.ly/3jIA9g5](https://bit.ly/3jIA9g5)
- Ramar K, Dort LC, Katz SG, Lettieri CJ, Harrod CG, et al. (2015) Clinical practice guideline for the treatment of obstructive sleep apnea and snoring with oral appliance therapy: an update for 2015. *J Clin Sleep Med* 11: 773-827. [Link: https://bit.ly/3BFvVrA](https://bit.ly/3BFvVrA)
- Phillips CL, Grunstein RR, Darendeliler MA, Mihailidou AS, Srinivasan VK, et al. (2013) Health outcomes of continuous positive airway pressure versus oral appliance treatment for obstructive sleep apnea: a randomized controlled trial. *Am J Respir Crit Care Med* 187: 879-887. [Link: https://bit.ly/3jLcVWE](https://bit.ly/3jLcVWE)
- Vale F, Albergaria M, Carrilho E, Francisco I, Guimarães A, et al. (2017) Efficacy of rapid maxillary expansion in the treatment of obstructive sleep apnea syndrome: a systematic review with meta-analysis. *J Evid Based Dent Pract* 17: 159-168. [Link: https://bit.ly/38FW6pU](https://bit.ly/38FW6pU)
- Chang Y, Koenig LJ, Pruszyński JE, Bradley TG, Bosio JA, et al. (2013) Dimensional changes of upper airway after rapid maxillary expansion: a prospective cone-beam computed tomography study. *Am J Orthod Dentofacial Orthop* 143: 462-470. [Link: https://bit.ly/3jNUuAJ](https://bit.ly/3jNUuAJ)
- Abu Arqub S, Mehta S, Iverson MG, Yadav S, Upadhyay M, et al. (2021) Does Mini Screw Assisted Rapid Palatal Expansion (MARPE) have an influence on



airway and breathing in middle-aged children and adolescents? A systematic review. *Int Orthod* 19: 37-50. [Link: https://bit.ly/3h2CSze](https://bit.ly/3h2CSze)

27. Kim SY, Park YC, Lee KJ, intermann A, Han SS, et al. (2018) Assessment of changes in the nasal airway after nonsurgical miniscrew-assisted rapid maxillary expansion in young adults. *Angle Orthod* 88: 435-441. [Link: https://bit.ly/38Lzm7K](https://bit.ly/38Lzm7K)
28. Deguchi T, Kurosaka H, Oikawa H, Kuroda S, Takahashi I, et al. (2011) Comparison of orthodontic treatment outcomes in adults with skeletal open bite between conventional edgewise treatment and implant-anchored orthodontics. *Am J Orthod Dentofacial Orthop* 139: S60-S68. [Link: https://bit.ly/3n4hOwb](https://bit.ly/3n4hOwb)
29. Dzingle J, Mehta S, Chen PJ, Yadav S (2020) Correction of Unilateral Posterior Crossbite with U-MARPE. *Turk J Orthod* 33: 192-196. [Link: https://bit.ly/2YxlhZV](https://bit.ly/2YxlhZV)
30. Mehta S, Wang D, Kuo CL, Mu J, Vich ML, et al. (2020) Long-term effects of mini-screw-assisted rapid palatal expansion on airway. *Angle Orthod* 91: 195-205. [Link: https://bit.ly/3n375Cd](https://bit.ly/3n375Cd)

31. Strollo PJ, Soose RJ, Maurer JT, de Vries N, Cornelius J, et al. (2014) STAR Trial Group. Upper-airway stimulation for obstructive sleep apnea. *N Engl J Med* 370: 139-149. [Link: https://bit.ly/3tgEMbn](https://bit.ly/3tgEMbn)
32. Rosvall BR, Chin CJ (2017) Is uvulopalatopharyngoplasty effective in obstructive sleep apnea? *Laryngoscope* 127: 2201-2202. [Link: https://bit.ly/3BKxF71](https://bit.ly/3BKxF71)
33. Kau CH, Richmond S, Palomo JM, Hans MG (2005) Three-dimensional cone beam computerized tomography in orthodontics. *J Orthod* 32: 282-293. [Link: https://bit.ly/3yOA9zi](https://bit.ly/3yOA9zi)
34. Gange P (2015) The evolution of bonding in orthodontics. *Am J Orthod Dentofacial Orthop* 147: S56-S63. [Link: https://bit.ly/3n886Zt](https://bit.ly/3n886Zt)
35. Mehta S, Suhail Y, Nelson J, Upadhyay M (2021) Artificial Intelligence for radiographic image analysis. *Semin Orthod* 27: 109-120. [Link: https://bit.ly/2WZ5FxF](https://bit.ly/2WZ5FxF)

### Discover a bigger Impact and Visibility of your article publication with Peertechz Publications

#### Highlights

- ❖ Signatory publisher of ORCID
- ❖ Signatory Publisher of DORA (San Francisco Declaration on Research Assessment)
- ❖ Articles archived in worlds' renowned service providers such as Portico, CNKI, AGRIS, TDNet, Base (Bielefeld University Library), CrossRef, Scilit, J-Gate etc.
- ❖ Journals indexed in ICMJE, SHERPA/ROMEO, Google Scholar etc.
- ❖ OAI-PMH (Open Archives Initiative Protocol for Metadata Harvesting)
- ❖ Dedicated Editorial Board for every journal
- ❖ Accurate and rapid peer-review process
- ❖ Increased citations of published articles through promotions
- ❖ Reduced timeline for article publication

**Submit your articles and experience a new surge in publication services** (<https://www.peertechz.com/submission>).

*Peertechz journals wishes everlasting success in your every endeavours.*

**Copyright:** © 2021 Razzaq I. This is an open-access article distributed under the terms of the Creative Commons Attribution License, which permits unrestricted use, distribution, and reproduction in any medium, provided the original author and source are credited.