Peertechz



Open Journal of Orthopedics and Rheumatology

OPEN ACCESS JOURNAL

ISSN: 2641-3116 Journal DOI: https://dx.doi.org/10.17352/ojor

Research Article

Pitfalls and Pearls in Transpsoas Lateral Lumbar Interbody Fusion

Alberto Luis Martinez Mateo[1], Madeline Rodriguez[2] and Andreina Rosario Rosario[3]*

[1]Hospital Traumatológico Universitario Dr. Darío Contreras, Santo Domingo, Dominican Republic

[2]Hospital Traumatológico Universitario Docente Dr. Ney Arias Lora, Santo Domingo, Dominican Republic

[3]Medicine, Universidad Autónoma de Santo Domingo (UASD), Santo Domingo, Dominican Republic

Submitted : 31 October, 2026
Accepted : 24 November, 2026
Published : 25 November, 2026

***Corresponding author:** Andreina Rosario Rosario, Medicine, Universidad Autónoma de Santo Domingo (UASD), Santo Domingo, Dominican Republic, E-mail: Andreinarosario07@gmail.com

Keywords: Lateral lumbar interbody fusion; Transpsoas; XLIF; Lumbar plexus; Indirect decompression; Cage subsidence; Surgical complications

Copyright License: © 2026 Martinez Mateo AL, et al. This is an open-access article distributed under the terms of the Creative Commons Attribution License, which permits unrestricted use, distribution, and reproduction in any medium, provided the original author and source are credited.

https://www.organscigroup.us

Check for updates

Abstract

Background: Transpsoas lateral lumbar interbody fusion can restore anterior-column support and achieve indirect decompression, but its safety depends on patient selection, level-specific anatomy, neural surveillance, and preservation of endplate support.

Objective: To organize practical pitfalls, preventive measures, and reasons to modify a transpsoas strategy within an evidence-informed technical workflow.

Methods: This narrative review retains the original 38 publications and incorporates six additional primary reports published in 2022–2026 after a targeted update completed on November 19, 2026. Anatomy, decompression, monitoring, reconstruction, positioning, and complications were synthesized without pooling participants or effect estimates.

Results: The 44 publications support a decision-based technical synthesis. The evidence supports individualized corridor assessment, selection for reversible compression, preservation of endplates, and planned construct stability. Contemporary monitoring and retraction-time studies do not establish a universal threshold of neural safety. Selected prone-position cohorts demonstrate feasibility but cannot establish equivalence for uncommon serious complications. Mixed XLIF/OLIF studies and a prepsoas randomized trial inform decompression mechanisms rather than transpsoas access safety.

Conclusion: Access, decompression, and reconstruction require separate but compatible decisions. The workflow is an educational synthesis rather than a validated algorithm. Selection, outcome ascertainment, residual confounding, and overlapping cohorts limit the strength and transferability of the recommendations.

Introduction

Transpsoas lateral lumbar interbody fusion has become an established option for selected adults with degenerative lumbar disease and spinal deformity. The original description of extreme lateral interbody fusion demonstrated a retroperitoneal route to the lumbar disc through the psoas, permitting disc preparation and insertion of a broad interbody implant without routine entry into the posterior spinal canal [1]. Variations in positioning, fixation, imaging, and implants broaden the circumstances in which lateral reconstruction is considered, but they also make the term LLIF an imprecise description of what was actually performed.

In this article, LLIF denotes a true transpsoas approach unless a different corridor is explicitly identified. Direct lateral interbody fusion and extreme lateral interbody fusion belong to this technical family. Oblique or anterior to psoas fusion uses a different relationship to the psoas, plexus, and great vessels. A study labelled lateral fusion therefore cannot automatically establish the neurological safety, access feasibility, or clinical performance of a transpsoas procedure.

Citation: Martinez Mateo AL, Rodriguez M, Rosario AR. Pitfalls and Pearls in Transpsoas Lateral Lumbar Interbody Fusion. Open J Orthop Rheumatol. 2026;11(1):15-28. Available from: https://dx.doi.org/10.17352/ojor.000058

Maintaining this distinction is particularly important when translating selection criteria or small comparative trials into operative recommendations.

The appeal of LLIF is anatomical and mechanical. A lateral cage can restore disc and foraminal dimensions, support the anterior column, and contribute to segmental correction. Indirect neural decompression may reduce the need for posterior tissue removal when compression has a reversible component [2]. However, restoration of radiographic dimensions does not establish symptom relief in an individual patient. A fixed osseous lateral recess lesion may persist despite satisfactory distraction, while an initially successful decompression may be lost if the implant subsides [3,4].

Access introduces a second set of constraints. The lumbar plexus lies within the psoas and its relationship to the disc changes by level and between patients. Cadaveric and imaging studies support heightened attention at L4-L5, where plexus position, vessel location, and the iliac crest may restrict the working trajectory [5–10]. None of these studies establishes a universally safe quadrant. A technically convenient skin incision or reassuring stimulation response cannot compensate for an unsuitable corridor.

Research published since 2022 has refined these constraints. An MRI-based L4–L5 classification emphasizes anatomical selection [11], while contemporary subsidence work distinguishes intraoperative endplate violation from later settling [12]. Protocol-based monitoring and retraction-time analyses question the use of a reassuring signal or a 20-minute rule as an independent certificate of neural safety [13,14]. Multicenter prone-position data and a two-decade motor-deficit cohort extend outcome reporting while retaining selection and era-related limitations [15,16]. These developments complement the foundational anatomy and mechanics rather than remove their relevance.

The practical challenge is consequently broader than preventing one named complication. Transient thigh symptoms, a major motor deficit, endplate injury, persistent stenosis, loss of alignment, and visceral injury arise through different mechanisms and demand different preventive measures. This technical note links those mechanisms to decisions made before access, during reconstruction, and after surgery. Its purpose is to present usable pearls together with their boundaries, so that recognition of an unfavorable condition leads to reassessment rather than escalation of force or reliance on a single reassuring measurement.

Materials and methods

Design and scope

This work is a narrative review with an evidence informed technical description. It does not report a patient series, a newly tested operation, or a systematic review and meta analysis. The scope is adult transpsoas LLIF for degenerative disease and selected deformity reconstruction. Tumor, infection, trauma, pediatric indications, and intentional anterior longitudinal ligament release are outside the principal workflow. Prepsoas literature is retained only when it helps explain a transferable mechanical principle or a limitation of available evidence.

Literature retrieval and source verification

Targeted online searches were performed on October 28, 2026, to retrieve PubMed indexed records, Europe PMC records, and original journal pages. Search concepts combined lateral lumbar interbody fusion, XLIF, direct lateral, or transpsoas with anatomy, lumbar plexus, neuromonitoring, indirect decompression, lateral recess, endplate, subsidence, cage, fixation, alignment, complications, and prone positioning. Examples included “lateral lumbar interbody fusion” AND “bony lateral recess” and “lateral lumbar interbody fusion” AND “endplate” AND “subsidence”. Reference lists and related records were used to locate foundational studies. No claim of exhaustive database coverage is made.

The original 38 publications were selected purposively for their relevance to a technical decision, anatomical mechanism, complication, or evidentiary boundary. A targeted update for this revision was completed on November 19, 2026, using PubMed-indexed bibliographic records and original journal pages, with the same technical concepts and additional terms including monitoring protocol, retraction time, L4–L5 anatomy, prone complications, and contemporary motor deficits. Six relevant primary reports published in 2022–2026 were added [11–16], producing a 44-publication corpus. The earlier 38 references were retained. This was a focused narrative update rather than an exhaustive search with a documented screening denominator. No retrospective PRISMA flow or systematic-review claim was constructed.

Synthesis and illustration development

Evidence was organized by selection, access, monitoring, disc preparation, reconstruction, and postoperative assessment. Each publication was recorded separately by design, operative corridor, supported interpretation, and principal limitation in Table 2; Table 1 provides a selective clinical translation rather than a second inventory. Cadaveric, biomechanical, observational, and randomized evidence was interpreted according to design. No pooled estimate, formal certainty grade, formal risk-of-bias score, independent duplicate screening, or validated risk score was generated. Reports from the same parent cohort were not treated as independent patient populations, and participant totals were not summed across publications or reviews.

Figure 4 was prepared de novo for this revision with two-dimensional vector primitives and anatomical labels in Python using Matplotlib, then exported as a 600-dpi raster image for Word. It identifies fluoroscopic reference landmarks without assigning a safe docking coordinate or using patient images. No third-party image was reproduced or traced in this new figure. The provenance, creator, preparation software, and license or permission status of Figures 1–3 and 5–8 and Infographics 1–2 require separate confirmation in the illustration provenance register; their originality and permission status are not certified by their captions alone.

Citation: Martinez Mateo AL, Rodriguez M, Rosario AR. Pitfalls and Pearls in Transpsoas Lateral Lumbar Interbody Fusion. Open J Orthop Rheumatol. 2026;11(1):15-28. Available from: https://dx.doi.org/10.17352/ojor.000058

Table 1: Practical pitfalls and pearls by operative decision

Decision	Pitfall	Pearl and supporting evidence	Reason to change plan
Decompression	Assume increased disc height resolves every stenosis	Identify reversible collapse and fixed compression separately [2,3,17,19]	Fixed lesion or progressive deficit requiring direct treatment
Corridor	Apply a universal docking quadrant	Review plexus, vessels, rotation, crest and level together [5–11]	No acceptable trajectory with adequate visualization
Imaging	Use one projection for every level.	Confirm numbering, bilateral pedicles, spinous process, endplates and orthogonal level-specific views (Figure 4) [1,34,35]	Uncertain orientation or disagreement with anatomy
Monitoring	Treat a reassuring threshold as proof of safety.	Integrate anatomy, signal trends and exposure conditions; no universal 20-minute certificate [13,14,31–33]	Unexplained alert or persistent anatomical concern
Endplate	Remove structural bone during cartilage preparation	Preserve the supporting osseous surface and distinguish intraoperative breach from later settling [12,20,21,25]	Breach, unexpected settling or lost trial resistance
Cage	Pursue height despite excessive resistance	Match footprint, reducibility and bone support [12,22–24]	Unsafe insertion force or unsuitable support
Construct	Let access convenience determine fixation	Plan stability and alignment with decompression [26–28]	Instability or unacceptable loss of restored dimensions
Surveillance	Label every new thigh symptom as neuropraxia	Document distribution, strength, timing and systemic signs; separate motor from sensory outcomes [15,16,37–44]	Progressive weakness, abdominal illness, or circulatory change

Table 1 is a selective educational decision matrix, not an exhaustive publication inventory or a validated score. Citations identify evidence relevant to each operative action. Publications not cited in a particular row are not excluded from the review: the complete 44-publication inventory appears in Table 2. Reasons to change plan include reassessment, additional treatment, alternative access, or stopping the lateral stage.

Table 2: Complete publication-level evidence inventory

The original 38 publications and the six additions are all listed below. "Update" identifies a newly incorporated 2022–2026 report. Rows are ordered by citation number.

Publication	Design and operative corridor	Principal finding and technical role	Main limitation or boundary
Ozgur 2006 [1]	Technical description. Transpsoas XLIF.	Establishes the original lateral retroperitoneal transpsoas route.	Foundational technical description; does not validate every modern implant, position, or indication.
Oliveira 2010 [2]	Consecutive clinical radiographic series. Stand-alone transpsoas XLIF.	Demonstrates radiographic enlargement after interbody distraction.	Radiographic change is not proof of adequate decompression or symptomatic benefit in each stenosis phenotype.
Wang 2017 [3]	Multicenter retrospective analysis of prospectively collected data. Transpsoas XLIF.	Associates fixed bony lateral recess stenosis with indirect decompression failure.	Study-specific failure definition; multilevel observations are not independent patients.
Tempel 2018 [4]	Retrospective review of prospectively collected consecutive cases. Stand-alone LLIF.	Associates graft subsidence with revision surgery.	Selected stand-alone population; association does not establish that every radiographic subsidence event requires revision.
Benglis 2009 [5]	Cadaveric anatomical study. Transpsoas corridor anatomy.	Maps lumbosacral plexus relationships relevant to access.	Small anatomical sample; static cadaveric relationships cannot guarantee a live patient-specific safe route.
Uribe 2010 [6]	Cadaveric anatomical study. Transpsoas corridor anatomy.	Describes level-related working-zone relationships.	Proposed zones are anatomical observations, not universally safe coordinates.
Regev 2009 [7]	Morphometric imaging study. Lateral corridor in normal and deformed spines.	Describes nerve-root and vessel relationships and the influence of deformity.	Imaging morphology and population averages cannot replace operative-position assessment.
Davis 2011 [8]	Anatomical study. Plexus within psoas at L4–L5.	Shows how intrapsoas plexus anatomy constrains lower lumbar access.	Sample-specific anatomy; no universal safe quadrant or stimulation threshold.
Publication	Design and operative corridor	Principal finding and technical role	Main limitation or boundary
Kepler 2011 [9]	MRI anatomical study. Psoas and plexus in transpsoas access.	Relates psoas morphology and plexus position to the proposed approach.	MRI position and static anatomy may differ from the operative configuration.
Banagan 2011 [10]	Cadaveric anatomical mapping. Direct lateral transpsoas corridor.	Maps nerve roots within proposed working regions.	Anatomical feasibility cannot establish functional neurological safety.
Amaral 2024 [11] — Update	MRI anatomical classification; 50 sites. L4–L5 transpsoas planning.	Proposes imaging-based stratification of L4–L5 access anatomy.	Selected high-quality images; unfavorable types not all operated; no prospective validation of clinical risk.
Ohiorhenuan 2022 [12] — Update	Retrospective analysis of a prospective database; 131 patients, 204 levels. Lateral lumbar interbody fusion.	Separates intraoperative endplate violation from later settling; evaluates relative cage support area.	Implant material and footprint are interrelated; adjusted associations are not a universal implant rule.
Mundis 2024 [13] — Update	Retrospective single-center cohort; 169 patients. LLIF with a neuromonitoring protocol.	Describes alerts and postoperative deficits; their correspondence is incomplete.	Response to alerts changes outcomes; no randomized protocol comparator establishes a preventive effect.
Patel 2025 [14] — Update	Retrospective multicenter cohort; 658 patients. Transpsoas LLIF.	The 20-minute threshold poorly predicts postoperative quadriceps palsy.	Few events and incomplete anatomical/procedural adjustment; findings do not prove prolonged retraction is harmless.
Soliman 2023 [15] — Update	Retrospective multicenter cohort; 365 patients, 11 centers. Prone transpsoas LLIF.	Extends reporting of approach-related sensory, motor, vascular, and visceral complications.	No lateral-position comparator; center-specific selection and surveillance; rare-event imprecision.
Burkhard 2026 [16] — Update	Retrospective two-era cohort; 1000 selected cases, 2006–2024. Lateral-decubitus LLIF without concomitant posterior procedures.	Reports motor-deficit trajectories and lower observed rates in the later era.	Era, selection, and ascertainment confounding; sensory outcomes excluded; possible overlap with older institutional cohorts.

Citation: Martinez Mateo AL, Rodriguez M, Rosario AR. Pitfalls and Pearls in Transpsoas Lateral Lumbar Interbody Fusion. Open J Orthop Rheumatol. 2026;11(1):15-28. Available from: https://dx.doi.org/10.17352/ojor.000058

Table 2: Complete publication-level evidence inventory
The original 38 publications and the six additions are all listed below. "Update" identifies a newly incorporated 2022–2026 report. Rows are ordered by citation number.

Publication	Design and operative corridor	Principal finding and technical role	Main limitation or boundary
Publication	Design and operative corridor	Principal finding and technical role	Main limitation or boundary
Yingsakmongkol 2022 [17]	Retrospective selection and risk-factor cohort. Mixed transpsoas XLIF and prepsoas OLIF.	Evaluates selection criteria using dynamic symptoms, reducibility, and absence of unfavorable static compression.	Selected mixed-corridor population; combined outcomes cannot be called transpsoas-specific.
Kirnaz 2020 [18]	Systematic review. Published LLIF evidence.	Synthesizes reported indirect decompression failures and predictive factors.	Heterogeneous failure definitions, reporting, and study selection prevent universal failure probabilities.
Limthongkul 2024 [19]	Randomized trial in selected patients. Prepsoas OLIF; indirect versus additional direct decompression.	Tests the need for added direct decompression in a selected reducible-stenosis population.	Adjacent mechanism evidence; does not establish transpsoas access safety or justify leaving fixed compression untreated.
Tempel 2015 [20]	Observational bone-density and subsidence study. Minimally invasive transforaminal lumbar interbody fusion (TLIF).	Associates impaired bone mineral density with graft subsidence.	Association and selected population do not define a universally protective density cutoff.
Jones 2021 [21]	Retrospective risk-factor analysis. LLIF with or without posterior screws.	Relates endplate volumetric bone mineral density to subsidence.	QCT-derived measurements and thresholds are protocol- and cohort-dependent.
Marchi 2013 [22]	Clinical radiographic subsidence study. Stand-alone lateral interbody fusion.	Evaluates cage subsidence together with clinical and radiographic outcomes.	Stand-alone construct selection and subsidence definitions restrict transferability.
Le 2012 [23]	Observational cage-subsidence study. Lateral retroperitoneal transpsoas LLIF.	Evaluates subsidence of PEEK cages and implant-related factors.	Implant characteristics and confounding factors affect applicability to modern cage materials and designs.
Pimenta 2012 [24]	Laboratory biomechanical study. Lateral interbody spacers.	Tests the effect of wider spacers on initial mechanical stability.	Laboratory stiffness cannot establish clinical fusion, symptom relief, or a safe size for every endplate.
Publication	Design and operative corridor	Principal finding and technical role	Main limitation or boundary
Wu 2022 [25]	Systematic review. LLIF studies of endplate injury and subsidence.	Synthesizes associations involving bone quality, multilevel surgery, and cage dimensions.	Heterogeneous definitions, implants, and observational designs limit pooled or threshold-based recommendations.
Kepler 2012 [26]	Observational radiographic factor analysis. Lateral transpsoas LLIF.	Evaluates factors influencing achieved segmental lumbar lordosis.	Radiographic associations do not establish clinical benefit or a universal correction target.
Issa 2023 [27]	Retrospective radiographic predictor analysis. Minimally invasive LLIF.	Relates cage positioning and patient/surgical factors to lordosis and disc-space restoration.	Confounding by implant selection, segment flexibility, and additional treatment limits causal inference.
Cappuccino 2010 [28]	Laboratory biomechanical analysis and review. Lateral lumbar fusion constructs.	Evaluates construct stability with different fixation configurations.	Initial in-vitro stability is not clinical fusion, long-term durability, or a universal fixation indication.
Sembrano 2016 [29]	Prospective multicenter comparison with randomized and observational arms. MIS transpsoas XLIF versus MIS TLIF.	Reports two-year clinical findings in selected low-grade degenerative spondylolisthesis.	Same parent cohort as the Isaacs companion report; publications must not be counted as independent patient samples.
Isaacs 2016 [30]	Companion radiographic report of the Sembrano parent cohort. MIS transpsoas XLIF versus MIS TLIF.	Reports two-year radiographic findings complementing the clinical report.	Not a second independent trial; radiographic and clinical outcomes answer different questions.
Tohmeh 2011 [31]	Prospective multicenter nonrandomized monitoring study. Transpsoas XLIF.	Evaluates dynamically evoked discrete-threshold EMG during transpsoas exposure.	Signal interpretation depends on conditions; monitoring does not exclude all injury mechanisms.
Uribe 2015 [32]	Prospective multicenter monitoring study. Transpsoas XLIF.	Evaluates monitoring during retraction and its relation to symptomatic neuropraxia.	Predictive associations do not establish a universally safe threshold or retractor duration.
Publication	Design and operative corridor	Principal finding and technical role	Main limitation or boundary
Riley 2018 [33]	Retrospective comparative monitoring study. Lateral lumbar interbody fusion.	Relates motor-evoked-potential use to postoperative deficit frequency.	Nonrandomized modality allocation and other practice differences can confound the association.
Ehresman 2025 [34]	Single-institution clinical case series. Prone transpsoas LLIF.	Reports feasibility and clinical and radiographic outcomes in selected prone cases.	No randomized comparator; selection and experience limit generalizability and rare-harm inference.
Sadhwani 2024 [35]	Single-surgeon nonrandomized comparative study. Single-position lateral versus prone transpsoas LLIF.	Compares early outcomes, including procedures involving L4–L5.	Early surveillance and single-surgeon selection cannot establish long-term or rare-complication equivalence.
Edelbach 2026 [36]	Retrospective propensity-matched non-inferiority analysis. Single-position prone versus dual-position transpsoas LLIF.	Tests selected radiographic endpoints under a prespecified non-inferiority framework.	Matching addresses measured covariates only; endpoint-specific non-inferiority is not global safety equivalence.
Rodgers 2011 [37]	Prospective complication series. Transpsoas XLIF.	Describes intraoperative and early postoperative complications across a large series.	Early follow-up and outcome definitions limit inference about delayed or rare harms.
Rustagi 2019 [38]	Retrospective bowel-injury case series. Minimally invasive lateral lumbar approach.	Documents bowel injury and its recognition after lateral access.	Rare-event selected cases illustrate mechanisms, not a generalizable procedure-specific incidence.

Citation: Martinez Mateo AL, Rodriguez M, Rosario AR. Pitfalls and Pearls in Transpsoas Lateral Lumbar Interbody Fusion. Open J Orthop Rheumatol. 2026;11(1):15-28. Available from: https://dx.doi.org/10.17352/ojor.000058

Table 2: Complete publication-level evidence inventory
The original 38 publications and the six additions are all listed below. "Update" identifies a newly incorporated 2022–2026 report. Rows are ordered by citation number.

Publication	Design and operative corridor	Principal finding and technical role	Main limitation or boundary
Kueper 2015 [39]	Observational vascular-complication series. Mini-open lateral LLIF access.	Characterizes vascular complications during mini-open lateral access.	Access-specific series and low event counts cannot guarantee absence of vascular risk.
Dakwar 2011 [40]	Clinical complication series. Minimally invasive lateral transpsoas LLIF.	Describes abdominal wall paresis after lateral access.	Denervation-related bulging must be distinguished from fascial hernia; a selected series is not a comparative risk estimate.
Publication	Design and operative corridor	Principal finding and technical role	Main limitation or boundary
Pumberger 2012 [41]	Clinical neurological-deficit cohort. Lateral lumbar interbody fusion.	Characterizes postoperative neurological deficits and evolution.	Definitions, ascertainment, and follow-up affect estimates and separation of transient from persistent deficits.
Cummock 2011 [42]	Clinical postoperative symptom series. Minimally invasive transpsoas LLIF.	Describes postoperative thigh symptoms and their recovery.	Thigh pain and sensory symptoms should not be pooled with major motor injury.
Cahill 2012 [43]	Clinical motor-nerve-injury series. Minimally invasive lateral transpsoas access.	Describes motor nerve injuries after lateral transpsoas surgery.	Selected injury series cannot be generalized as a complete complication rate for all practices.
Abel 2018 [44]	Electrodiagnostic clinical injury and recovery series. Lateral retroperitoneal transpsoas access.	Describes prognostic electrodiagnostic features of femoral/plexus injury and recovery.	A selected injured population informs prognosis rather than incidence or proven injury prevention.

All 38 publications from the original manuscript and six additional primary reports published in 2022–2026 are included. Each publication appears once, but rows do not represent independent patient samples. The Sembrano and Isaacs reports concern the same parent cohort; further institutional overlap is possible, including between the older Pumberger report and the longitudinal Burkhard update. Review articles may include primary cohorts cited elsewhere. No participant totals or complication rates were pooled across these dependent sources. Mixed XLIF/OLIF, prepsoas, anatomical, and laboratory evidence is labeled to prevent inappropriate transfer of access-specific conclusions.

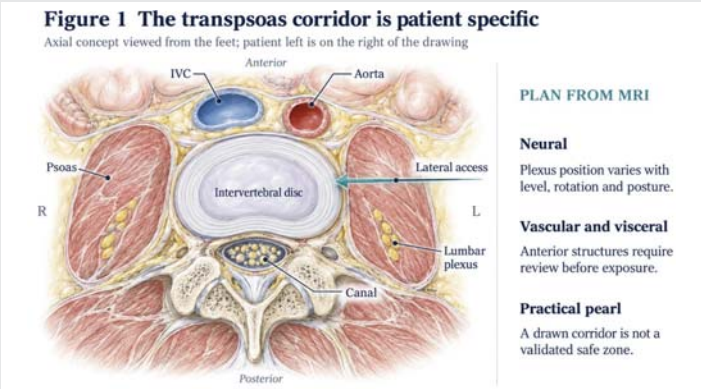

Figure 1: Conceptual axial illustration of the relationship between the lateral disc, psoas, lumbar plexus, spinal canal, major vessels, and anterior visceral structures. The arrow represents a planned lateral trajectory, not a universally safe path. Neural and vascular relationships vary by level, deformity, and patient position. The depiction is not a validated safe-zone map and must not substitute for patient-specific imaging [1,5–10].

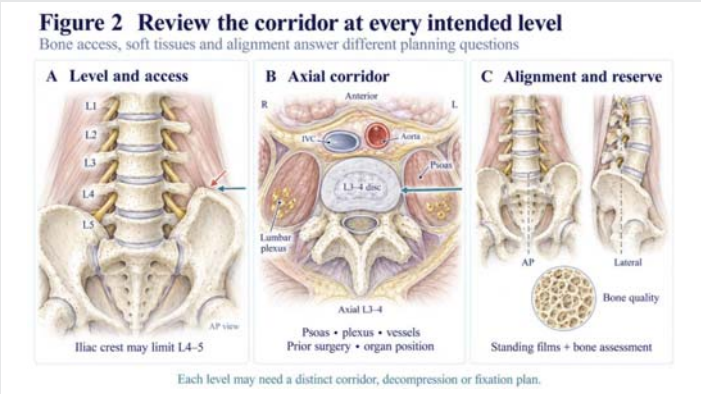

Figure 2: Three complementary components of preoperative planning. A, the relationship of ribs and the iliac crest to the intended disc may restrict exposure, particularly at L4-5. B, axial cross-sectional imaging is reviewed for psoas morphology, neural risk, vessels, organs, and consequences of previous surgery. C, standing radiographs and an assessment of bone strength and instability define alignment and fixation requirements. These panels summarize planning domains rather than measurement thresholds [7,9,20,21].

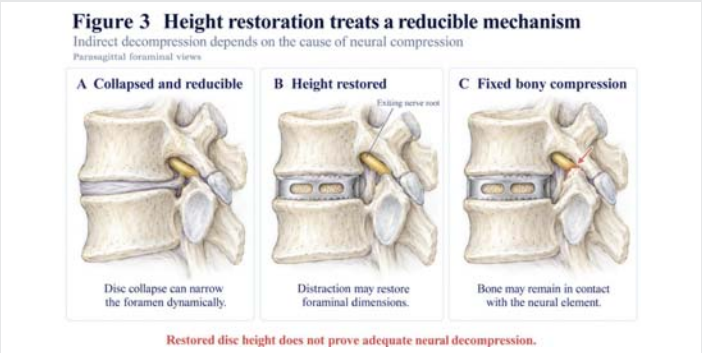

Figure 3: Conceptual sagittal motion-segment diagrams contrasting disc-height loss, restoration of height by an interbody device, and persistent fixed bony compression despite distraction. Indirect decompression can address a reducible component but cannot be assumed to remove a fixed osseous lesion. The neural structure, foramen, and implant are shown schematically, without a quantitative prediction of response [2,3].

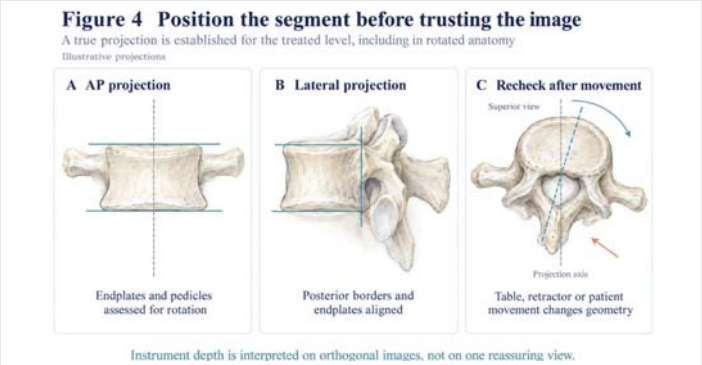

Figure 4: Original conceptual schematic of level-specific fluoroscopic orientation, redrawn for this revision. A, the bilateral pedicles, spinous process and midline, superior and inferior vertebral endplates, and L4–L5 disc space are explicitly labeled. Pedicle symmetry and midline relationships are interpreted in the context of deformity and rotation. B, posterior vertebral body margins and paired endplate contours guide lateral orientation. C, patient, table, beam, or retractor movement prompts renewed confirmation. The drawing is not a patient fluoroscopic image, a calibrated measurement, or a validated safe-zone map. Source: newly generated vector-based drawing using Python and Matplotlib, without reproduction or tracing of third-party graphical material; conceptual technical references [1,34,35].

Citation: Martinez Mateo AL, Rodriguez M, Rosario AR. Pitfalls and Pearls in Transpsoas Lateral Lumbar Interbody Fusion. Open J Orthop Rheumatol. 2026;11(1):15-28. Available from: https://dx.doi.org/10.17352/ojor.000058

Results

Publication accounting and scope

The synthesis comprises the 38 original publications and six additional primary reports [11–16], for 44 publications overall. Thirteen were published from 2022 onward. The original corpus was organized into eight exclusive reporting domains: technique and anatomy, seven publications; indirect decompression, five; endplates and subsidence, seven; positioning, three; complications and surveillance, eight; monitoring, three; alignment and fixation, three; and comparative outcomes, two. These counts describe publications, not independent cohorts or patients. All are reported below and individually in Table 2; Table 1 translates selected findings into operative decisions.

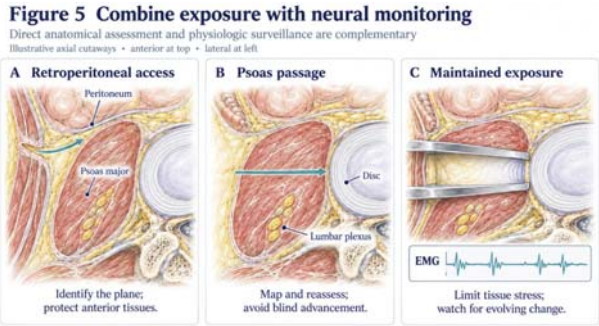

Figure 5: Conceptual sequence of lateral exposure. A, the retroperitoneal plane is established with protection of anterior tissues. B, the psoas corridor is assessed and reassessed during instrument passage. C, the maintained exposure is monitored for tissue stress and evolving physiologic change. Directional stimulation and other monitoring modalities provide complementary information; reassuring signals cannot exclude all traction, ischemic, sensory, or delayed neural injuries [31–33].

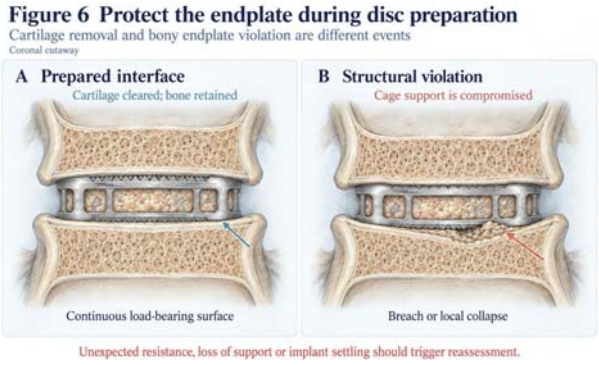

Figure 6: Coronal conceptual diagrams of an interbody interface after disc preparation. A, removal of cartilaginous tissue leaves a continuous load-bearing bony surface. B, a local structural breach reduces support and may permit implant penetration or subsequent settling. The schematic separates preparation from injury and illustrates a mechanism rather than a measured subsidence grade [21,25].

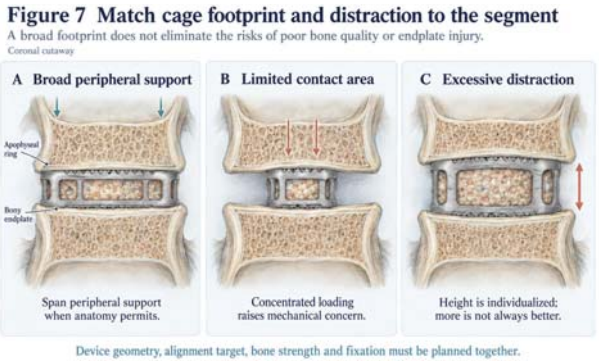

Figure 7: Coronal schematics illustrating broad peripheral implant support, a smaller footprint with concentrated contact, and excessive distraction of a motion segment. Support at the peripheral ring apophyses is a planning principle, not a guarantee against subsidence. Cage width, height, position, and supplemental fixation are selected in the context of endplate integrity, bone quality, and alignment requirements. The drawing does not prescribe implant dimensions [20,22–24,28].

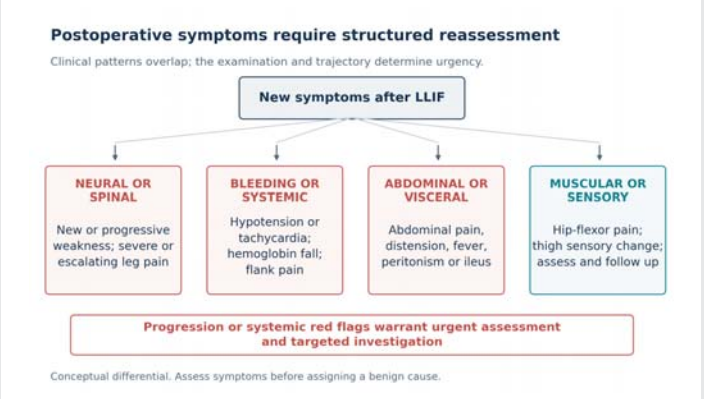

Figure 8: Conceptual differential diagnosis after transpsoas LLIF. New symptoms should be characterized by onset, progression, a documented neurologic examination, and systemic findings. Neural or spinal, bleeding or systemic, and abdominal or visceral patterns may require urgent targeted investigation. Hip-flexor pain and thigh sensory symptoms also warrant assessment and follow-up; their presence alone does not establish a benign muscular cause. The branches overlap and do not represent a validated diagnostic algorithm [38–44].

Technique anatomy and decompression

Ozgur established the retroperitoneal transpsoas technique [1]. Benglis and Uribe characterized plexus relationships and proposed working regions [5,6]; Regev and Kepler examined imaging-based relationships involving roots, vessels, and psoas morphology [7,9]; Davis and Banagan further defined lower-lumbar plexus and nerve-root constraints [8,10]. Together these publications support level-specific assessment rather than universal docking coordinates.

Oliveira documented radiographic enlargement after lateral distraction [2], whereas Wang associated fixed bony lateral recess stenosis with failed indirect decompression [3]. Yingsakmongkol evaluated selection criteria in a mixed XLIF/OLIF population [17]. Kirnaz identified inconsistent failure definitions in the published LLIF literature [18]. Limthongkul tested additional direct decompression in selected prepsoas patients [19]. Thus, the evidence distinguishes the decompression mechanism from corridor-specific neural risk.

Endplates reconstruction and comparative outcomes

Tempel linked subsidence with revision in a stand-alone population [4] and, in a separate publication, related impaired bone density to subsidence [20]. Jones evaluated regional endplate volumetric density [21]. Marchi and Le examined clinical and radiographic subsidence and cage-related factors [22,23]. Pimenta tested spacer-width mechanics [24], and Wu synthesized associations involving bone quality, multilevel treatment, and implant dimensions [25]. Kepler and Issa examined achieved lordosis and cage position [26,27];

Citation: Martinez Mateo AL, Rodriguez M, Rosario AR. Pitfalls and Pearls in Transpsoas Lateral Lumbar Interbody Fusion. Open J Orthop Rheumatol. 2026;11(1):15-28. Available from: https://dx.doi.org/10.17352/ojor.000058

Cappuccino evaluated construct stability in laboratory testing [28]. These findings support preservation of load-bearing support but do not define a universally safe cage size or fixation strategy.

Sembrano reported two-year clinical outcomes and Isaacs companion radiographic findings for the same multicenter MIS lateral-versus-TLIF parent cohort [29,30]. The pair contributes two publications and one shared clinical population. No additional participant count was generated from their separate reports.

Monitoring positioning and complications

Tohmeh evaluated dynamically evoked discrete-threshold EMG [31]; Uribe examined monitoring throughout retraction [32]; and Riley compared monitoring strategies including motor evoked potentials [33]. Ehresman reported a prone case series [34], Sadhwani compared selected lateral and prone cases [35], and Edelbach performed a propensity-matched analysis of selected radiographic endpoints [36]. These studies support technical feasibility and surveillance while leaving causal prevention and rare-harm comparisons uncertain.

Rodgers reported intraoperative and early complications in 600 cases [37]. Rustagi described bowel injury [38], Kueper vascular complications during mini-open lateral access [39], and Dakwar abdominal wall paresis [40]. Pumberger characterized neurological deficits [41], Cummock postoperative thigh symptoms [42], Cahill motor nerve injury [43], and Abel electrodiagnostic features of plexus or femoral injury and recovery [44]. These outcomes differ in mechanism, severity, and follow-up and were not merged into one complication rate.

Additional primary evidence published in 2022 to 2026

Amaral proposed an MRI-based L4–L5 classification in 50 anatomical sites; this was not a prospective clinical validation [11]. Ohiorhenuan evaluated 131 patients and 204 levels, identifying 23 subsidence levels comprising 11 intraoperative endplate violations and 12 later settling events [12]. Mundis reviewed 169 patients: 23 triggered monitoring alerts and 16 had postoperative deficits, demonstrating incomplete correspondence between alerts and clinical outcomes [13].

Soliman reported 365 prone transpsoas cases from 11 centers, including new sensory symptoms and lower-extremity weakness [15]. Patel analyzed 658 patients and found that a 20-minute retractor threshold had 50% sensitivity and 3.4% positive predictive value for postoperative quadriceps palsy [14]. Burkhard compared motor outcomes across two eras in 1,000 selected LLIF cases [16]. These publications refine counseling and surveillance without establishing that prolonged retraction is harmless or that lower observed contemporary risk is caused by surgical era.

Technical note

Define the decompression objective before selecting the corridor

The first technical decision is whether the patient's neural compression can reasonably improve through restoration of disc height and segmental stabilization. Foraminal narrowing associated with a reducible collapsed disc provides a plausible mechanical target. By contrast, a fixed osseous lateral recess lesion remains present after distraction. Reviewing axial images at the symptomatic root, rather than relying on a sagittal impression of generalized stenosis, helps distinguish these mechanisms. The pearl is to identify what must move for the operation to work. The pitfall is assuming that every stenotic segment becomes adequately decompressed when its radiographic height increases. Bony lateral recess stenosis has been associated with failure of indirect decompression, supporting a deliberate plan for direct decompression when fixed compression dominates [2,3].

Figures 1–3 summarize the anatomical corridor, complementary planning domains, and the distinction between restoration of disc height and relief of fixed compression. They are conceptual aids rather than patient-specific measurements or validated predictions of decompression.

Clinical behavior should complement imaging. Improvement when supine, positional symptoms, and demonstrable disc-height reducibility support a dynamic component, although none guarantees success. A published selection framework, derived from a mixed XLIF and OLIF cohort, also considered profound weakness and static stenosis unfavorable for indirect decompression alone [17]. Its combined results should not be interpreted as a transpsoas-specific success estimate. Progressive motor loss or a clearly compressive fixed lesion changes the urgency and method of neural decompression. The operative discussion should distinguish a planned combined procedure from an unplanned revision. A posterior decompression can be part of an appropriate LLIF strategy; avoiding it is not itself an outcome measure. Figure 3 and Infographic 1 organize these decisions without presenting a validated prediction score.

Standing radiographs establish coronal and sagittal alignment, while magnetic resonance imaging defines neural

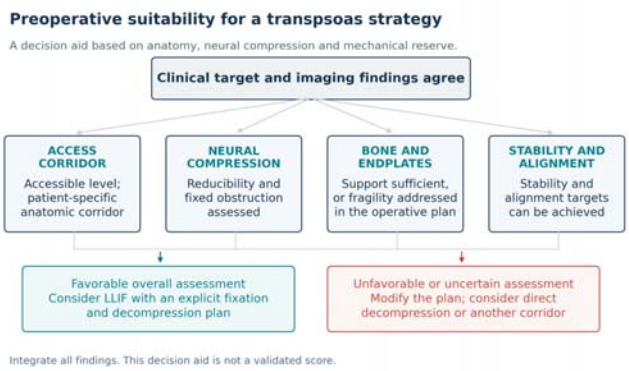

Infographic 1: Preoperative suitability assessment for transpsoas LLIF. Concordance between symptoms and imaging is followed by integrated assessment of the access corridor, the reducibility and composition of neural compression, bone and endplate support, and the requirements for stability and alignment. Favorable findings support consideration of the proposed strategy. Unfavorable or uncertain findings prompt modification of fixation or decompression planning, direct decompression, or selection of another corridor. This is a conceptual decision aid rather than a validated score [3,17,20,21].

Citation: Martinez Mateo AL, Rodriguez M, Rosario AR. Pitfalls and Pearls in Transpsoas Lateral Lumbar Interbody Fusion. Open J Orthop Rheumatol. 2026;11(1):15-28. Available from: https://dx.doi.org/10.17352/ojor.000058

compression, psoas morphology, and the relationship between the disc and surrounding soft tissues. Computed tomography is useful when the extent of osseous stenosis, endplate integrity, prior fusion, or ankylosis is uncertain. Figure 2 summarizes these complementary planning domains. Preoperative bone health requires attention because the decompressive effect depends on preserving the height achieved at surgery. A fragility-fracture history, low bone density, and concerning vertebral or endplate appearance should prompt appropriate evaluation and optimization. Opportunistic CT measures can contribute information, but study-specific thresholds should not replace a complete bone-health assessment [20,21].

Before surgery, the patient should understand which part of the operation addresses pain, compression, instability, or deformity. Consent should include the approach-specific possibility of thigh symptoms and weakness, alongside mechanical failure, residual compression, and the potential need for additional surgery. A large complication series provides useful context but cannot predict the risk of an individual operation or resolve differences in complication definitions [37]. The technical plan should therefore identify the intended benefits, the principal reasons it might fail, and the alternatives available if its assumptions prove incorrect.

Treat each level as a separate anatomical problem

The transpsoas trajectory passes through a muscle containing the lumbar plexus. Cadaveric and imaging studies describe level-dependent changes in the position of neural structures and vessels; their measurements are population observations rather than a patient-specific guarantee [5–7]. Preoperative review should therefore include the entire intended trajectory, from the skin and retroperitoneal compartment to the ipsilateral annulus and contralateral boundary. A convenient disc target does not establish that the intervening corridor is favorable. Figure 1 deliberately illustrates relationships without marking a universally safe quadrant.

L4-L5 deserves particular scrutiny because the plexus may occupy a more anterior position and the iliac crest can constrain access. Psoas configuration, vertebral rotation, vascular position, and the achievable orthogonal trajectory should be evaluated together [8,9]. Forcing an oblique instrument trajectory to bypass the crest can create a different operative geometry from the one used to plan a direct lateral approach. If a satisfactory corridor cannot be established, selecting another approach or revising the operative plan is a technical success, not a failure to complete the exposure. Cadaveric observations of neural structures within proposed working regions reinforce that no surface landmark eliminates this judgment [10].

Upper lumbar access introduces a different relationship to the ribs, diaphragm, and pleural boundary. The intended exposure and closure must reflect that anatomy rather than simply reproducing a lower lumbar incision. Previous retroperitoneal surgery, scarring, and unusual vascular or visceral relationships may further change the approach. Standard transpsoas LLIF also should not be extended conceptually to routine L5-S1 access. That level commonly requires a different corridor. Likewise, OLIF uses an anterior-to-psoas route and should retain its own technical description rather than being treated as an interchangeable name for transpsoas surgery.

Establish positioning and imaging before incision

For a lateral decubitus procedure, the patient is secured so that subsequent manipulation does not rotate the pelvis or thorax unpredictably. Dependent pressure points and peripheral nerves require protection, and abdominal compression should be avoided. Table adjustment can improve access, but excessive positional correction may change the anatomy being approached. Hip position, table configuration, and the selected approach side should form a coherent plan. After positioning, the team confirms that the intended levels remain accessible and that imaging can depict their endplates without relying on a single global view of the lumbar spine.

True anteroposterior and lateral images must be obtained for the individual operative level. In the anteroposterior projection, the bilateral pedicles, spinous process relative to the midline, superior and inferior vertebral endplates, and target disc space should be identified; pedicle symmetry must be interpreted in the context of vertebral rotation and deformity. In the lateral projection, posterior vertebral body margins and paired endplate contours should be superimposed as the anatomy permits. The wrong-level check includes reconciliation of transitional anatomy and the preoperative numbering convention. Figure 4A labels these landmarks, Figure 4B illustrates lateral orientation, and Figure 4C identifies circumstances requiring renewed confirmation.

Skin marking should reflect the final position and the actual fluoroscopic target. During multilevel surgery, rechecking orientation after table movement, patient repositioning, or retractor adjustment prevents the initial image from becoming an outdated reference. Navigation, when used, adds information but also introduces registration and reference-frame dependencies. Unexpected disagreement between anatomy and image guidance requires reassessment. Similarly, a prone single-position workflow changes access, positioning, and imaging logistics; it is not simply the lateral decubitus operation performed without turning the patient. Its technical advantages must be considered alongside the team's experience and the anatomy of the selected case [34–36].

Develop the retroperitoneal exposure without blind commitment

The exposure proceeds through the abdominal wall with attention to its layers and the nerves supplying them. Muscle splitting and controlled entry preserve orientation and help avoid unnecessary injury to the abdominal wall. The retroperitoneal compartment must be identified before advancing toward the psoas. Tissue assumed to be displaced safely may instead represent peritoneum, bowel, or a structure altered by prior surgery. Direct observation and careful tactile confirmation are complementary; neither justifies advancing

Citation: Martinez Mateo AL, Rodriguez M, Rosario AR. Pitfalls and Pearls in Transpsoas Lateral Lumbar Interbody Fusion. Open J Orthop Rheumatol. 2026;11(1):15-28. Available from: https://dx.doi.org/10.17352/ojor.000058

an instrument through an unidentified resistance. The original transpsoas technique establishes the operative route, but its reproducibility depends on respecting these tissue boundaries [1].

When the expected plane is absent, the appropriate response is to pause and establish the anatomy. Enlarging a poorly understood exposure by force can transform a manageable access problem into visceral injury. Instruments and retractors also require attention during withdrawal, when tissue may return into the working corridor. Published bowel injuries demonstrate that retroperitoneal access does not remove visceral risk, and some presentations may be delayed [38]. Major-vessel injury is uncommon in reported series but demands immediate recognition and an established means of obtaining specialist assistance [39].

Abdominal wall denervation can produce postoperative weakness or bulging even without a fascial defect. This complication differs from an incisional hernia and is relevant to both dissection and postoperative examination [40]. The pearl is to preserve the abdominal wall as a functioning structure, not merely to create the smallest skin opening. A restricted incision that compromises identification and control of the tissue planes does not necessarily represent a less invasive operation.

Use neuromonitoring as feedback throughout the exposure

Before transpsoas dilation, the surgeon, anesthesia team, and neurophysiologist should agree on the monitoring modalities, baseline signals, anesthetic constraints, and response to an alert. Directional triggered electromyography can help identify nearby motor neural structures, but it is not a direct measurement of the distance to a nerve. Initial readings must be interpreted in the context of electrode function, stimulation conditions, neuromuscular blockade, and anatomy. The protective value lies in integrating feedback into the exposure, rather than treating a numerical threshold as permission to proceed [31].

Dilation and retractor deployment are separate opportunities to reassess the corridor. A satisfactory initial reading does not establish that the plexus remains protected after expansion, blade movement, or prolonged retraction. Neural injury can involve compression, stretch, or impaired perfusion, and sensory structures are not fully represented by motor EMG responses. A prospective L4–L5 study associated retraction duration and changes in triggered EMG thresholds with postoperative motor neuropraxia [32]. Interpretation of apparently false-positive alerts is complicated when the surgical response to an alert changes the eventual neurological outcome. Neither an isolated current threshold nor a published time interval defines a universally safe exposure.

The operative team should know the current retractor duration and minimize unnecessary expansion and dwell time. Preparation of instruments and implants before retraction reduces avoidable delay. Retractor release or repositioning should be guided by the anatomy, monitoring findings, and operative circumstances rather than an unvalidated timer alone. Motor evoked potentials may add information about motor pathway integrity; observational comparisons suggest potential value, although differences in patients and practice limit causal conclusions [33]. Figure 5 illustrates the distinction between nerve mapping and surveillance of a changing operative exposure.

Recent studies reinforce the limits of single-variable reassurance. A protocol cohort documented deficits despite absent alerts [13], while a multicenter analysis found poor predictive performance for the 20-minute threshold [14]. Retraction should remain controlled and efficient, with ongoing anatomical and physiological assessment.

During multilevel procedures, efficient sequencing should preserve the same checks at every level. Fatigue, accumulated operative time, and the temptation to reproduce a satisfactory exposure from the preceding disc can weaken that discipline. The surgeon should reassess imaging, corridor, monitoring, and implant support whenever the operative level changes. An uncomplicated earlier level does not validate the next exposure. Likewise, leaving all difficult decisions until the final level can prolong the least favorable retraction. Anticipating the order of treatment helps keep technical efficiency compatible with anatomical judgment.

An alert requires a coordinated response: stop the provoking maneuver, assess the retractor and instrument position, evaluate physiological and technical causes, and communicate the response to corrective measures. Persistent concern may require abandoning the corridor or changing the plan. Infographic 2 summarizes this reassessment sequence without prescribing a universal monitoring threshold or safe retraction duration.

Prepare the disc while preserving the supporting endplate

After the disc has been confirmed, the annular opening and discectomy are performed under controlled visualization and

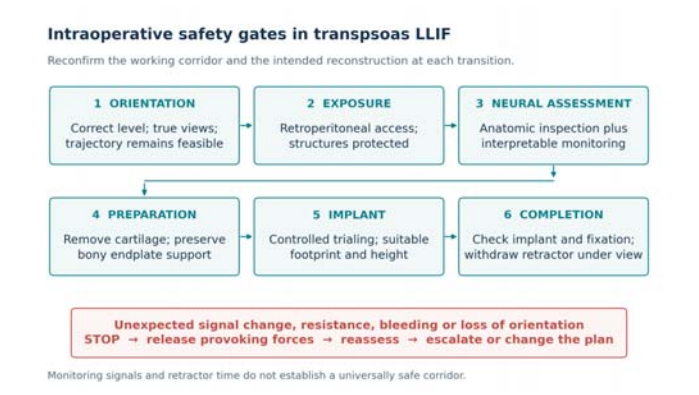

Infographic 2: Intraoperative safety gates for transpsoas LLIF. Orientation, exposure, neural assessment, disc preparation, implant insertion, and completion each require a deliberate reassessment before the next maneuver. An unexpected monitoring change, loss of orientation, excessive resistance, or bleeding should trigger cessation of the provoking maneuver, release of relevant forces when appropriate, reassessment and escalation, or a change in strategy. The sequence is conceptual and does not define a universal electromyographic threshold or safe retractor duration [1,25,31–33].

Citation: Martinez Mateo AL, Rodriguez M, Rosario AR. Pitfalls and Pearls in Transpsoas Lateral Lumbar Interbody Fusion. Open J Orthop Rheumatol. 2026;11(1):15-28. Available from: https://dx.doi.org/10.17352/ojor.000058

imaging. Instrument direction is referenced to the actual disc plane. The contralateral side is not an unlimited working space: vessels, annulus, and surrounding tissues remain relevant beyond the far margin of the vertebral body. Contralateral release, when required, must be controlled and appropriate to the intended construct. Unexpected resistance or an instrument position that does not match the planned depth should trigger reassessment rather than additional force.

The objective of endplate preparation is to remove disc and cartilaginous tissue while preserving the supporting osseous endplate. Aggressive curettage can create a cavity that is initially obscured by the working channel and becomes apparent only during trialing or cage insertion. Figure 6 separates cartilage removal from structural endplate violation. Poor bone quality and endplate vulnerability narrow the margin for error; regional endplate density may contain information that is not captured by a single vertebral measurement [21]. Tactile feedback therefore remains important even when imaging appears satisfactory.

Trialing should evaluate fit, alignment, and mechanical behavior rather than simply identify the largest implant that can be inserted. An abrupt change in resistance, unexpected trial advancement, or new endplate irregularity may indicate structural injury. The surgeon should assess the event before proceeding with the planned implant. Recognizing a breach during the procedure allows reconsideration of cage position, supplemental fixation, and the intended reliance on indirect decompression. Continuing to distract an injured endplate risks increasing the defect while creating an exaggerated impression of immediate height restoration.

Match the cage to the vertebral footprint and available height

The cage must balance footprint, height, lordosis, insertion trajectory, and the patient's endplate anatomy. A broad implant with appropriate peripheral support distributes load differently from a narrow implant concentrated centrally. Clinical studies and biomechanical work support the importance of cage dimensions, although patient anatomy and construct design limit simple translation into a universal implant rule [22–24]. Figure 7 illustrates this mechanical principle. The pearl is to select an implant that the segment can support. The pitfall is equating a taller cage with a better decompression.

Overdistraction may damage the endplate, increase insertion force, and compromise the very height that indirect decompression requires. Restoration should be judged against reducibility, bone quality, and the behavior of the trial, not an arbitrary target height. Implant expansion does not remove these constraints. Similarly, the nominal lordotic angle of a cage is not identical to the lordosis achieved by the motion segment. Residual posterior constraint, endplate shape, cage position, and the posterior fixation strategy all influence the final result [26,27].

Before final impaction and release, the implant position should be assessed in appropriate orthogonal views. Posterior malposition can threaten neural structures, while anterior or lateral displacement creates different risks. The cage should achieve its intended support without being left across an unrecognized endplate defect. A difficult insertion is information about the segment and trajectory, not merely an obstacle requiring greater force. Final orthogonal imaging should document both cage position and endplate condition so that subsequent settling can be distinguished from injury already present at the index procedure.

Plan fixation and correction as parts of the same construct

Stand-alone LLIF and LLIF supplemented with posterior or lateral fixation impose different mechanical demands on the cage-endplate interface. The decision should consider instability, deformity, bone quality, number of treated levels, posterior-element competence, and the consequences of losing indirect decompression. Supplemental fixation can improve construct stability in biomechanical models, but it cannot restore a damaged endplate or make an unsuitable decompression mechanism effective [28]. It should be planned before cage insertion rather than considered only after a mechanical problem becomes visible.

In deformity surgery, each lateral level contributes to a larger alignment objective. Local disc-height restoration should be interpreted within the planned distribution of lumbar lordosis and the patient's overall balance. The posterior stage may alter the correction achieved by the cage, and the intended sequence should account for those interactions. Direct decompression remains appropriate when the neural target requires it. Anterior longitudinal ligament release and anterior column realignment introduce additional instability and vascular considerations; they require a separate technical strategy and should not be implied by routine LLIF terminology.

Close with attention to the approach and examine beyond the incision

Before retractor removal, the field should be assessed for bleeding and tissue entrapment. Withdrawal is controlled so that the approach can be inspected rather than abandoned as soon as the cage is seated. Fascial closure and assessment of the abdominal wall are important even when the exposure is limited. The operative record should preserve the treated levels, approach side, implants, relevant monitoring changes, recognized endplate injury, and any change in the planned decompression or fixation strategy. These details help interpret subsequent symptoms and images.

The early neurological examination should distinguish pain-limited hip flexion from objective weakness involving knee extension or other plexus distributions. Thigh pain, sensory change, hip-flexor weakness, and femoral motor deficit represent different outcomes and should not be merged into a single reassuring category. Clinical series describe varying postoperative patterns and recovery, while severe plexus injuries require careful assessment and follow-up [41–44]. A baseline examination documented before surgery is essential

Citation: Martinez Mateo AL, Rodriguez M, Rosario AR. Pitfalls and Pearls in Transpsoas Lateral Lumbar Interbody Fusion. Open J Orthop Rheumatol. 2026;11(1):15-28. Available from: https://dx.doi.org/10.17352/ojor.000058

for recognizing a new deficit. Figure 8 emphasizes the clinical distinction between an expected postoperative symptom and a finding that warrants urgent investigation.

New or progressive motor deficit, severe disproportionate pain, hemodynamic change, abdominal deterioration, or systemic illness requires prompt evaluation for a structural or systemic cause. Possible explanations include implant malposition, compressive hematoma, plexus injury, vascular injury, and visceral injury; the investigation should follow the presentation rather than assume that all approach-side symptoms are neuropraxia. Persistent radicular symptoms after otherwise satisfactory implant placement require reassessment of residual compression and the need for direct decompression [18]. Delayed recovery should not become a reason to postpone investigation of a potentially remediable lesion.

Follow-up should connect clinical improvement with maintenance of the reconstruction. Subsidence is important when it produces loss of foraminal height, recurrent symptoms, instability, or a need for revision, rather than solely as an isolated radiographic label [4]. Immediate endplate injury and later settling should be reported separately. Serial assessment of neurological findings, pain, function, and imaging permits a more useful account of recovery than fusion status alone. The final pearl is to regard postoperative surveillance as the continuation of the original decompression and mechanical plan.

Discussion

Interpreting a pearl within its evidence

Technical recommendations must retain the conditions under which their supporting findings were observed. Historical cage studies and laboratory experiments support broad load-bearing contact and construct stability [20–24,28]. Contemporary subsidence analysis also associated cage-to-endplate support area with outcome [12], but implant material, footprint, bone quality, and surgeon selection are interrelated. A favorable unadjusted material comparison cannot establish an independent material effect. Supplemental fixation likewise improves initial laboratory stability without proving a universal clinical indication or compensating for an unsuitable decompression mechanism.

Sembrano and Isaacs reported clinical and radiographic results from the same prospective multicenter parent comparison, which included randomized and observational arms [29,30]. Their publications provide complementary outcomes rather than two independent trials. The findings apply to selected low-grade degenerative spondylolisthesis and do not establish superiority across fixed stenosis, multilevel deformity, severe bone fragility, or revision surgery. Radiographic restoration, fusion, disability, and blood loss are distinct outcomes; their clinical importance cannot be inferred from one another.

Selection also limits extrapolation in indirect decompression. Yingsakmongkol studied a mixed XLIF/OLIF cohort [17], while the randomized comparison of additional direct decompression by Limthongkul used a prepsoas corridor in selected patients [19]. These publications help explain the role of reducible disc collapse and favorable symptom behavior. They cannot establish transpsoas access safety or justify leaving fixed compression untreated. Table 2 identifies these corridor boundaries explicitly.

Positioning and the evolution of technique

Prone transpsoas surgery offers interbody reconstruction and posterior instrumentation without repositioning. Recent case series, a multicenter complication cohort, and nonrandomized comparisons broaden the experience reported with this position [15,34–36]. Their different patient selection, examination schedules, and follow-up prevent direct comparison of crude complication percentages. The 2026 propensity-matched analysis evaluated selected radiographic noninferiority endpoints [36]; it does not establish equivalence for uncommon neural, visceral, or vascular injuries. Decisions about position therefore remain conditional on anatomy, the planned reconstruction, and team experience.

Changing position also changes instrument ergonomics, soft tissue relationships, and the way radiographs are acquired. Familiarity with lateral decubitus LLIF does not eliminate the need to learn these relationships in prone surgery. The principles of level specific imaging, controlled access, continued monitoring, endplate preservation, and an available alternative approach remain applicable. The appropriate position is the one that permits the planned reconstruction with acceptable access and reliable visualization in the particular patient and operative setting.

Biases and other limitations of the evidence

Purposive retrieval and the absence of independent duplicate assessment make this review vulnerable to selection, citation, and confirmation bias. Studies consistent with familiar technical preferences may be easier to locate or emphasize, while less visible or unfavorable findings may be missed. Because retrieval was not exhaustive and unpublished evidence was not systematically sought, publication bias cannot be quantified or excluded. The direction and magnitude of these biases remain unknown; the proportion of favorable published reports should not be interpreted as an effectiveness estimate.

Clinical selection and applicability

Selection into treatment can favor apparently successful indirect decompression when patients with fixed compression, profound weakness, or unfavorable anatomy are excluded. The early XLIF failure analysis [3], the 2022 mixed-corridor selection study [17], and the 2024 selected-patient prepsoas trial [19] illustrate why eligibility must accompany any success estimate. In the contemporary anatomy classification [11], none of the type III anatomies underwent lateral surgery, so observed operative outcomes cannot directly quantify risk in the excluded anatomy. This is a selection and verification problem; mixing XLIF and OLIF adds exposure heterogeneity and limits transportability of access-specific conclusions.

Citation: Martinez Mateo AL, Rodriguez M, Rosario AR. Pitfalls and Pearls in Transpsoas Lateral Lumbar Interbody Fusion. Open J Orthop Rheumatol. 2026;11(1):15-28. Available from: https://dx.doi.org/10.17352/ojor.000058

Monitoring and response to alerts

Monitoring comparisons are susceptible to confounding by indication, surgeon experience, anesthetic conditions, and protocol changes [13,31–33]. An alert followed by corrective action and no deficit may represent a successful rescue rather than an intrinsically false signal. Conversely, absent alerts do not exclude injury outside the monitored structures or mechanisms. This treatment-response effect distorts simple sensitivity or false-positive calculations when the response itself changes the outcome. The retrospective 20-minute analysis also had few injury events and incomplete anatomical and procedural covariates [14], leaving residual confounding. A poor threshold predictor should not be reinterpreted as proof of absent retraction-related injury.

Positioning learning curves and surgical era

The 2024 single-surgeon positioning comparison and the 2026 propensity-matched study remain vulnerable to preferential selection, learning-curve effects, and unmeasured baseline differences [35,36]. Matching can balance recorded variables but cannot remove unrecorded confounders. The multicenter prone series had no conventional-position control [15], and low counts of uncommon serious events primarily produce imprecision rather than demonstrated equivalence. Similarly, the 1,000-case longitudinal update showed better observed motor outcomes in the later era [16], but changes in selection, implants, workflow, and outcome ascertainment can confound an era comparison. Operative duration in that report is not interchangeable with retractor dwell time.

Outcome measurement follow up and denominators

Outcome misclassification can arise when thigh dysesthesia, pain-limited hip flexion, objective quadriceps weakness, and revision surgery are combined [16,37,41–44]. Different examination schedules and nonblinded clinical assessment can create detection bias, while incomplete follow-up may cause attrition bias if recovery or delayed failure differs among missing patients. The earlier failure review and the 2022 subsidence review demonstrate heterogeneous definitions [18,25]; the 2022 primary subsidence cohort further separates endplate injury from later settling [12]. Different definitions also create heterogeneity, which is not automatically bias. Multilevel observations within a patient are correlated and should not be treated as independent patients.

Dependent evidence and mechanistic indirectness

Counting companion clinical and radiographic reports as independent cohorts would over-weight their conclusions [29,30]. Potential overlap between the older Pumberger series and the later institutional motor-deficit update also cannot be excluded [16,41]. Systematic reviews may include primary studies cited elsewhere, so publication counts do not represent independent replications [18,25]. Cadaveric and laboratory studies additionally provide indirect evidence for clinical safety and durability [5–10,24,28]. Static anatomy, simplified loading, small samples, and sparse clinical events constrain generalizability and precision; these are distinct from a demonstrable directional bias. No claim is made that this narrative assessment replaces a formal study-level risk-of-bias evaluation.

Future evaluation should prospectively define eligibility, reasons for changing strategy, neurological examination schedules, and the distinction between access injury, inadequate decompression, and mechanical failure. Reports should separate patient-based and level-based denominators, account for clustering of multiple levels within patients, distinguish transient sensory symptoms from persistent motor deficits, and distinguish radiographic subsidence from symptomatic failure. Testing the complete workflow against usual practice would address a question that a collection of individually plausible pearls cannot resolve.

Conclusion

Successful transpsoas LLIF requires agreement between the target pathology, available corridor, anticipated decompression, and mechanical reconstruction. The most consequential pitfalls are accepting a marginal corridor, trusting neuromonitoring as a guarantee, treating fixed stenosis with distraction alone, and sacrificing the endplate to achieve implant size or correction. The corresponding pearls are deliberate selection, repeated verification, controlled tissue handling, preservation of structural support, and prompt recognition of an evolving complication. An alternative approach or planned direct decompression is a constructive technical decision when these requirements cannot be reconciled.

Declarations

Ethics approval and consent to participate: Not applicable. This manuscript is a literature-based narrative review and does not involve a new study with human participants.

Consent for publication: Not applicable to the newly developed conceptual Figure 4. Any patient-derived material, if included, requires the appropriate consent and permissions.

Data availability: No new clinical dataset was generated for this manuscript. The sources supporting this review are cited in the reference list and summarized in Table 2.

Author contributions

Alberto Luis Martinez Mateo: Conceptualization, Methodology, Investigation, Writing – Original Draft, and Writing – Review & Editing.

Madeline Rodriguez: Investigation, Data Curation, Formal Analysis, Validation, and Writing – Review & Editing.

Andreina Rosario Rosario: Conceptualization, Methodology, Project Administration, Visualization, Writing – Original Draft, and Writing – Review & Editing.

Renat Nurmukhammedov: Conceptualization, Validation, Supervision, Resources, and Writing – Review & Editing.

Citation: Martinez Mateo AL, Rodriguez M, Rosario AR. Pitfalls and Pearls in Transpsoas Lateral Lumbar Interbody Fusion. Open J Orthop Rheumatol. 2026;11(1):15-28. Available from: https://dx.doi.org/10.17352/ojor.000058

All authors contributed to the manuscript, reviewed and approved the final version, and agreed to be accountable for the integrity and accuracy of the work.

Funding: No external funding was received for this work.

Illustration attribution and permissions: Figure 4 was newly created for this manuscript and does not reproduce third-party images. All remaining illustrations are subject to the applicable attribution and permission requirements.

Editorial and generative AI assistance: ChatGPT (OpenAI) was used during the revision process to assist with literature identification, language editing, and the preparation of code for the conceptual Figure 4. The authors reviewed and verified the manuscript content and take full responsibility for its accuracy and integrity.

(Supplementary-Figure-4)

References

1. Ozgur BM, Aryan HE, Pimenta L, Taylor WR. Extreme lateral interbody fusion (XLIF): a novel surgical technique for anterior lumbar interbody fusion. Spine J. 2006;6(4):435-43. Available from: https://doi.org/10.1016/j.spinee.2005.08.012

2. Oliveira L, Marchi L, Coutinho E, Pimenta L. A radiographic assessment of the ability of the extreme lateral interbody fusion procedure to indirectly decompress the neural elements. Spine (Phila Pa 1976). 2010;35(26 Suppl):S331-7. Available from: https://doi.org/10.1097/BRS.0b013e3182022db0

3. Wang TY, Nayar G, Brown CR, Pimenta L, Karikari IO, Isaacs RE. Bony lateral recess stenosis and other radiographic predictors of failed indirect decompression via extreme lateral interbody fusion: multi-institutional analysis of 101 consecutive spinal levels. World Neurosurg. 2017;106:819-26. Available from: https://doi.org/10.1016/j.wneu.2017.07.045

4. Tempel ZJ, McDowell MM, Panczykowski DM, Gandhoke GS, Hamilton DK, Okonkwo DO, et al. Graft subsidence as a predictor of revision surgery following stand-alone lateral lumbar interbody fusion. J Neurosurg Spine. 2018;28(1):50-6. Available from: https://doi.org/10.3171/2017.5.SPINE16427

5. Benglis DM, Vanni S, Levi AD. An anatomical study of the lumbosacral plexus as related to the minimally invasive transpsoas approach to the lumbar spine. J Neurosurg Spine. 2009;10(2):139-44. Available from: https://doi.org/10.3171/2008.10.SPI08479

6. Uribe JS, Arredondo N, Dakwar E, Vale FL. Defining the safe working zones using the minimally invasive lateral retroperitoneal transpsoas approach: an anatomical study. J Neurosurg Spine. 2010;13(2):260-6. Available from: https://doi.org/10.3171/2010.3.SPINE09766

7. Regev GJ, Chen L, Dhawan M, Lee YP, Garfin SR, Kim CW. Morphometric analysis of the ventral nerve roots and retroperitoneal vessels with respect to the minimally invasive lateral approach in normal and deformed spines. Spine (Phila Pa 1976). 2009;34(12):1330-5. Available from: https://doi.org/10.1097/BRS.0b013e3181a029e1

8. Davis TT, Bae HW, Mok JM, Rasouli A, Delamarter RB. Lumbar plexus anatomy within the psoas muscle: implications for the transpsoas lateral approach to the L4-L5 disc. J Bone Joint Surg Am. 2011;93(16):1482-7. Available from: https://doi.org/10.2106/JBJS.J.00962

9. Kepler CK, Bogner EA, Herzog RJ, Huang RC. Anatomy of the psoas muscle and lumbar plexus with respect to the surgical approach for lateral transpsoas interbody fusion. Eur Spine J. 2011;20(4):550-6. Available from: https://doi.org/10.1007/s00586-010-1593-5

10. Banagan K, Gelb D, Poelstra K, Ludwig S. Anatomic mapping of lumbar nerve roots during a direct lateral transpsoas approach to the spine: a cadaveric study. Spine (Phila Pa 1976). 2011;36(11):E687-91. Available from: https://doi.org/10.1097/BRS.0b013e3181ec5911

11. Amaral R, Pokorny G, Alvernia JE, Pimenta L. L4-L5 anatomy classification system for lateral lumbar interbody fusion. Neurosurg Rev. 2024;47(1):529. Available from: https://doi.org/10.1007/s10143-024-02740-2

12. Ohiorhenuan IE, Walker CT, Zhou JJ, Godzik J, Sagar S, Farber SH, et al. Predictors of subsidence after lateral lumbar interbody fusion. J Neurosurg Spine. 2022;37(2):183-7. Available from: https://doi.org/10.3171/2022.1.SPINE201893

13. Mundis GM Jr, Record NC, Shahidi B, Lakomkin N, Carnelian A, Brady KC, et al. Incidence of postoperative neurological deficit with the use of an intraoperative neuromonitoring protocol for lateral lumbar interbody fusion. J Neurosurg Spine. 2024;40(2):162-8. Available from: https://doi.org/10.3171/2023.9.SPINE23263

14. Patel A, McDermott MR, Mundis GM Jr, Eastlack RK, Buckland AJ, Menezes CM, et al. The "20-minute rule" in lateral lumbar interbody fusion. Fact or fiction? A multi-center analysis of 658 patients. Global Spine J. 2025;15(7):3189-98. Available from: https://doi.org/10.1177/21925682251321490

15. Soliman MAR, Diaz-Aguilar L, Kuo CC, et al. Complications of the prone transpsoas lateral lumbar interbody fusion for degenerative lumbar spine disease: a multicenter study. Neurosurgery. 2023;93(5):1106-11. Available from: https://doi.org/10.1227/NEU.0000000000002555

16. Burkhard MD, Jones C, Ortiz S, et al. Lateral lumbar interbody fusion: an update on motor deficits in 1000 patients across two decades. Global Spine J. 2026;16(7):3040-9. Available from: https://doi.org/10.1177/21925682261421507

17. Yingsakmongkol W, Jitpakdee K, Kerr S, Limthongkul W, Kotheeranurak V, Singhatanadgige W. Successful criteria for indirect decompression with lateral lumbar interbody fusion. Neurospine. 2022;19(3):805-15. Available from: https://doi.org/10.14245/ns.2244058.029

18. Kirnaz S, Navarro-Ramirez R, Gu J, Wipplinger C, Hussain I, Adjei J, et al. Indirect decompression failure after lateral lumbar interbody fusion-reported failures and predictive factors: systematic review. Global Spine J. 2020;10(2 Suppl):8S-16S. Available from: https://doi.org/10.1177/2192568219876244

19. Limthongkul W, Thanapura C, Jitpakdee K, Praisarnti P, Kotheeranurak V, Yingsakmongkol W, et al. Is direct decompression necessary for lateral lumbar interbody fusion (LLIF)? A randomized controlled trial comparing direct and indirect decompression with LLIF in selected patients. Neurospine. 2024;21(1):342-51. Available from: https://doi.org/10.14245/ns.2346906.453

20. Tempel ZJ, Gandhoke GS, Okonkwo DO, Kanter AS. Impaired bone mineral density as a predictor of graft subsidence following minimally invasive transpsoas lateral lumbar interbody fusion. Eur Spine J. 2015;24 Suppl 3:414-9. Available from: https://doi.org/10.1007/s00586-015-3844-y

21. Jones C, Okano I, Salzmann SN, Reisener MJ, Chiapparelli E, Shue J, et al. Endplate volumetric bone mineral density is a predictor for cage subsidence following lateral lumbar interbody fusion: a risk factor analysis. Spine J. 2021;21(10):1729-37. Available from: https://doi.org/10.1016/j.spinee.2021.02.021

22. Marchi L, Abdala N, Oliveira L, Amaral R, Coutinho E, Pimenta L. Radiographic and clinical evaluation of cage subsidence after stand-alone lateral interbody fusion. J Neurosurg Spine. 2013;19(1):110-8. Available from: Available from: https://doi.org/10.3171/2013.4.SPINE12319

23. Le TV, Baaj AA, Dakwar E, Burkett CJ, Murray G, Smith DA, et al. Subsidence of polyetheretherketone intervertebral cages in minimally invasive lateral retroperitoneal transpsoas lumbar interbody fusion. Spine (Phila Pa

Citation: Martinez Mateo AL, Rodriguez M, Rosario AR. Pitfalls and Pearls in Transpsoas Lateral Lumbar Interbody Fusion. Open J Orthop Rheumatol. 2026;11(1):15-28. Available from: https://dx.doi.org/10.17352/ojor.000058

1976). 2012;37(14):1268-73. Available from: https://doi.org/10.1097/BRS.0b013e3182458b2f

24. Pimenta L, Turner AW, Dooley ZA, Parikh RD, Peterson MD. Biomechanics of lateral interbody spacers: going wider for going stiffer. ScientificWorldJournal. 2012;2012:381814. Available from: https://doi.org/10.1100/2012/381814

25. Wu H, Shan Z, Zhao F, Cheung JPY. Poor bone quality, multilevel surgery, and narrow and tall cages are associated with intraoperative endplate injuries and late-onset cage subsidence in lateral lumbar interbody fusion: a systematic review. Clin Orthop Relat Res. 2022;480(1):163-88. Available from: https://doi.org/10.1097/CORR.0000000000001915

26. Kepler CK, Huang RC, Sharma AK, Meredith DS, Metitiri O, Sama AA, et al. Factors influencing segmental lumbar lordosis after lateral transpsoas interbody fusion. Orthop Surg. 2012;4(2):71-5. Available from: https://doi.org/10.1111/j.1757-7861.2012.00175.x

27. Issa TZ, Lee Y, Lambrechts MJ, Tran KS, Trenchfield D, Baker S, et al. The impact of cage positioning on lumbar lordosis and disc space restoration following minimally invasive lateral lumbar interbody fusion. Neurosurg Focus. 2023;54(1):E7. Available from: https://doi.org/10.3171/2022.10.FOCUS22607

28. Cappuccino A, Cornwall GB, Turner AW, Fogel GR, Duong HT, Kim KD, et al. Biomechanical analysis and review of lateral lumbar fusion constructs. Spine (Phila Pa 1976). 2010;35(26 Suppl):S361-7. Available from: https://doi.org/10.1097/BRS.0b013e318202308b

29. Sembrano JN, Tohmeh A, Isaacs R, SOLAS Degenerative Study Group. Two-year comparative outcomes of MIS lateral and MIS transforaminal interbody fusion in the treatment of degenerative spondylolisthesis: Part I: clinical findings. Spine (Phila Pa 1976). 2016;41 Suppl 8:S123-32. Available from: https://doi.org/10.1097/BRS.0000000000001471

30. Isaacs RE, Sembrano JN, Tohmeh AG, SOLAS Degenerative Study Group. Two-year comparative outcomes of MIS lateral and MIS transforaminal interbody fusion in the treatment of degenerative spondylolisthesis: Part II: radiographic findings. Spine (Phila Pa 1976). 2016;41 Suppl 8:S133-44. Available from: https://doi.org/10.1097/BRS.0000000000001472

31. Tohmeh AG, Rodgers WB, Peterson MD. Dynamically evoked, discrete-threshold electromyography in the extreme lateral interbody fusion approach. J Neurosurg Spine. 2011;14(1):31-7. Available from: https://doi.org/10.3171/2010.9.SPINE09871

32. Uribe JS, Isaacs RE, Youssef JA, Khajavi K, Balzer JR, Kanter AS, et al. Can triggered electromyography monitoring throughout retraction predict postoperative symptomatic neuropraxia after XLIF? Results from a prospective multicenter trial. Eur Spine J. 2015;24 Suppl 3:378-85. Available from: https://doi.org/10.1007/s00586-015-3871-8

33. Riley MR, Doan AT, Vogel RW, Aguirre AO, Pieri KS, Scheid EH. Use of motor evoked potentials during lateral lumbar interbody fusion reduces postoperative deficits. Spine J. 2018;18(10):1763-78. Available from: https://doi.org/10.1016/j.spinee.2018.02.024

34. Ehresman J, Farber SH, Battista M, Lee KE, Lee BS. Clinical outcomes and radiographic results of prone transpsoas lateral lumbar interbody fusion: a single-institution case series. Neurosurgery. 2025;96(4):763-8. Available from: https://doi.org/10.1227/NEU.0000000000003151

35. Sadhwani S, Brown M, Dalton J, Nivar I, Henzes J, Marcinko M, et al. Single position lateral versus prone transpsoas lateral interbody fusion inclusive of L4-L5: a single surgeon experience examining early postoperative outcomes. World Neurosurg. 2024;187:e460-4. Available from: https://doi.org/10.1016/j.wneu.2024.04.109

36. Edelbach B, Laurey N, Ahola M, Cho S, Shin D, Haynal E, et al. Single position prone versus dual-position in lateral transpsoas approach for lumbar interbody fusion and fixation: propensity matched non-inferiority analysis for spondylosis. Neurochirurgie. 2026;72(3):101786. Available from: https://doi.org/10.1016/j.neuchi.2026.101786

37. Rodgers WB, Gerber EJ, Patterson J. Intraoperative and early postoperative complications in extreme lateral interbody fusion: an analysis of 600 cases. Spine (Phila Pa 1976). 2011;36(1):26-32. Available from: https://doi.org/10.1097/BRS.0b013e3181e1040a

38. Rustagi T, Yilmaz E, Alonso F, Schmidt C, Oskouian R, Tubbs RS, et al. Iatrogenic bowel injury following minimally invasive lateral approach to the lumbar spine: a retrospective analysis of 3 cases. Global Spine J. 2019;9(4):375-82. Available from: https://doi.org/10.1177/2192568218800045

39. Kueper J, Fantini GA, Walker BR, Aichmair A, Hughes AP. Incidence of vascular complications during lateral lumbar interbody fusion: an examination of the mini-open access technique. Eur Spine J. 2015;24(4):800-9. Available from: https://doi.org/10.1007/s00586-015-3796-2

40. Dakwar E, Le TV, Baaj AA, Le AX, Smith WD, Akbarnia BA, et al. Abdominal wall paresis as a complication of minimally invasive lateral transpsoas interbody fusion. Neurosurg Focus. 2011;31(4):E18. Available from: https://doi.org/10.3171/2011.7.FOCUS11164

41. Pumberger M, Hughes AP, Huang RR, Sama AA, Cammisa FP, Girardi FP. Neurologic deficit following lateral lumbar interbody fusion. Eur Spine J. 2012;21(6):1192-9. Available from: https://doi.org/10.1007/s00586-011-2087-9

42. Cummock MD, Vanni S, Levi AD, Yu Y, Wang MY. An analysis of postoperative thigh symptoms after minimally invasive transpsoas lumbar interbody fusion. J Neurosurg Spine. 2011;15(1):11-8. Available from: https://doi.org/10.3171/2011.2.SPINE10374

43. Cahill KS, Martinez JL, Wang MY, Vanni S, Levi AD. Motor nerve injuries following the minimally invasive lateral transpsoas approach. J Neurosurg Spine. 2012;17(3):227-31. Available from: https://doi.org/10.3171/2012.5.SPINE1288

44. Abel NA, Januszewski J, Vivas AC, Uribe JS. Femoral nerve and lumbar plexus injury after minimally invasive lateral retroperitoneal transpsoas approach: electrodiagnostic prognostic indicators and a roadmap to recovery. Neurosurg Rev. 2018;41(2):457-64. Available from: https://doi.org/10.1007/s10143-017-0863-7

Discover a bigger Impact and Visibility of your article publication with Peertechz Publications

Highlights

- Signatory publisher of ORCID
- Signatory Publisher of DORA (San Francisco Declaration on Research Assessment)
- Articles archived in worlds' renowned service providers such as Portico, CNKI, AGRIS, TDNet, Base (Bielefeld University Library), CrossRef, Scilit, J-Gate etc.
- Journals indexed in ICMJE, SHERPA/ROMEO, Google Scholar etc.
- OAI-PMH (Open Archives Initiative Protocol for Metadata Harvesting)
- Dedicated Editorial Board for every journal
- Accurate and rapid peer-review process
- Increased citations of published articles through promotions
- Reduced timeline for article publication

Submit your articles and experience a new surge in publication services
https://www.peertechzpublications.org/submission

Peertechz journals wishes everlasting success in your every endeavours.

Citation: Martinez Mateo AL, Rodriguez M, Rosario AR. Pitfalls and Pearls in Transpsoas Lateral Lumbar Interbody Fusion. Open J Orthop Rheumatol. 2026;11(1):15-28. Available from: https://dx.doi.org/10.17352/ojor.000058